Presented to
The Library
of the
University of Toronto
by
THE ALEXANDER MACDONALD
FOUNDATION

OPHTHALMIC REPORTS.

Digitized by the Internet Archive
in 2010 with funding from
University of Toronto

http://www.archive.org/details/reportsroyal02roya

Ophthalmic Hospital Reports

AND JOURNAL OF THE

ROYAL LONDON OPHTHALMIC HOSPITAL.

Edited by J. F. Streatfeild.

1859—1860.

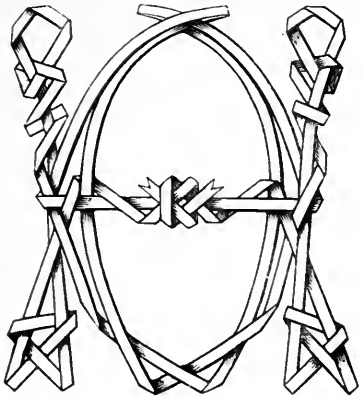

VOLUME THE SECOND.—PRICE TWELVE SHILLINGS.

LONDON:

TO BE HAD OF

MR. CHURCHILL, 11, NEW BURLINGTON ST.

NEW YORK, MR. BAILLIERE, 440, BROADWAY.

RE
3
L6L6
v.2

LIBRARY
APR 13 1961
UNIVERSITY OF TORONTO

892250

CONTENTS

OF

THE SECOND VOLUME.

OBSERVATIONS, Page

In No. 7. Can the Superior and Inferior *Recti* move the eye laterally . . . 1

No. 8. Notes on Night Blindness . . . 35

No. 9. On Coloured Papers 117

No. 10. Dr. Mackenzie on "So-called Diphtheritic *Ophthalmia*" . . . 175

Voluntary Power of using the *Tensor tarsi*, and of causing *Entropion* of the lower lids 176

No. 11. The Sun-ophthalmoscope . . . 239

Various Ophthalmoscopic appearances of the Vessels of the Optic Disk, when excavated 240

PUBLISHED CASES,

Case 19. Cancerous ulceration, treated with sulphate of zinc paste 5

20. Appearances of Orbital Aneurism . . 6

21. *Ophthalmitis* from injury. Dissection . 11

22. *Anemia* of the Optic Nerve and *Retina* . 14

PUBLISHED CASES, *continued* Page

Case 23. Night Blindness. Ophthalmoscopic Appearances 15
24. Inflammation of *Retina* (?) and Choroid . 16
25. Night Blindness, with Scurvy, in the Crimea 37
26. *Hemiopia* coitaneous with effusion of Lymph (?) 38
27. Melanotic Tumour, externally, of the Sclerotic 120
28. Voluntary power of using Horner's Muscle 123
29. *Phthiriasis Palpebrarum* 125
30. Protrusion of the Globe with some symptoms of Aneurism 127
31. Diphtheritic *Ophthalmia* 130
32. *Amaurosis;* from Fatty Degeneration, &c. 181
33. Persistence of some remains of the Pupillary Membrane 185
34. Voluntary power of using the *Orbicularis Palpebrarum*, so as to invert the lower Lid 186
35. Extraction of a portion of Coal, etc. . 244
36. *Entropion*, from winking 247
37. Much *Edema*, with slight *Conjunctivitis*, etc. 248

ORIGINAL COMMUNICATIONS,

In No. 7. The Structure and Movements of the *Iris*, by Dr. LETHEBY 18
The Use of *Forceps* in extraction of Cataract, by Mr. FRANCE 20

ORIGINAL COMMUNICATIONS, *continued* Page

In No. 8. Night Blindness in connexion with Scurvy, by Dr. BRYSON . . . 40
Paralytic affections of the Muscles of the Eye, by Dr. JOHN S. WELLS . 44
Inflammation of the Eye, consequent on Inherited *Syphilis* (*continued*), by Mr. JONATHAN HUTCHINSON . . 54

No. 9. Paralytic affections of the Muscles of the Eye (*continued*), by Dr. JOHN S. WELLS 133
Further remarks on *Iridesis*, by Mr. CRITCHETT 145
Conical *Cornea*, and its treatment by operation, by Mr. BOWMAN . . 154

No. 10. Foreign Bodies in the Eyeball, by Mr. WHITE COOPER . . . 188
Paralytic affections of the Muscles of the Eye (*continued*), by Dr. JOHN S. WELLS 192
Protrusion of the Eyeball (*continued*), by Mr. POLAND 216

No. 11. *Glaucoma*, and the Optic *Papilla*, by Dr. MACKENZIE 252
Inflammations of the Eye, consequent on Inherited *Syphilis* (*concluded*), by Mr. JONATHAN HUTCHINSON . . 258
Paralytic affections of the Muscles of the Eye (*continued*) by Dr. JOHN S. WELLS 284
On *Corelysis*. Detachment of adhesions of the pupil, etc., by Mr. STREATFEILD 309

QUARTERLY REPORTS, Page

In No. 7. Of Operations on the *Iris*, R.L.O.H. . 26
Of Donations to the Library, etc. . 32

No. 8. Of Operations for *Strabismus, Entropion, Ectropion*, etc., R.L.O.H. . . . 106

No. 9. Of (78) Iridectomy Operations, for *Glaucoma*, R.L.O.H. 168

No. 10. Of (78) Iridectomy Operations, for *Glaucoma*, R.L.O.H. (*concluded*) . . . 226

No. 11. Of Linear Extraction Operations, R.L.O.H. 346
Of Donations to the Library, etc. . . 355

LIST OF PLATES IN THE SECOND VOLUME.

Plate VIII. (April, 1859). Ophthalmoscopic Appearances.
IX. (October, 1859). *Phthiriasis Palpebrarum.*
X. (April, 1860). Heredito-syphilitic Inflammations.
XI. (April, 1860). "Cupping" of the Optic Disk, etc.

TO THE BINDER.

All the Plates should be placed at the end of the Volume. The descriptions of the Plates are on two separate leaves, one of which should be inserted between Plates VIII and IX, and the other between Plates X and XI.

OPHTHALMIC HOSPITAL REPORTS,

AND JOURNAL OF THE

ROYAL LONDON OPHTHALMIC HOSPITAL.

No. VII.

April, 1859.

At the beginning of the second number of the Ophthalmic Reports, it was a fair subject of congratulation that the contributions to the newly established journal were so many; and, now, at the beginning of the second volume, it is even more gratifying to find that the number of contributors has lately so much increased. This is good evidence of the approval, which, in consideration of the importance ophthalmology had attained, was claimed for this periodical, when it was founded, and which now goes to prove the expediency of a special record of its progress in the English language. That it has gained so much support, founded on the desire of increasing ophthalmic science, convinces me that, for the same reason, more and more contributors will come forward, and the ultimate success of the journal be thus established.

CAN THE SUPERIOR AND INFERIOR RECTI MOVE THE EYE LATERALLY?

The superior or inferior, acting with the internal or external rectus, turns the globe in a direction between the two muscles, somewhat laterally; and it has been supposed that the superior and inferior recti together have, by means of some parts of their broad sclerotic insertions, a power of moving the globe, from the axis of the orbit, to one side. This opinion has been adopted by some operators in extra-

ordinary cases of squint, and frequently with a good result;* but if it is not true, as I believe, that success in tenotomy can be appreciated at the time, the simple operation of dividing the tendon of the lateral muscle only, might have been sufficient in these cases. However this may be, I believe that the superior and inferior muscles *have* a power of giving lateral motion to the globe, for I have lately seen two cases which bear upon this point.

E. V., a maid-servant, aged 26, became an out-patient at Moorfields on January 10th, 1859. She had paralysis of the left external rectus muscle, and could not abduct the right eye steadily for any length of time. She said that, three weeks previously, she had had headache for some days, and then she seemed to squint, and saw some objects double. She described a similar attack, four years before this time, for which she took "strengthening medicine," and recovered in two or three months. She had no longer any headache, and was in very good health, but, as the squinting and double vision continued, she came to the Hospital. She had passed portions of "tape-worm," but had not discovered it till lately. She was pale and thin, of active habits, and quick muscular movements. The eyes, with and without the ophthalmoscope, seemed to be healthy; when either of them was covered she saw very well. Generally, when she tried to look at an object, away to the left side, the left eye, which was not generally inverted, remained in the position of the axis of the orbit; but, *when I urged her to continue to look at the object whilst I moved it quickly to her left, the eye, when it reached the axis of the orbit, gave a sudden turn, once up and once downwards, gained a slight amount of eversion,* reached its outward limit, and then relapsed into its former position, centrally in the axis of the orbit. This peculiar movement of the left eye was seen, at first, on each occasion when she came, but it was not often repeated each time, as it appeared that the eye soon became tired of this exercise, or indeed of any movement, excepting, probably, in the inward direction; and if only to bring the eye again to the axis of the orbit, when inverted, the abductor is required to act, and, in default, it is probable that the superior and inferior recti alone have to do this.

It seemed to me that, in the above case, when the eye, not being under the control of the external rectus, was

* Ophthalmic Reports, vol. i, pp. 253, 254.

turned up and downwards, the superior and then the inferior muscle had most power, and then that they acted together, to turn the eye outwards, but that they alone could not keep the eye in this direction, although it was enough to show that in the normal state they can assist the external muscle, and perhaps the superior and inferior muscles would act to most advantage, secondarily, when the proper abductor has begun to turn the eye outwards.

She came several times, and I tried different kinds of treatment, and on the 20th (she had then been taking quinine mixture) she could turn the left eye outwards in some degree, with hesitation—it still sometimes turned quickly down, but not upwards.* She did not come again to the Hospital.

The second case was also one of my out-patients at Moorfields.

M. C., a girl, aged 15, came on February 3rd, 1859, with occasional convergent strabismus of the right eye only. Both her father and foster-mother squint, she used to imitate them, and, since she was three years old, she has had the defect. She then only squinted occasionally, and it became a trick. She had voluntary power to turn this eye inwards whilst the other remained in position—she could, with great facility, do this, and desist at any time, or keep it so. Vision of this eye was defective, and when she read, or looked very attentively at any object placed directly before her, the eye was very much inverted, because she "saw better," and if, reading with the left eye only, the position of the book or other object was changed, there was always the same degree of distortion of the right eye, as compared with the direction of the left, thus, if the book was placed much to the right side she continued to read with the left eye, and the right was as if looking directly forwards; but, even when reading, she could, by an effort, prevent the inversion taking place. She had no double vision.

On the 7th, I divided subconjunctivally the tendon of the right internal rectus, as I hoped, by its temporary disuse or otherwise, she would lose the acquired habit. I then told the patient to turn the eye in as she had done before. She could not do this, or follow an object away to her left with

* I have since seen this twitch *once downwards*, under similar circumstances, in another case of palsy of the sixth nerve.

the right eye. The attempt was perhaps painful; but when she began to read, *I thought the eye became slightly inverted.* I could not be sure that it was so in this case, and certainly it is rather improbable, for although the superior and inferior recti usually aid in this movement, yet the voluntary power was, no doubt, an extraordinary influence she had gained over the proper adductor alone, as some persons can use the tensor tarsi or any other muscle not usually under the influence of the will. She had, immediately after the operation, double vision, which in a few hours disappeared.

On the 10th no double vision, inversion, or power of inversion existed.

On the 17th she told me that, the previous day, she had been startled, and the right eye then became inverted; before this, since the operation, she had quite lost the voluntary power of adduction. The power regained over the right internal rectus was slight, and *the superior rectus seemed to act with it,** as the voluntary movement was slightly up as well as inwards. She could read properly without inverting the right eye, and could see better with it.

I watched the case after this time for six weeks, when she had finally lost the power of turning the eye inwards; parallelism was perfect, and, straight before her, she read, with the right eye, at a focus of twelve inches, the smallest type.

From the above cases it appears that the superior and inferior muscles can move the eye outwards, and that, probably, lateral movement in the opposite direction is effected in some degree by the same muscles, and not only by the internal rectus. The evidence in the first case is necessarily the most satisfactory — when palsy of the internal rectus occurs there is loss of power in the superior and inferior muscles; and, in the second case quoted, the extraordinary power was probably lost altogether when the internal rectus was divided, and then inversion or any other muscular movement was probably painful.

J. F. Streatfeild.

* Or its action now was limited to the upper part of the muscle, or its new attachment to the globe was higher than natural.

PUBLISHED CASES.

Case XIX.—Cancerous Ulceration close to the Inner Canthus, treated with Sulphate of Zinc Paste.

By Dr. William Mackenzie (*of Glasgow*).

A patient, aged apparently about 55, and who attributed the spread, if not the origin, of his complaint, to the depression of mind arising from pecuniary loss, applied to me on the 1st of February, 1859, on account of a cancerous ulcer on the side of the nose, close to the inner angle of his left eye. It was fully the size of a fourpenny-piece, of irregular shape, covered with a scab, and surrounded by hard and elevated edges. The papillæ and caruncule lacrymales, and the palpebral conjunctiva were inflamed, and the disease seemed to be extending in the direction of these structures.

I felt no doubt that were the ulcer left to itself, it would gradually spread, and prove rebellious to all applications of a soothing description. Having repeatedly found, also, that extirpation of such a disease by the knife, even when care was taken to cut into the sound integuments, although followed by a firm cicatrice and an apparent cure, was succeeded after a time by a renewal of the scirrhous hardness and intractable ulceration, I determined in this case to try as an escharotic the sulphate of zinc, as recommended by Dr. Simpson of Edinburgh. I was partly led to this course, too, by observing that I could not extirpate the diseased part without removing the lower papilla lacrymalis.

Having driven off by heat the water of crystallization of a few grains of the sulphate of zinc, and reduced the residuum to a fine powder, I mixed it with a little glycerine, so as to form a thick tenacious paste. Taking a little of this on the point of a bit of stick, I applied it over the scab and over the hard edges of the ulcer, and covered the part with dry lint.

Next day, I found that the application had given very little uneasiness; but that it had acted in destroying almost entirely the hard edges of the sore, and left the whole of its surface free from scab and of a florid healthy colour.

Two or three times subsequently, I covered the edges again with the zinc paste; after which, I left the wound to cicatrize, under the application of dry lint. I touched the

conjunctiva and papillæ lacrymales occasionally with the four grains' solution of nitrate of silver, under which application they speedily freed themselves of inflammation.

On the 24th March, the patient called on me, with a firm cicatrice, of a healthy hue, in the site of his former disease.

Case XX.—All the Capital Signs of Orbital Aneurism present, in a marked degree, but independently of Aneurism or any Erectile Tumour.

By Mr. Hulke.

A woman, aged 40, of irregular, dissipated habits, was admitted, February 19th, 1858, into King's College Hospital, under the care of Mr. Bowman, with symptoms supposed to depend on orbital aneurism. Five months previously, in a scuffle, she was struck with a fist on the left side of the head and temple. The blow knocked her down. The next day she felt severe pain in the left temple, about one inch in front of the ear. The pain was aggravated when she moved about and when she stooped; it disturbed her sleep. After a fortnight it subsided, but was replaced by a rushing noise, like the beating of a steam-engine, on the same side of the head, at first towards the occiput, but latterly in front of the ear and temple. The noise was constant, and increased when the heart's action was quickened. She said that, since first heard, it had gradually increased in loudness. This noise had been heard by her husband ever since three weeks after the accident. A month before her admission into the hospital, she found her sight "bothered" when she looked at an object with both eyes. A fortnight after this the left eye became red and sensibly projected. The subjoined memorandum was made on her admission.

"General fulness of the left orbital region with prominence of the eye which is congested. The pupil dilated but active. Sees distant objects perfectly, but is unable to read. The angular vein and one over the outer edge of the orbit are dilated. There is an abrupt depression in the lower border of the orbit at the articulation between the malar and upper maxillary bones. A loud sibilant bruit can be heard

extensively over the left side of the head, but it is most intense above and in front of the ear. This sound is synchronous with the beating of the heart. A similar bruit is heard along the course of the great cervical vessels as far down as the common carotid artery. The fingers being placed upon the left eye, when the lids are closed, pulsation is plainly felt, and the fingers are seen to rise and fall with it; a loud bruit also is heard when the stethoscope is placed on the front of the globe. Head symptoms, as giddiness and loss of memory, have never been present. The irregularity of the lower border of the orbit seems to have resulted from a blow received three months after the first injury.

All these symptoms plainly pointed to the existence of orbital aneurism, and as they were manifestly increasing, Mr. Bowman decided to tie the common carotid artery. This was done on February 27th, the patient being under the influence of chloroform. The operation was accomplished without difficulty and with the least possible interference with the adjacent structures. The sheath was opened only just sufficiently to allow the passage of the aneurism needle. The internal jugular vein and pneumogastric nerve were not seen. The vessel was tied a little higher than was originally intended in consequence of a large vein running across the line of the wound. Immediately on tightening the thread all pulsation was arrested in the vessel and its branches above. The pulsation and bruit hitherto felt and heard over the front of the eye at once ceased. On recovering from the effects of the chloroform she was sick, and stated that she still heard the noise in her head, but faintly; it could not, however, be heard by other persons. Next day she complained of great throbbing in the right side of the head, and in the left side of a sound like the noise of a drum a long way off. The eye was less prominent, and less congested, and she spontaneously said that her sight was no longer "bothered." During the next week she was much distressed by cough with a free bronchial expectoration to which she had been liable for two years past. On the 7th, the wound which had nearly healed assumed a phagedenic appearance. A distinct bruit could be heard over the front of the eye, and also over the left forehead, but more faintly. Just in front and a little above the ear, on the same side, a continuous musical note of rather a high pitch, swelling out at each pulsation, could be heard. There was little change in the nature of the sound as

heard by herself, though at times it was rather more intense. Above the point of ligature no pulsation could be felt in the carotid. The phagedenic ulceration spread, and the discharge from the wound was unhealthy. The tongue became furred, dry and brown. On the morning of the 10th, at 2 o'clock, there was slight oozing of blood from the wound; two hours afterwards it recurred to the extent of a couple of ounces, and seemed to come from the upper angle. It was readily checked by slight pressure.

The hemorrhage recurred twice during the next twenty-four hours, and she had a severe rigor. The ligature separated without bleeding on the evening of the 11th, thirteen days after the vessel was tied; but on the following morning at 4 o'clock, free hemorrhage took place. It was repeated several times during the next four days. The blood welled up in a full stream from the bottom of the deep sloughy wound; slight pressure always arrested it at the time. Graduated compresses moistened with perchloride of iron were employed. It seemed probable that the bleeding came from the upper end of the vessel. The left eyeball again became prominent; the pupil was dilated and motionless; the eye was everted: and there was ptosis of the upper lid. No pulsation could be felt over the eye. A free gush of blood took place during the visit on the 15th. With some difficulty Mr. Bowman struck a tenaculum through the spot from which the blood seemed to pour; the tissues were tied with complete arrest of the bleeding. She became weaker; was at times greatly excited, and at length died on the 17th.

Post-mortem appearances.—Permission was obtained to examine the head and neck only. The skull cap and dura-mater having been removed, the visceral layer of the arachnoid was found to be slightly opaque owing to a little serum in the meshes of the pia-mater. The brain and all its vessels were quite healthy; the descending horn of the right lateral ventricle contained two drachms of serum; the other cavities were empty. The pituitary body was swollen, congested, and coated with lymph. The dura-mater being the floor of the sella turcica and the posterior clinoid processes, together with that corresponding to the cavernous, transverse, superior and inferior petrosal sinuses, was congested and coated with a layer of lymph which was sprinkled with small dots of blood, but no vessels could be detected in it with the microscope.

The dura-mater forming the outer wall of the cavernous

sinus was swollen and softened, and the third nerve imbedded in it was greatly swollen and bathed in serum; the Casserian ganglion and the nerves proceeding from it were in a similar condition. The cavity of the sinus contained a puriform fluid, which on close examination proved to be softened and disintegrated coagulum. The transverse sinus was filled with an old clot, the outer part of which was firm and adherent to the wall of the sinus, but the centre had a tawny brown colour, and a pulpy consistence. This grumous pulp was mainly composed of cells having the appearance of pus corpuscles, but wanting the characteristic nuclei on the addition of acetic acid. Small masses of orange-brown pigment were mingled with these cells. The circular sinus was filled with similar matter. A slender decolorized clot extended from the cavernous sinus for a short distance into the superior petrosal. The superior petrosal sinus, in its whole extent, was filled with softened clot. The vascular foramina on the surface of the body of the sphenoid and tip of the petrous portion of the temporal bone were dilated; a section of these bones had a rather brownish colour, but they were not soft or carious. The double bend of the internal carotid artery resting against the side of the body of the sphenoid bone, together with the carotid and cavernous plexuses of the sympathetic nerve were bathed in ichorous serum, but the artery itself was not dilated, and its inner surface had a perfectly healthy appearance. The ophthalmic artery and its branches were traced with great care, they were not at all dilated, nor more numerous than usual. The infra orbital branch of the internal maxillary artery was not enlarged; the antrum was healthy. The malar was detached from the upper maxillary bone and displaced slightly upwards. This was the only change in the wall of the orbit. The ophthalmic vein seemed much enlarged and had the appearance of a varix. By comparing it with the vein of the other orbit, the enlargement was seen to be due to thickening of its coats, and not to any dilatation of its calibre. Where the vein opened into the cavernous sinus it was obstructed by a softened, degenerated clot, similar to that in the sinus; this clot stretched along the trunk of the vein into the orbit, but here and in the tributary branches of the vein it was evidently of more recent date than that which blocked the mouth of the vein at the cavernous sinus.

The ligature had been placed upon the common carotid artery a little below its bifurcation; the divided ends of the

vessel were three-quarters of an inch apart. The external and internal carotids were patulous and empty; the lower portion of the common carotid trunk from the point of deligation downwards to the root of the neck was filled with pulpy, grumous clot which oozed out from the patulous open end during the removal of the parts. At the root of the neck the vessel was completely closed by a thin membranous, decolorized coagulum, which formed a perfect septum; below this the carotid had a perfectly healthy aspect. That portion of the vessel containing the decomposed grumous clot, had a dirty-brown stain, and its inner surface was flocculent from adhering shreds of fibrine, but was not otherwise altered. The external carotid and its branches were healthy and empty. The internal carotid artery upwards to the base of the skull and in the carotid canal was healthy: not dilated, and its inner surface smooth and of a natural colour. In the upper part of its course it contained a slender fibrinous clot, a mere thread, which occupied only a slight portion of the calibre of the vessel. The internal jugular vein was healthy, it contained a slender decolorized clot reaching from the root of the neck to the base of the skull, and a similar clot was found in the left lateral sinus.

The great importance of this case in the history of this rare and obscure disease is my apology for presenting it at such length. Bruit, pulsation, protrusion of the eyeball, in short all the physical signs of orbital aneurism were present in a marked degree, yet no aneurism or erectile tumour existed. How much doubt this case throws on many of the recorded examples of aneurisms of the orbit. It has been a common custom to speak of such cases as aneurisms by anastomosis; but this, in the majority of instances, is not their true nature. An analysis of twenty-one cases shows that they range themselves in two distinct series; the first comprising aneurism properly so called, true and diffuse; the second aneurisms by anastomosis, or erectile tumours. The former series is much the larger, and indeed the age at which the disease is most frequently met with, the suddenness with which the symptoms appear, often immediately following a blow or other direct violence, all point to aneurism proper in contradistinction to erectile tumour. This has been strongly insisted on by Mr. Nunneley, of Leeds, in a recent communication to the Royal Medical and Chirurgical Society, in which he narrates three cases occurring in his own practice. But the case I have described does not

come under either category; for, as I have already said, neither aneurism nor erectile tumour was present, yet had the woman recovered, no doubt would have been thrown on its nature, and the case would have been adduced as another instance of orbital aneurism, cured by ligature of the carotid artery. It is difficult to explain the aneurismal symptoms by the pathological appearances, which were those of phlebitis of the cavernous, transverse, circular, and petrosal sinuses. The internal carotid artery may have been partially compressed by the swollen walls of the cavernous sinus against the side of the body of the sphenoid bone giving rise to the bruit, which would have a good conducting medium in the cranial bones. The plugging of the trunk of the ophthalmic vein, where it joins the cavernous sinus, by obstructing the return of blood from the orbit, accounts for the protrusion of the eyeball, and perhaps also for the pulsation which was felt when the fingers were laid on it; because each diastole of the ophthalmic artery must have been attended by a general momentary increase of the whole quantity of blood in the orbit, because its exit through the ophthalmic vein was cut off, and the resisting bony walls of the orbit could permit a distension in front only. The healthy state of the internal carotid artery and its branches, and of the internal jugular vein, preclude the idea that the pathological changes in the cranial sinuses commenced subsequently to the deligation of the common carotid. This operation was performed in fifteen of the twenty-one cases to which I have alluded, and the result in eleven instances was satisfactory. Two cases were recently cured by digital pressure on the common carotid artery, by Gioppi, and Vanzetti, of Padua.*

Case XXI.—Ophthalmitis from Injury—Excision—Dissection.

By Dr. Bader.

I. C., aged 9 (patient of Mr. Bowman), had the upper and outer ciliary region of the right eye perforated by a steel pen, on the 7th of December, 1858; vision was destroyed the next day; the patient had slight pain, the eye looked intensely inflamed, and vision of the left eye soon began to

* For an account of these, and an analysis of seventeen cases, see Schmidt's Journal, No. 4, 1859.

be impaired, with other signs of chronic deep-seated inflammation. The right eye was excised on the 18th of January, 1859, and examined immediately afterwards.

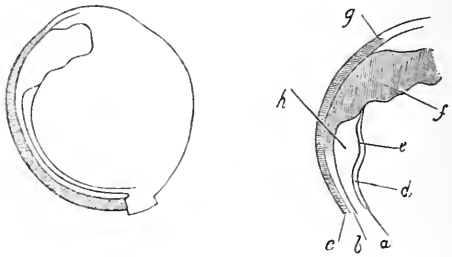

a. Retina.
b. Choroid.
c. Sclerotic.
d. Where the displacement of the retina inwards commences.
e. Commencement of the transparent membrane (hyaloid + ?), which, in the normal state, lies on the inner surface of the choroid (ora serrata) and which is intimately connected with the retina.
f. The ora serrata, ciliary processes, and iris infiltrated with lymph.
g. Margin of the cornea.
h. Space between displaced retina and infiltrated choroid occupied by a turbid yellowish fluid.

The smaller figure represents the natural size of the parts in a section of the whole eye.

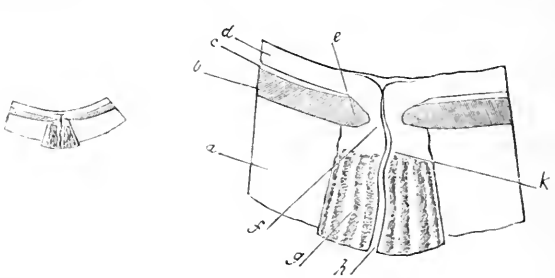

a. Sclerotic.
b. Choroid, infiltrated with lymph, exceeding about four times its natural thickness.
c. Elastic lamina (limitans) of the choroid and the layer of hexagonal cells.
d. Retina.
e. Portion of choroid, which encroaches upon (constricts) the transparent portion of the optic nerve fibres.
f. Constricted part of the optic nerve fibres.
g. Grayish translucent bundles of optic nerve fibres.
h. Retinal vessel.
k. Where the optic nerve fibres first become transparent.

The smaller figure shows the natural size of the parts.

The vitreous space was occupied by turbid fluid and whitish flocculi; the retina was very vascular, the vessels gorged; its substance was slightly hazy; a small quantity of turbid fluid had been effused between it and the choroid: it was thus displaced inwards, principally along the ora serrata, where it adheres to the transparent membrane which lines the ora serrata; this membrane had been pressed inwards by inflammatory products, dragging the retina inwards also; the substance of the choroid was infiltrated with lymph, chiefly round the optic nerve and beneath the yellow spot; it encroached much on the optic nerve, and reduced its diameter considerably (constriction of the optic nerve). No lens was found; the whole of the area surrounded by the ora serrata, ciliary processes and iris was occupied by inflammatory products.

The preparation (one-half of the eye) may be seen in the Museum of the Hospital.

This case shows one manner in which the retina becomes displaced from the choroid: a quantity of inflammatory products is poured out from the inner (vitreous) surface of the portion of the choroid called the ora serrata and from the ciliary processes beneath the transparent membrane which lines those parts; this membrane is thus pressed into the vitreous space; the contents of which lose their consistence and volume. The retina is intimately connected with the above membrane, and is drawn inwards in proportion as the former is pressed into the vitreous space; the space which is created by the displacement of the retina, between it and the choroid, is filled with fluid (serum, pus corpuscles, etc.) which comes from the inflamed and infiltrated choroid. The continued changes of the contents of the vitreous space (shrinking, etc.) appear to lead to the further displacement of the retina.

The case shows also the possibility of the portion of the choroid which surrounds the optic nerve (choroidal aperture) pressing upon the nerve; the margin of the choroidal aperture advances upon the transparent portion of the optic nerve, thus probably affecting the circulation of light, blood, etc., in the retina.

Case XXII.—Anemic State of the Optic Nerve and Retina.

By Dr. Bader.

Jane Buffam, aged 29, had been in very good health until three years ago, when, three weeks after a confinement, she caught cold, which was followed by epileptic fits, two or three a-week. These ceased spontaneously after twelve months, and three months after this she became pregnant and was weak and ailing during the whole of the time. After the birth of a child she was well again and remained so for four months, when she had an attack of pneumonia, from which she recovered in three weeks; but it was followed by night perspirations, pain in the chest, expectoration of blood, etc. These symptoms have disappeared the last two months; and now she is in the fifth month of pregnancy. Her parents and five sisters are alive and in good health; another sister has a bad cough.

The patient is a pale and thin woman of middle size and fair complexion; she has several large caverns in the upper lobe of the right lung.

Both eyes had been good until some time after the fits had commenced; she then lost her vision in the right eye suddenly during the day (not during a fit); "the eye became dark all at once" without any inflammatory symptoms and she has had no perception of light with this eye since. Vision, of the left eye, seems to have become misty some time after the right; the degree of mistiness remains stationary; pain is felt at the back of the head, when the sight is much tried. With this eye she can recognise very large letters, one at a time, at about five inches distance, but she loses the sight of one entirely before she can recognize the next; she sees but cannot recognize objects at a moderate distance; every room looks to her as if it was full of smoke. Her vision is not improved by glasses. The right eye has a tendency to eversion; the sclerotic of both eyes is of a dead-white, the conjunctiva extremely anemic; a few thin vessels emerge from the ciliary region of the sclerotic; the cornea, iris, pupil, etc. appear healthy; the tension of both eyes is normal.

Ophthalmoscopic examination.—Right eye, Plate VIII, B. The media and retina are transparent. The retina next to

the entrance of the optic nerve and that portion where the yellow spot (a small, well-defined brownish dot) is situated, are subtended by an equally red surface (the chorio capillaris filled with blood); further on the choroidal pigment and large choroidal vessels are well seen. The entrance of the optic nerve, in its central portion, is white, and at its peripheral portion bluish-white; it is flat and well-defined. The small brownish patch at its periphery is situated in the margin of the aperture which the choroid forms round the optic nerve. The vessels passing through it are extremely thin and few in number and hardly perceptible while branching over the retina; the arteries can be distinguished from the veins by their straight course, and bright red blood; the same pressure as in healthy eyes is required to stop their pulse; an ill-defined faint whitish patch is perceptible in the chorio capillaris near the entrance of the optic nerve.

The left eye presents the same appearances as the right, except that the retinal vessels are not quite so thin and are more numerous.

The cause of this high degree of anemia of the retina and optic entrance is probably the constitutional state of the patient, the veins and arteries are equally anemic, and the state of both eyes as far as the blood supply is concerned is in proportion to the amount of vision in either eye.

Case XXIII.—Night Blindness—Ophthalmoscopic Appearances.

By Dr. Bader.

The two sketches (Plate VIII, C, 1, C, 2), are taken from a case of night-blindness, which came under the care of Mr. Dixon, December 26th, 1857. The history of the patient and his symptoms offered no peculiarities. The ophthalmoscopic appearances of both eyes were these:—The media (cornea, aqueous, lens, and vitreous) were transparent; the fundus round the optic nerve entrance had a bluish red tint as if the choroidal red were seen through a faintly blue tinted glass; the retina appeared transparent; the entrance of the optic nerve had its normal, slightly pink, appearance; the rather oval shape is not unfrequently observed in healthy eyes; the vessels which pass

through the optic entrance were too numerous; the veins were slightly tortuous; the arteries in this case presented the peculiarity that the stream of blood glided along the walls of the vessel leaving its central part free. The usual pressure was required to stop the circulation in the retinal vessels; the yellow spot appeared as a well-defined brown dot.

This bluish tint of the fundus of the eye is mostly observed in dark-eyed people; it is not peculiar to night-blindness, and appears to be due to the quantity of pigment in the choroid and to the state of transparency and colour of the granules of the hexagonal cells (so-called choroidal epithelium). It is not unfrequent in healthy retinal circulation to see the middle portion of the vessel empty, while the blood glides along on either side.

Case XXIV. — Inflammation of Retina(?) and Choroid.

By Dr. Bader.

Robert Rolfe, aged 30, under the care of Mr. Tyrrell, clinical assistant to Mr. Dixon, May 19th, 1855, had been in good health until two months previously, when he caught cold, which was followed by what he called an inflammation of the stomach (fever, sickness, pain in scrobiculus cordis, and vomiting), this subsided after two weeks, his sight then began to fail; a grey mist appeared before both eyes; vision for distance was, within a few days, lost, and for near objects became very defective. He was brought to the Hospital by his parents, who are in good health.

The patient, a stout but not muscular man; looks very pale and yellowish, and he complains nowhere of pain, but of loss of appetite and of dizziness in the head, of inability to distinguish distant objects, and of an unusual desire for passing urine; the latter is yellow and turbid, and contains a great quantity of mucus and pus cells: he has twitchings of the muscles; his lungs and heart seem to be normal; his pulse is very slow and full; he answers slowly but correctly.

The sclerotic is very pale, the tension and movements of both eyes are normal, the pupils are of median size and act

sluggishly; he does not perceive large objects when a few yards distant, and only recognises features when very near, and they then appear as if seen through a thick grey mist.

Ophthalmoscopic examination.—Plate VIII, A, 1, A, 2.—The media are transparent; the general appearance of the fundus of either eye is the same; the portion of the fundus comprising the entrance of the optic nerve and the neighbouring retina and choroid has a brilliant reddish white colour. This is chiefly marked at the place which corresponds to the entrance, towards which the retinal vessels converge; further distant from the entrance is the uninterrupted choroidal red, seen beneath the transparent retina; the middle and anterior portions of both eyes are, the retinal vessels excepted, normal. The latter appear, while branching in the brilliant reddish white portion, extremely thin and tortuous, and converge towards one point, which by this is recognised to be the entrance. Some of the vessels are unequally dilated and tortuous, others become suddenly thin, a darkish clot being perceptible at the spot where the thin portion of the vessel begins; small and large blood-spots lie along the walls of some of the vessels. In the portion of the fundus next to the white part may be observed several groups of what resemble herpes vesicles of the skin.

The state of the retinal vessels, of the optic nerve entrance, etc., is probably due to a constriction of the optic nerve by the swollen choroidal aperture, and to the pressure which the infiltrated and swollen choroid exercises on the retina. The state of the brain, urine, etc., of this patient, are indicative of some blood disease.

ON THE STRUCTURE AND MOVEMENTS OF THE IRIS.

By Dr. Letheby.

(*Received April 13th.*—Ed.)

The following are the results of some experiments made many years ago on the structure and movements of the iris; and although so long a time has elapsed since they were performed yet they are still of sufficient interest to deserve publication.

The investigations were pursued for the purpose of ascertaining whether the movements of the iris are due to muscular contraction or to vascular turgescence; and the proofs of it were sought from the microscopic appearances of the organ, the anatomical structure, the physiological property, the chemical reactions, the pathological phenomena, the comparative anatomy, and the action of certain medicines upon it.

1st. A microscopic examination of the iris failed to discover the presence of muscular fibre, except at the outer or ciliary boundary; for the orbicular and radiating fibres had none of the appearances of muscular tissue. That which composed the circular margin of the pupil had the properties and structure of ligamentous tissue; and the rest of the iris was chiefly composed of capillary vessels.

2nd. When the iris was subjected to the stimulus of galvanism, which is so powerful an agent in exciting muscular contraction, there was no movement of it after circulation had ceased. This is very unlike the behaviour of muscular tissue; for in all other cases the circulation of blood is not essential to muscular contraction; in fact, the removal of muscular fibre from the body, and therefore the cutting off of all vascular connection, has no influence on its contractility when it is subjected to such a stimulus. But if the eye of an animal is removed from the orbit and galvanised, the iris shows no sign of contraction,* whilst the

* The circulation having ceased the ciliary fibres have no power to produce any visible effect.

recti muscles are strongly affected. So again, a few minutes after death the iris ceases to contract, for generally this is sufficient time for the arrest of the circulation in the eye, and then no movement can be produced in it.

3rd. Again if the iris be made up of two sets of muscular fibres—the radiating and circular, intimately blended together, how is it that in the living animal, one set only, namely the circular, contracts under the influence of a stimulus? or conversely, why is it that belladonna, and the active principles of the solaneæ generally, act only on the same set? It may be answered that the circular only are muscular, and the radiating elastic; but of this we require proof.

4th. And why, too, is it that in every condition of the system, when the vessels of the head are gorged, as in apoplexy, the pupil is contracted, and in opposite states, as during syncope and in epilepsy, the pupil is dilated? This points to the fact that vascular turgescence has something to do with the phenomena.

5th. The chemical reactions of the iris are more like those of elastic tissue than muscular fibre; for if the iris is enclosed between two pieces of glass, together with fragments of muscular and ligamentous tissue, and then boiled in water, the former like the latter is so changed that the structure is obliterated and gelatine is produced from it; but nothing of the kind occurs with muscular fibre.

6th. If the contraction of the pupil is due to circular fibres, it is manifest that when there is a radial slit in the iris, the contraction of it should cause the sides of the slit to be drawn asunder, but experiments on animals show no such a result: on the contrary, when the iris is cut through the pupil contracts as usual and the edges of the slit are brought closer together.

7th. If we turn to comparative anatomy for help in the inquiry, it will be found that the pupillary aperture in the eyes of some animals is reduced in size, not by a circular contraction of the pupil, but by the falling down or pushing up of a curtain. This is well seen in the eye of the skate,

and it is proof that the movement is not due to muscular contraction, but to the unfolding of the curtain-like membrane by some other cause. Again, the irides of most fish, and of many reptiles, are immoveable, although they have the same structure as those of mammals, excepting the vascularity. So also in tracing the development of the iris from the lowest class of animals to the highest, it is found to be nothing more than a prolongation of the vascular choroid.

Lastly. Injections of the iris show it to be very vascular, and to be made up almost entirely of an erectile plexus. Nay more, if we inject the eye with water from the carotid, we can effect a contraction of the pupil with every force of the syringe; and this may be done long after death, when muscular irritability has entirely ceased.

My conclusions, therefore, are that the movements of the iris in mammals are due to vascular turgescence, and not to muscular contraction, indeed I might point to the fact that the existence of muscular fibre in the outer or ciliary margin of the iris, may afford an explanation of the phenomena, for if there were muscular pressure on the returning capillaries of the iris the tissue would become gorged with blood and the pupil contracted; but of this I had not sufficient proof because of the difficulties of the inquiry.

ON THE USE OF FORCEPS IN EXTRACTION OF CATARACT.

By Mr. France.

(*Received April 30th.*—Ed.)

At the opening of the season during which extraction is chiefly resorted to, and opportunities of testing any suggestion in connexion with it are abundant, I am desirous of drawing attention to a mode of procedure introduced to the notice of the Profession last October.*

* Guy's Hospital Reports, 3rd Series, vol. iv.

A large proportion of the readers of the Ophthalmic Hospital Reports, are themselves operators in more or less wide fields of observation; and it is unnecessary, therefore, to dwell at any length upon points with which experience has rendered them familiar. All probably will at once acknowledge, that there is no operation more variable in facility of execution in different cases than extraction. It has been characterized by competent judges as the most difficult of surgical operations, and cases occur in which it merits the appellation; yet others again are met with, wherein everything passes off so smoothly and favourably, that, to bystanders at least, the character so imputed seems almost a libel invented by the mal-adroit.

It is needless also in this publication to insist upon the influence cast over every subsequent stage of the operation, by that usually described as the first,—the section of the transparent cornea.

If this be performed satisfactorily, all the succeeding steps are apt to follow *en règle*. It constitutes, therefore, the turning point; and to deprive this stage of its uncertainty and risk is, in effect, to assure and facilitate the whole.

What then creates the main obstacle to the ready accomplishment of the section in any given case, and renders arduous perhaps in a plump model globe, that which may be found comparatively easy in an ill-formed deeply-set one, should the condition referred to not exist? Undoubtedly the principal impediment the surgeon has to encounter, is the irregular mobility of the eye, with its restless twitchings and sudden glancings under the excitement and apprehension of the eventful moment; together with its occasional rapid inversion towards the inner canthus (perhaps without previous warning from unsteadiness, and notwithstanding the opposing finger's pressure) when the section is in actual progress, and when this movement imperils to the utmost its normal completion. Hence this operation, in the same hands, varies to an extreme in difficulty, owing to the differing degrees in which these movements prevail in the organ sub-

mitted to manipulation. Accordingly in the dead-house the process is easy enough; probably under chloroform, were its exhibition admissible, (which, on distinct grounds, is not the case,) it would be the same. So, again,—to take a parallel illustration:—a thousand sempstresses in London thread their fine needles fifty times a day, with scarcely a conscious effort, because, minute as is the orifice they aim at, they have the implement at perfect command; but let the work-woman try to attain her end, while the needle is held by her aged mother with paralysis agitans, or by her sister with chorea, and the delicate task would become nearly impracticable. Just in the same way with this operation; the great desideratum is steadiness and fixity of globe, because any irregular or convulsive movement, by jeopardizing the precision and continuity of the section, the retention of the aqueous humor to the last, and (contingently thereupon) the safety of the iris, enhances so seriously, despite the highest skill, the danger of this critical stage.

I have elsewhere* shown how early, in the history of extraction, this truth was recognized; how various have been the contrivances which the exigency has at different times called forth; and how all have successively become obsolete, on account of some prevailing disadvantage attending them. On the same occasion I recommended the employment of simple artery forceps, as conducing in a marked measure to fix the eye steadily in the wished-for position, and as exempt from any of the drawbacks which had caused previous suggestions to fail. The recommendation was supported by the detail of twenty cases, proving the practicability and utility of the plan proposed. Winter has since intervened, and I have consequently but seven additional cases to supplement the former list. In all of these, however, the forceps was used with as good effect as in the preceding instances; the fixed cornea afforded an uniform resistance to the knife; the section was accomplished with proportionate ease without casualty (save, in one example, wherein, from the extreme

* Loc. cit.

prominence of the globe, some vitreous escape was predicted, and took place accordingly), and the patients are now, without exception, enjoying good vision.

My present purpose is to confirm what was before said in advocacy of this appliance; and to notice two or three minutiæ, which should be observed in adopting it; as, it is to be hoped, many, during the ensuing season, may be induced to do. In order not to exceed due limits in this communication, I will condense my remarks into the briefest compass:—

1. As to the form of forceps: an ordinary pair of artery forceps, without spring-catch, is the most convenient. It should be rather long, with broad nibs, and prominent or projecting teeth, so as the better to take hold of the subconjunctival fascia simultaneously with the mucous membrane itself.

2. With this view, at the commencement of the operation, the surgeon, in affixing the forceps, should make pressure with its nibs against the sclerotic, at some little distance beneath the cornea, 'ere closing them with the fold of tissues in their grasp. This is an essential point, as the lax conjunctiva, if seized alone, affords a much less firm anchorage to the globe.

3. The assistant to whom the forceps is delivered, should be instructed to rest his hand quietly upon the patient's face, and maintain the cornea in the central position as passively as possible,—by gentle traction if requested; but scrupulously to avoid either dragging or pushing with the instrument.

4. The operator, raising the upper lid with his forefinger, places that finger in the usual manner on the sclerotic above the cornea, and his middle finger on the sclerotic at the inner canthus, and thus completes his command of the globe.

It will be observed that this method of operating does not involve the *substitution* of one means of fixing the eye for another, but comprises the recognized and general plan, *plus* the effectual auxiliary I am describing. It will be observed,

too, that the forceps, while maintaining the globe in the most convenient position, performs incidentally the subordinate function of keeping the lower lid depressed.

5. The incision of the cornea is made in the regular way; but when counter-punctuation is fully effected, just before the final completion of the flap, the forceps should be gently disengaged. Should there be evidence of spasm, an interval may be here interposed before the last bridle of cornea is severed, as the adequacy of the section and the safety of the iris are now insured; but this is seldom necessary. The remainder of the operation proceeds in the customary mode.

Two objections have been advanced against the use of forceps. The more important is, that it might tend to excite spasm, and consequent rupture of the hyaloid membrane, and escape of vitreous humor. The other, that it must inflict an injury on the conjunctiva, which might prove seriously detrimental to the ultimate issue of the case. With regard to the first: as a matter of fact, it will not be found that spasmodic action is created by the instrument, except, perhaps, at the first moments of its application; when every nervous patient's eye, open it how we will, is apt to be thus affected from alarm. Moreover, if the forceps is detached before the final completion of the section, as it always should be; it is at the surgeon's option, should spasm actually arise, to pause for its subsidence before proceeding; and until he proceeds to divide the remaining corneal isthmus, no mischief can be produced by the occurrence.—The second objection is a very natural one, but entirely at variance with daily experience. I use the forceps in keratonyxis as well as extraction; it is pretty generally employed in London in cases of artificial pupil; sometimes in removing extraneous bodies from the eye; and, in short, on every occasion (extraction hitherto excepted,) when it is desirable to fix the globe; yet mischievous results from the contusion of the conjunctiva are quite unknown.

I will add no more than the expression of my earnest

hope, that the use of forceps, in extraction of cataract, may be submitted extensively and impartially during the approaching summer to the ordeal of practice.* It will then be found, that, by this simple means the section of the cornea may be accomplished with a precision and certainty unattainable before; and the habitual employment of forceps will be recognized as a signal improvement and safeguard in this operation; making it in expert hands still surer,—in those of the less skilful or less experienced comparatively sure.

* Mr. White Cooper informs me, that he is already in the habit of availing himself of this appliance, and concurs in the recommendation of it.

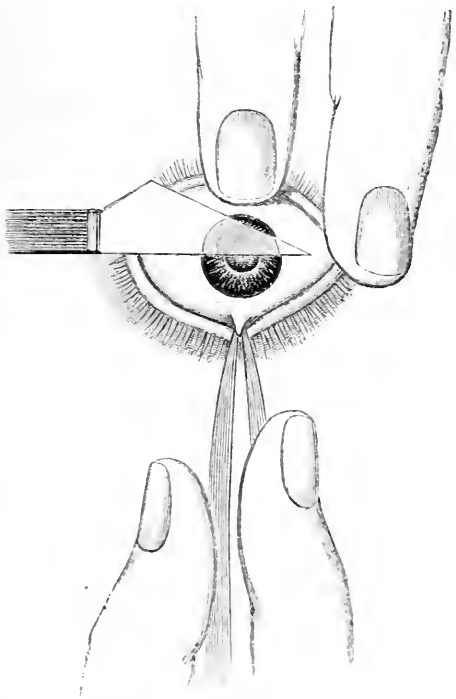

The woodcut illustrates the operation at the moment when the forceps, having fulfilled the intended purpose, should be removed.

REPORT

OF OPERATIONS PERFORMED ON THE IRIS FROM THE DATE OF THE LAST REPORT OF IRIS OPERATIONS, JULY 1, 1858, TO MARCH 31, 1859.

I.—Artificial Pupil.

This operation has been performed in :—

1.—Fifteen cases of obstruction of the pupillary area by inflammatory products.—The iris was impaired in its movements and adherent to these products (posterior synechia). Eleven of the cases were of syphilitic, one of spontaneous(?), and three of traumatic origin. No pain or redness were present at the time of operation. Its success appeared in most cases to depend upon the state of the choroid, retina, etc. In six of the cases both eyes were operated on at the same time; in one case an artificial pupil in one eye had been formed and the lens in the other had been extracted. In most cases the pupils had been formed outwards or downwards. The opening in the cornea was in all cases made with a broad needle. In nine cases the portion of iris was removed with iris-hook and scissors (the hook being inserted at the adherent pupillary margin); in two with the cannula forceps (by tearing away a small portion of the iris near the adherent pupil); iriddesis was performed in one, and in three cases the adhesions were detached with a spatula.

2.—Thirty-two cases of corneal opacity.—The artificial pupil was placed opposite the largest portion of transparent cornea; a pupil on the outer (temporal) side of the iris was preferred in cases of central corneal opacity. A pupil in this situation would be of the most practical (protective) use to the patient.

The opacity followed purulent ophthalmia in six cases, ulceration of the cornea in fourteen, and injury in three cases. Five of the opacities followed corneo-iritis, three remained after an attack of syphilitic keratitis, and one after extraction of cataract.

The operation was, in seventeen cases, performed with the blunt hook and scissors, in fifteen by iriddesis, and in one

the cannula forceps was employed. The general result of these operations was favourable; vision was in all the cases improved.

The opening for the passage of instruments into the anterior chamber, when an extensive central opacity existed, has been made through the sclerotic, close to the corneal edge.

In a case of adhesion of the iris to the cornea it was sufficient to divide the adhesion with the broad needle, which rendered the natural pupil useful. In a case of iriddesis, while drawing out the portion to be tied, the iris here became detached at its greater circumference, perhaps too large a piece had been withdrawn; however the periphery of the iris reunited, leaving a useful artificial pupil.

Iriddesis for the improvement of vision of cases of conical cornea has been performed four times. The results are favourable, and the manner of operating has remained the same as described in the last Report on iris operations. The transformation of the pupil into a *vertical* slit (cat's pupil) appears to be the most effectual plan. The irritation following the operation is slight.

Besides these cases the following may be mentioned particularly:—

A case of congenital cataract, in which the whole of one lens was transparent, except a small circular portion which occupied the anterior surface of the lens, and formed a small white conical projection into the area of the pupil; the pupil was (by iriddesis) displaced laterally, producing a satisfactory result.

A case in which a brownish film stretched across the pupil; it was attached to the anterior surface of the iris, near the pupillary margin, and was, with some difficulty, detached with the blunt hook.

A case which had been operated upon by iriddesis some time previously, and in which the pupil formed a narrow slit. This was changed into a triangular pupillary aperture of moderate size by a second iriddesis.

A case of adhesion of portions of the iris to the cornea, after corneo-iritis (no perforation of the cornea appeared to have preceded this synechia) the adhesions were detached with the blunt hook; some bleeding followed the operation: the blood coagulated immediately after its escape into the

anterior chamber and could not be removed with the scoop; but it had disappeared after a few days.

A case in which inflammation was followed by occluded pupils; both lenses were first extracted; and, sixteen months later, artificial pupils were formed by the removal of a piece of iris on the 22nd of May, 1858. These large pupils were again closed by false membranes on the 9th of March, 1859.

A case of iritis which began during some inflammatory state of the brain, was followed by synechia (posterior) occluded pupils, increased tension, and pain in the eyes. Mr. Dixon excised about one-fifth of the whole breadth of the iris in either eye; vision was improved, and the pain and tension entirely ceased.

II.—Excision of the Iris.

In eleven cases iridectomy has been adopted for preventing the recurrence of inflammation. These cases were syphilitic and in a chronic state; they were all improved by the operation, in none has a fresh attack yet occurred, and the pain and tension have been prevented. In one of the cases the operation was performed during an acute attack of iritis; a nodule of lymph being removed with the piece of iris; this case got rapidly well. In several cases changes in the deeper tissues of the eye were perceptible.

In two cases recurrent rheumatic iritis has been treated by iridectomy. From one-fourth to one-sixth of the whole breadth of the iris was removed. The incision was generally made with a cataract knife and through the margin of the sclerotic, close to the upper corneal edge; the iris was removed with the hook or forceps and scissors; any blood escaping into the anterior chamber ought to be scooped away; it is less easily resorbed.

Iriddesis was performed in a case of rheumatic iritis; the aqueous had a yellowish tint, and the iris had the appearance of one which was likely to bleed much.

The following cases in which iris-excision has been performed may be particularised :—

Staphyloma.—In this case the staphylomatous tissue, whitish with bluish thinned spots in it, occupied the lower

half of the cornea; about one-third of the upper part of the iris was removed, and in a month the staphyloma had disappeared. Age of the patient, 8.

Perforating ulcer of the cornea, followed by a fistulous opening in the whitish cicatrix. The patient, a girl aged 20, states that the eye had been affected for more than a year; a portion of the upper part of the iris was excised by Mr. Streatfeild, and vision was improved, but the fistulous opening remained.

Perforating ulcer at the lower part of the cornea with considerable prolapse of the iris. The excision of a portion of the iris at its upper part was followed by improvement of vision and some diminution of the prolapse.

M. T., aged 56, a healthy looking woman (patient of Mr. Critchett), had a spontaneous inflammation of the left eye six years ago, which resulted in iris-adhesions, haziness of the cornea, thinning of the sclerotic in the ciliary region, and loss of vision to the perception of light only. The right eye inflamed spontaneously three years ago; vision became gradually worse, misty, with flashes of light, etc., and a year ago the patient could no longer see to read. Several inflammatory attacks have appeared lately; the pain has become very severe, and the tension of the globe has increased.

The sclerotic was thin and bluish, its vessels were enlarged, the cornea was slightly hazy (finely greyish dotted); the anterior chamber was small, the pupil irregular and fixed; its area greenish. With the ophthalmoscope a faint red light was produced in the vitreous space. The patient had fair perception of light. A portion of iris was excised on the 8th of March, from its upper part; slight ophthalmia followed the operation. The pain subsided entirely on the third day; the iris remained in apposition with the cornea for a week, when the anterior chamber began to reappear on the 1st of April. The tension of the right eye is normal; the anterior chamber is good; the aperture in the iris clear; the pain has subsided; (O.S.) the optic nerve and retina are diseased; the patient perceives shadows.

On the same day a similar case was operated on with the same result.

E. B., aged 56, a pale, weakly, nervous woman (patient of Mr. Poland) observed four years ago, while at work, a sudden dimness, without pain, come before both eyes; perception of light was lost for a few days, when, after the application of six leeches to either temple, vision returned in both eyes. A month after this, dimness, sickness, and slight pain reappeared in the right eye, but again subsided until the 9th of March, seven weeks ago, when pain and dimness in the right eye recommenced.

Present state, 9th March.—(Left eye.)—The pupil contracts sluggishly; vision is defective for near and tolerably good for distant objects; otherwise the eye appears normal. (Right eye.)—The conjunctiva is slightly injected; the central portion of the cornea slightly hazy; the aqueous somewhat turbid, the pupil oval and fixed. The patient perceives shadows with this eye; the pain round the orbit is severe.

About one-fifth of the iris at its upper portion was removed; the anterior chamber was entered by a sclerotic incision; some blood oozed from the lower anterior surface of the iris after the escape of the aqueous; this was removed with the scoop; the aperture in the iris was then clear.

Some difficulty occurred in finishing the sclerotic incision, and the rotten state of the conjunctiva and iris was remarkable.

March 16th.—No redness, slight pain; tension normal; less corneal haziness; good anterior chamber, clear pupillary aperture; (O.S.) media transparent; retina and optic entrance normal; in the choroid traces of former inflammation appeared. The patient recognised small objects and had imperfect vision for distance.

W. B., aged 39, a strong, healthy looking coastguardsman (patient of Mr. Bowman, 26th October, 1858), observed while writing, three months previously, a sudden pricking sensation in the right eye, with indistinctness of the letters, which appeared "as if seen through running water;" large distant objects could not be recognised since this happened. The patient suffered from palpitation, but appeared otherwise in good health. The left eye was normal; the right was not painful or red; the pupil was dilated, fixed, and acted sluggishly in concert with the left. (O.S.) the media were transparent, the retina was slightly hazy, and sprinkled with small roundish blood-spots, which were most numerous

round the optic entrance and at the yellow spot; the entrance was ill-defined and reddish, few vessels appeared to pass through it; the choroidal red was uninterrupted.

25th March, 1859.—(O.S.) The blood-spots appeared fewer in number, some had changed colour; their margins were less defined; many appeared to have been replaced by white spots; the retina was less hazy, the optic entrance less congested; more large vessels were perceptible; vision was but slightly improved. Excision of an upper portion of iris (about one-fifth) was performed; some blood, which oozed from the anterior surface of the iris, was removed with the scoop, so that its resorption should not also be required of the eye after the operation.

1st April.—The pupillary aperture is clear, there is no irritation; the sclerotic incision has healed. The patient has no perception of distant objects; he recognises a watch held at about six inches distance without being able to distinguish the hands; with this eye objects appear smaller. An ophthalmoscopic examination has been thought unadvisable.

The last three cases are under observation.

Iridectomy has been performed in a case of atrophy of the optic nerve and retina, and in a case of capillary apoplexy of the retina. These cases are under observation; no ill results followed the operations.

The operation has also been applied to two cases of acute ophthalmia, following perforating wound of the eyes in the ciliary region; the pain and tension were relieved in both cases, vision was not improved, and one of the eyes was subsequently excised.

The surgical treatment of glaucoma has undergone no modifications; it may be said that the cases appear to become less numerous. A more detailed account of this subject will be given at some future time.

REPORT

OF RECENT GIFTS TO THE ROYAL LONDON OPHTHALMIC HOSPITAL LIBRARY AND MUSEUM.

By Dr. Bader, *Curator and Registrar.*

TO THE LIBRARY.

By Professor Von Ammon,

1. Von Ammon's Die Behandlung des Schielens, 1840.
2. Von Ammon's Die Sclerectomie, 1831.
3. Von Ammon's Geschichte der Augenheilkunde in Sachsen, 1824.
4. Von Ammon's Das Symblepharon, 1834.
5. Von Ammon's De Iritide, 1838.
6. Von Ammon's Neue Beiträge zur Lehre von den angebornen Fehlern der Iris, etc., 1852.
7. E. O. Peters' De Blepharoplastice, 1836.

By Professor Donders,

MacGillavry, De oculi accommodationis quantitate.—Utrecht, 1858.

By Mr. Ainley, *of Bingley,*

1. Samuel Cooper on Cataract, 1805.
2. Bowen on Cataract, 1824.
3. Evans on Cataract and Closed Pupil, 1815.
4. Richter on Cataract (in English), 1791.
5. Wathen on Cataract, 1785.
6. Horn on the Seat of Vision, 1818.
7. Wallis (translator) Nosologia Methodica Oculorum, 1785.
8. Kennedy's Ophthalmographia, 1713.
9. Sir William Read on the Eyes, n. d.
10. Crampton on the Entropeon, 1806.
11. Gibson on Artificial Pupil and Soft Cataract, 1811.
12. Maître-Jan, Traité des Maladies de l'Œil, 1722.
13. Crosse's Treatise of the Eyes, 1708.

14. Duddell's Diseases of the Horny Coat of the Eye 1729.
15. Simpson's Tentamen inaugurale de oculo humano, 1779.
16. Muter on Cataract and Artificial Pupil, 1811.
17. Adams on Ectropium, etc., 1812.
18. Farrell on Ophthalmia, 1811.

} Bound together.

19. O'Halloran on Ophthalmia, etc., 1824.
20. Serny on Ophthalmia, 1809.

By Mr. CURLING,

1. Gosselin sur le trajet intra-oculaire des liquides absorbés, etc., 1855.
2. Gosselin sur l'ophthalmie causée, etc., 1855.

By Mr. DIXON,

Dixon on Diseases of the Eye, 1859.

TO THE MUSEUM.

By Mr. SOLOMON,

1. An Eyeball (ophthalmitis).

By Mr. PENFOLD,

An Eyeball (staphyloma).

By Dr. BRONNER,

1. An Eyeball (staphyloma corneæ).
2. Ditto (ossification).

By Dr. WILLIAMS, *of Cork*,

A Tumor removed from the Sclerotic.

By Mr. HUTCHINSON,

A Stereoscope and 12 Stereoscopic Portraits of Hereditary Syphilis.

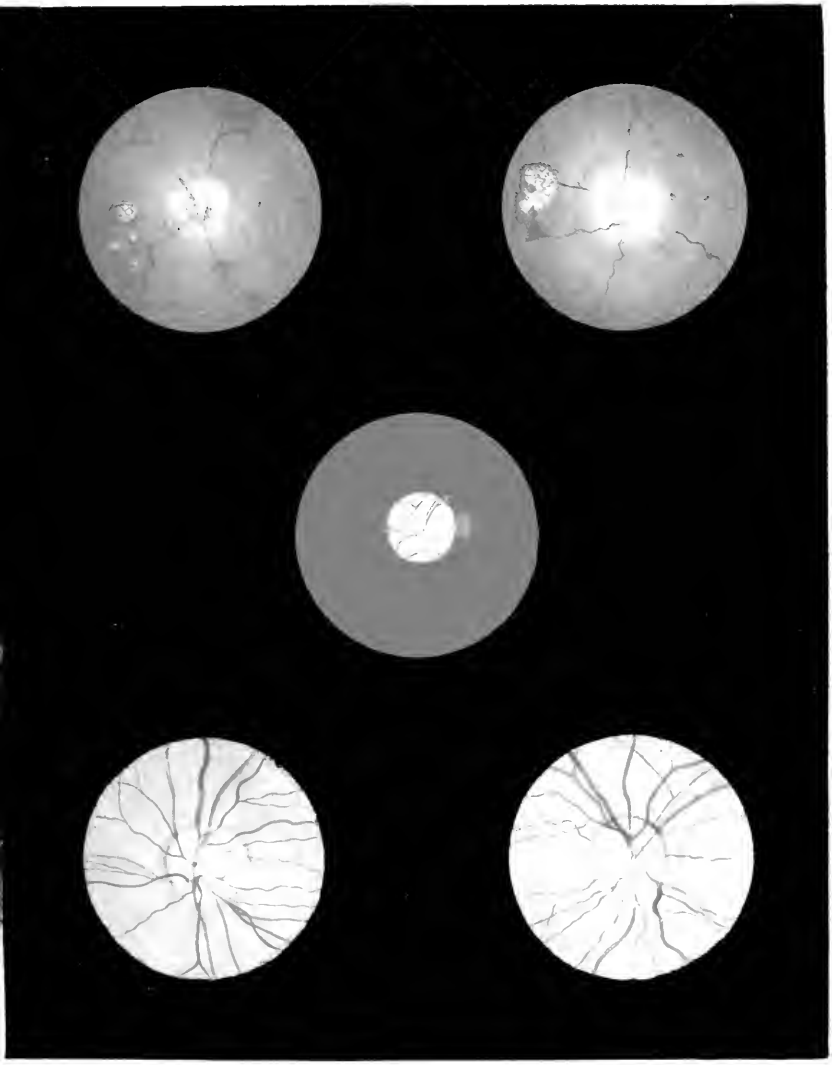

OPHTHALMIC HOSPITAL REPORTS,

AND JOURNAL OF THE

ROYAL LONDON OPHTHALMIC HOSPITAL.

No. IX.

October, 1859.

With the present Volume I have commenced the use of a tinted instead of the very white paper which had been before employed for the Journal. My reasons for so doing may, perhaps, be well told, especially as the advantage of using such paper is yet little recognized.

Many years ago Mr. Babbage had printed, experimentally, specimens of his Logarithmic Tables* in black ink, on a hundred and forty different coloured papers; and also in various coloured inks on all these coloured papers. He ultimately chose, for the publication of his work, black ink on an ochreous yellow paper;† and in the Preface his conclusions on the subject have been given.

ON COLOURED PAPERS.

Mr. Babbage's Rules of typographical perspicuity generally have reference only to the printing of tables of figures; but those which may be applied to other books are the following:—

"1st. *The clearness or facility of reading does not depend on the size of the type alone, but on the proportion of the type to the interval between the lines.*

"2nd. *Figures of the same, or nearly the same height, are preferable to those in which some of the digits rise above and others fall below the line,* because they interfere less with the space between the lines.

"There are some causes of indistinctness in tables which arise from other sources. It frequently happens that

* "Table of the Logarithms," etc., by Charles Babbage, Esq., M.A., F.R.S., etc.

† The description of Plate IX, contained in the present number, is printed on paper such as that used by Mr. Babbage.

"10th. *The impression of the figures on one page is reversed on the opposite:* this sometimes arises from the volume having been bound before the ink was quite dry, a fault which should be most carefully avoided. It is, however, more frequently caused by the bad quality of the ink employed by the printer.

"Another defect arises when

"11th. *The transparency of the paper admits the figures on the reverse side to appear through.*

"In order to try whether

"12th. *Coloured paper is more favourable to distinctness than white,* I had a page set up, and printed on paper of various colours and shades. Almost all those whom I consulted agreed with me in giving the preference to the coloured papers, but the particular tint was not so unanimously fixed upon. Yellow appeared to have the preference, and it is that which I have chosen for the first impression. The tint is at first considerably too deep, but it fades on exposure to the light. I should therefore recommend, that previously to binding this volume, the sheets should be exposed for several days to the action of the sun.

"It is not probable that the colour first selected should be found the best; we must wait the result of time and experience to determine that point. It may, perhaps, be found that different eyes require different colours; and it is not improbable, that a tint which is least fatiguing to the eye when used by candlelight, may not be the best adapted to calculations by daylight."

Several editions of Mr. Babbage's "Table of the Logarithms" have been printed on the *same* yellow paper; some have also been issued on white paper, but the former are always most in demand. A gentleman, much in the habit of using logarithms, ordered of his bookseller Mr. Babbage's work, and unexpectedly finding it printed on coloured paper, he was much disappointed; but afterwards, he was so much pleased with it, that he wrote to Mr. Babbage saying, that whereas he had only been able to use his eyes at night with books printed on white paper for an hour without resting them, he could with the new book continue for three hours without exertion. It has been remarked that "It is impossible to know whether a scarlet colour has the same appearance to me which it hath to another man."* For myself, I have always preferred tinted paper; and I have especially considered the yellowish paper much better than that of a

* Reid's "Inquiry into the Human Mind," 1785.

blue tint (which is so much used for writing paper), since I have seen and compared two editions (Dodsley's) of a work exactly alike, but that the paper was bluish in the one, and yellowish (as of old books, unbleached) in the other: the former was disagreeable, if not fatiguing; whereas the slight tint of the latter by daylight was very pleasant to read.

It is probably, not for the sake of greater legibility, that the advertisement pages in "Bradshaw's Railway Guide," "The Weekly Shipping List," etc., are of a yellow colour, and not white, as are those of their proper contents; and if, as in these instances, the type is very small, the paper thin, and the ink not *absolutely* black, it is possible that the white paper (and black ink, producing the greatest contrast) is best. The amount of contrast between paper and ink, necessary or agreeable to different persons, certainly varies much. Lately, when writing on a rather thin paper, I found it most agreeable when the sheet was open singly on the dark table, thus subtracting from the whiteness of the paper; but others whom I have asked to try the same way of using the paper have not always agreed with me. It might answer as well to use coloured light as coloured paper, but then we could only read under certain conditions; on the other hand, a disadvantage of having the paper coloured is, that its tint or shade is made to vary according to the amount or kind of light that is used; for this reason I believe that, as the yellow paper of Mr. Babbage's book is so pleasant for candle-light use, so that now used for the Ophthalmic Reports is better for ordinary daylight. I believe, also, that the colour should be deeper in proportion to the size of the type, for I have observed that large placards, on paper of a darker shade than could be used for any printed book, are very easily to be read.

I do not know why it is thought desirable to obviate the yellow colour of some artificial light, and yet that the yellow-coloured paper is most agreeable for reading; if it is so,* the reason remains to be proved, but it has occurred to me as an argument worth considering, that the organ of vision only requires for its use the luminous rays of the spectrum, not the heating or the chemical rays which, no doubt required for our health in other ways, are not necessary for seeing. Yellow occurs near the centre of the spec-

* "Yellow is unquestionably the colour (properly so called) most *visible* to all eyes."—Wilson "on Colour Blindness," etc., 1855, p. 127. See also pp. 34 and 166.

trum, *i. e.*, away from the heating and chemical rays (farthest from the latter); and green, which, after yellow, seems to be pleasantest to read with,* is next to it in the spectrum, and *equally* remote from its heating and chemical extremities, where, moreover, it appears to me that the colours most fatiguing to the eye are found. Much red is always so considered, and a bright indigo (*ultramarine*) blue is to me quite as disagreeable when a sufficiently large surface is intently viewed. To this evidence I must add that Dr. Bader and other literary contributors, say they very much prefer reading from the coloured paper now used for the Journal: and the printers have remarked that the new paper "takes the ink" particularly well, a fact of some importance, when the number of our woodcuts is considered.

J. F. Streatfeild.

PUBLISHED CASES.

Case XXVII.—Melanotic Tumor (external) of the Sclerotic.

By Dr. John Williams (*of Cork*).

Ellen Sheehan, aged 50, a delicate looking woman, a widow, applied for advice at the Cork Eye Institution, in the month of June, 1858. A dark globular tumor, about the size of a hazel nut, occupied the outer portion of the left eyeball, which it completely obscured; it protruded between the lids and prevented their approximation. On elevating the upper lid the tumor was found to be mushroom-shaped, and very intimately connected with the sclerotic by a short pedicle, it encroached for a short distance on the cornea, which was quite clear; the iris was also healthy in appearance, and acted well. Vision was as perfect in this eye as in the sound one.

The history she gave of the growth of the tumor was, that for *some years past* she had noticed a black speck '*on the white*' of the eye, at its outer side, that some medical treatment was attempted, but it remained the same, and that for the last six months she had noticed its growth to be more rapid, for until lately she could 'shut her eye.' She

*Not the pleasantest, because generally the contrast between it and the (black) ink is insufficient?

never complained of pain in the tumor, but, being alarmed by its quick growth, she now sought advice.

I placed a ligature, with the assistance of my friend Dr. Hobart, round the pedicle of the tumor, which I then removed with a scalpel, between the ligature and the sclerotic. After the hemorrhage, which was very considerable, had ceased, I perceived that complete removal of the tumor could only be effected with loss of the eye, its connection with the sclerotic was so intimate.

The advantage of the operation was, as may be expected, only of short duration, for the tumor soon showed a disposition to grow. The only means whereby to obtain a radical cure would have been extirpation of the globe; and, as vision in the eye was still by no means impaired, the patient would not consent to this.

I forwarded the tumor to Dr. Bader, Curator of the Royal London Ophthalmic Hospital Museum, for examination, and the following is his report "The melanotic tumor, besides brown pigment granules, contains cancer-cells in different stages."

Fig. 1.

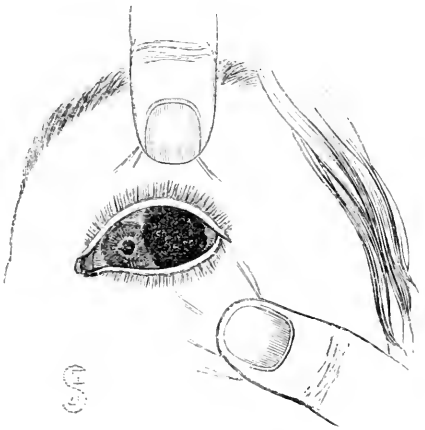

In January, 1859, the tumor had continued to grow, its margins were well defined and, unlike its former appearance, its base was broad: it had continued to extend over the cornea, but externally a small portion of the sclerotic was seen, when the patient turned the eye inwards, as in the accompanying illustration, from a photograph taken at this time. Vision was still pretty good, and I felt convinced that the morbid growth was still connected with the sclerotic only. In this case, as in those in which melanosis affects the interior of the globe, the growth of the tumor was slow, but up to this time it was without pain. Was it a secondary affection? I should think not in this case.

In May, I recommended total removal of the globe to the patient, who was fully assured of the inutility of a repetition of my former operation. The tumor had increased in size, its base occupied nearly all the outer visible portion of the sclerotic, but it had not encroached on more than one-fifth of the cornea, it protruded between the lids, and interfered with their movements. Vision was still tolerably good. The patient complained of intense lancinating pain at different times in the eye. Now, however, she was obliged to go to Dublin to reside, and there she came under the notice of Mr. Wilde, who on the 3rd of June communicated to me his opinion of the case, that it was "a very peculiar tumor of the sclerotic,"——of a "melanotic appearance." Soon after this time Mr. Wilde removed the eye, and on the 20th of July he told me that "she recovered favourably, and is now, I believe, very well." Again, on the 6th of August, he wrote to me that "she is very much improved in health since the eye was removed;" in this letter was enclosed Professor Wright's report of the minute examination of the globe, which was the following:—

"I found that the humors and lens had escaped owing to a laceration of the eyeball. The retina was (as far as could be judged) normally attached; the optic nerve was not atrophied, and the choroid was apparently quite unaffected. The ciliary muscle was at one spot more than normally adherent (by bands of membrane) to the sclerotic, and at this portion the latter was perforated by numerous vessels that went to the tumor situated beneath the conjunctiva and inner portion of the sclerotic. The tumor itself was bilobed, of large growth, and implicated a considerable extent of the conjunctiva, it was already encroaching inward, in the eyeball. It did not present under the microscope the appearance of malignant growth; the dark colour was probably owing to the large supply of venous blood, loaded with choroidal pigment."

This opinion differs from mine; the appearance of the woman indicated, to me at least, the presence of malignant disease; and, although the well marked *jaune pâle* of cancer could not be said to exist, that peculiar expression of the face so very frequently observed in malignant cases is *yet* plainly to be seen, and I fear a return of disease in the orbit, if it does not already exist, in some internal organs. Professor Wright's examination has, however, proved my diagnosis as to the seat of the tumor to have been correct; and

even if the latter were, as he thinks, benign its rapid growth —very perceptible indeed of late—would have rendered the destruction of the eyeball inevitable.

Case XXVIII.—Voluntary Power of using Horner's Muscle (*TENSOR TARSI.*)

By Dr. Jago (*of Plymouth*).

(*To the Editor of the Ophthalmic Hospital Reports.*)

Sir,—In compliance with your wish, I send you some remarks on the power I have over the *tensor tarsi* muscle which you remember having observed in me many years ago.

I cannot find that the action or the uses of this muscle have been *demonstrated* by any author within my reach, nor have I ever known any one, besides myself, who has *voluntary* control over it.

In me the *caruncul*æ and the *plic*æ *semilunares* are of normal size, and well defined. The *rim*æ *palpebrarum* are rather large. From my earliest years I have been able to move the eyelids in an unusual manner, and quite different from the ordinary way by the orbicularis.

Ellis says, "the *tensor tarsi* muscle, small and oftentimes very indistinct, is situated behind the tendon of the *orbicularis.* It arises from the vertical crest which divides the orbital surface of the *os unguis* into two portions that run outwards along the lacrymal canals, and are inserted, one for each eyelid, into the cartilaginous processes in which the *puncta lacrymalia* are situated, and also into the tarsal cartilage of the same lid. The muscle lies behind the tendon of the *orbicularis,* and against the lacrymal *sac.*"

It is stated by Cruveilhier that "this small muscle arises from the vertical ridge of the *os unguis* which forms the posterior border of the lacrymal groove; from this point it passes transversely outwards along the posterior tendon of the *orbicularis palpebrarum,* and divides into two tongues, a superior and an inferior, which correspond to the lacrymal canals, and terminate at the respective lacrymal *puncta.*" He regards these fibres as a "dependence" of the *orbicularis palpebrarum.*

In me the voluntary contraction of this muscle takes place instantly when willed, and with considerable force, which is *more in the under than in the upper lid.* The contraction can be sustained for some time, easily for half a

minute, after which time the *tensor* begins to be tired. This can be done in either eye alternately and singly, or in both together. The appearance produced is illustrated by the diagram, which faithfully represents the relative difference in size and shape of each *rima palpebrarum*, when the muscle is in action, as compared with it when at rest.

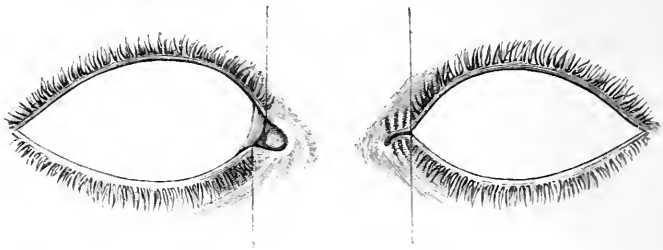

When the *tensor* contracts, the inner angle of the inferior tarsal cartilage is drawn inwards towards the nose, and *upwards* as far as the *upper border* of the *caruncula*, so as to cover it: at the same time also the corresponding angle of the upper tarsal cartilage is pulled inwards and *downwards*, as far as the upper border of the *caruncula;* where both inner angles of the tarsal cartilages meet: and together are still more drawn *inwards* towards the vertical ridge of the *os unguis*. The inner commissure becomes a mere groove of a semilunar form, its concavity looking downwards and outwards. The skin at the inner angle of the eye becomes puckered, the *caruncula* and *plica semilunaris* cannot be seen, being covered and pressed more deeply into the orbit by the inner angle of the *lower* tarsal cartilage.

During the action of the *tensor*, the eyeball remains passive or not, as I will it; and there is *no movement* of the *orbicularis*, nor any corrugation of the eyebrow.

In all degrees of contraction of the *tensor tarsi* the *puncta lacrymalia* continually keep their usual direction towards the eyeball, and neither they nor the eyelids are everted or inverted.

When the eyes are shut the *tensor* simply draws both eyelids transversely nearer to the nose, and the inner tarsal angles are pulled more into the orbit towards the vertical ridge of the *os unguis*.

When the *tensor* is not in action, the lids bear with the usual force against the front of the eyeball.

The outer commissure of the eye keeps its position, and is not affected by the action of the *tensor tarsi.*

What is the use of this little muscle? Does it, by intermittent contraction on the lacrymal canals, assist in *pumping* away the tears? When it is considered that the *puncta* are of less diameter than the canals, that the muscle is inserted close to each *punctum,* and following the direction of each, is attached to the vertical ridge of the *os unguis,* that each lacrymal canal has a separate orifice *in the sac,* that the muscular power of the *inferior* division of the *tensor tarsi,* to which the most tears must flow, is, in me, at least four times more than that of the upper, that just below the opening of the inferior lacrymal canal into the sac, sometimes a circular, and often a semicircular *valve* is found; I think that all this mechanism points to a very important, though not perhaps the sole, use of Horner's muscle, and that it is not by capillary attraction alone the tears find their way through the lacrymal canals.

The name, *tensor tarsi,* does very aptly indicate an important use; and it is not at all improbable, although few may have voluntary power over this muscle, that in every person it always acts as a *regulator,* with the orbicularis, in keeping up that amount of tension necessary for a perfect and protecting apposition of the lids to the eyeball under every situation of the eye.

I have quoted Cruveilhier's observation that the muscle is a "dependence" of the orbicularis; this may appear so on dissection, but in my own case it seems to be ascertained that the *tensor tarsi* is as much an independent muscle as any other.*

I remain, Sir, Yours etc.

Case XXIX.—Phthiriasis palpebrarum.

By Mr. W. W. Harkness.

The following case seems worthy of record, both on account of its comparative rareness, and also because opportunity was afforded of accurately determining the nature of the insect infesting the eyelashes.

For the very faithful drawings illustrating the case, I am

* This gentleman has similar voluntary power over the *attollens* and *attrahens aurem.*—Ed.

indebted to Mr. Streatfeild, amongst whose out-patients it occurred.

R. P., æt. 50, a German jewess, residing in Houndsditch, applied at the Moorfields Hospital on account of a chronic ophthalmia of the left eye. On examination the lashes of the *right* upper eyelid were found to be thickly studded with a number of dark brown bud-like bodies, of about $\frac{1}{48}$ inch in length (Plate IX, fig. 1), and which microscopical examination proved to be the eggs of the *Phthirius* or *Pediculus pubis*. One or two *Phthirii* were also found half-hidden among the lashes, which were spread and seemed to be kept apart by the numerous *ova* attached to them. The eyebrow and, when first seen, the lower lid were free from eggs and insects. The left eyebrow and lashes were also unaffected.

The patient was not conscious of anything amiss with the *right* eye, and did not appear to suffer any inconvenience from the presence of the insects.

Dalrymple ("Pathology of the Human Eye") mentions his having seen three cases of this complaint in children, and gives a representation of the eyelashes, but not of the insect, although he calls the disease *Phthiriasis*. Wedl ("Grundzüge der Pathologischen Histologie"), in describing the *Phthirius*, says that it is met with in the hair of the *pubes, axilla,* breast and eyebrows. I have been unable to find a representation of an insect actually taken from the eyelashes.

The insect represented in Plate IX, fig. 2, was taken from the eyelashes, and mounted in glycerine, and will be seen to be a well-marked specimen of the common crab-louse or *Phthirius*. In fig. 4 is represented the ordinary appearance of the eggs as seen with a magnifying power of eighty diameters; in fig. 5, the egg has been rendered transparent by glycerine, and examined with a power of one hundred and thirty; in this the fœtal louse is distinctly seen. The lashes were found to have on them from one to five eggs; the latter are pear-shaped, and cemented by their narrow ends to the shafts of the hairs with a transparent cement: the broad end of the egg has a lip, to which is attached a conical lid, studded with little nodular processes; this falls off when the fœtus is fully developed; the egg is lined throughout by a membrane (*chorion*), which contains the fœtus. The lice were found adhering closely to the cuticle at the roots of the lashes, and considerable force was required to dislodge them.

On close investigation the patient was found to have the *Phthirius* in the hair of the *pubes,* and of the *axilla,* and the *Pediculus capitis* in that of the head. At a subsequent visit an egg resembling those of the *Phthirius* was found in the right eyebrow, as was also a *Phthirius* in the lashes of the right lower lid.

The particulars of this case clearly illustrate the fact that the louse, which infests the eyelashes, *is* the *Phthirius,* although the *Pediculus capitis* may exist at the same time in the head.

The treatment consisted in cutting off the eyelashes as closely as possible, and painting the edges of the lids with a strong solution of bichloride of mercury. After two applications the patient reported herself cured.*

Case XXX.—Protrusion of the Globe, with some symptoms of Aneurism.

By Mr. E. L. Hussey *(of Oxford).*

A laboring man, below middle stature, 42 years of age, but much older in appearance, came to me on the 20th of May, 1855, complaining of dimness of sight in his left eye, attended with pain deep at the back of the eye, and beating and throbbing in the eye and over the eyebrow, extending to the temple and ear, and much increased on stooping. The globe was prominent, and protruded towards the temple; the conjunctiva was vascular, chiefly over the rectus internus muscle. No tumor of any kind could be felt with the finger. The appearance of the eyelids was natural.

Upon making firm pressure over the trunk of the left carotid artery, the globe returned to its proper position; the man smiled, and said that his sight was clear, and that all pain and throbbing had ceased. Upon relaxing pressure, the globe again protruded, and the other symptoms returned.

History.—The man said his father died "in a decline." His grandfather lived to the age of 70. He had never been ill himself.

About two years before, being much tired by hard work through four days and nights in driving a waggon and team

* She only answered by her daughter; and as she did not appear again herself at the hospital the *cure* could not be completed. It is the more unlikely that she will be free from the complaint, even in the eyelids, since, it has been remarked, that these parasites progress from the pubes to the axilla, and then to the eyelids, always upwards.—Ed.

of horses, as he was lying on the waggon at night, "between sleeping and waking," he was suddenly alarmed by some of the team going wrong; he jumped off the waggon on to his feet, and immediately felt pain deep at the bottom of the left eye, and singing in the ear. He afterwards passed some bloody urine, and spit some blood for three or four days. The pain in the orbit, and the noise in the ear, lasted without perceptible intermission for about a month: since then, he had seldom been free from it for any length of time together. Latterly the pain had been more severe when it returned. The sight began to grow dim in the beginning of the last winter.

It was afterwards learned that he had been rather a free drinker; and that he had been subject to "fits" for many years. The belief of his family was that the accident he mentions, as the cause of his present suffering, happened during a fit, although he himself denied ever having had one.

On the 2nd of June, he came to me again: the eye was less prominent. He had had several days rest,—the consequence of a recommendation I made to his master.

On the 4th of July he came to me with the globe prominent *generally*,—not outwardly, as before. He had returned to his work, and to his ordinary habits of life.

On the 30th he came to me, alarmed by finding that the eye had become closed. He was admitted into the Radcliffe Infirmary on the 1st of August.

He now complained of constant pain in the top of the head and the left temple. He could only raise the left upper eyelid a little, by the occipito-frontalis muscle: the levator palpebræ did not act. On separating the lids with my finger, the pupil was seen to be moderately dilated, and motionless: he had no sight with the eye. Some feverish symptoms were present, unfavorable to the performance of any operation. I ordered that he should be kept quiet in bed.

On the 18th he seemed better in general health. He complained that the pain in his head was now felt in the right side, as well as the left. Pressure over the right carotid artery relieved the pain on both sides of the head. But the left globe did not return to its proper position, on pressure either on the right side or the left.

When he had been about three weeks in the ward, the nurse, passing by his bed late at night, saw him in a fit: he was flat on his back, struggling violently.

On the 19th of September he was discharged from the

Infirmary at his own request, with the intention of returning to his work as a farm laborer. His general health improved during his stay in the Infirmary: the local disease did not advance. As I inclined to the opinion that the disease within the skull was probably of a malignant nature, I did not urge any operation.

On the 1st of December I saw the man again,—much altered in general appearance; and not able to follow his work. The left eyelid was closed; the globe not more prominent than when he left the Infirmary. On raising the upper lid with my finger, he was able to see with a fair amount of distinctness.

On the 5th he was re-admitted into the Radcliffe Infirmary.

His health continued to fail. His fits were more frequent, chiefly in the night. At times his temper was very violent, and he became childish and unmanageable. On the 7th of February his right arm was observed to be wholly paralytic.

A blister now and then to the back of the neck, when he complained more than usual of pain in the head, often gave relief: and purgative medicine was regularly administered with benefit.

In the beginning of April he was removed to the workhouse at Abingdon, under the care of Mr. Stone. The sight of the left eye was completely gone. There was rather a free serous discharge from the conjunctiva, tinged with blood; the result, as it seemed, of the irritation caused by the habit of poking his left fore-finger into it at the inner canthus. The eyelids were tightly stretched over the globe, which had become rather enlarged and hard. He was able to stand, but hardly able to walk without support; and he had recovered some little power over his right arm.

He died in the workhouse, on the 25th of July, 1856, fourteen months from the time of his first visit to me. Mr. Stone tells me that for some time before death the globe had lost all its natural appearance, and protruded from between the eyelids, a large, hard and raw substance. The skin of the upper eyelid was ulcerated superficially. A stream of blood flowed almost without intermission, over the cheek, from a depression in the middle of the globe, which seemed to be the site of the iris. Free bleeding also took place many times from the nose. The patient's friends would not allow the body to be examined.

Case XXXI.—Diphtheritic Ophthalmia.

By Mr. Jonathan Hutchinson.

Herbert P., an infant at the breast, aged 6 months, was brought to the Royal London Ophthalmic Hospital on June 6th, 1859. He was a stout well-grown infant. The eyelids of both eyes were extremely swollen, the skin being tense and glazed. There was a certain amount of unhealthy secretion flowing from them, and the whole aspect of the patient was such as to suggest a diagnosis of per-acute purulent ophthalmia from which both corneæ had given way. I hardly ever recollect to have seen the eyelids more acutely inflamed, and the diagnosis alluded to was the one which I at once formed. On opening the lids of one of the eyes, however, a very different state of things to what I had expected showed itself. The conjunctiva in every part palpebral as well as ocular was concealed from sight by a thick layer of coherent lymph. This layer ended abruptly at the circumference of the cornea, and the latter structure was throughout dimly opaque, though still preserving its perfect form, and free from any appearance either of ulceration or sloughing. There was no true purulent secretion, what of fluid was present, consisting of a thin ichor. The pellicle was examined microscopically by Dr. Bader immediately after removal, and was found to consist of exudation cells entangled in the meshes of a loosely fibrillating matrix. The diphtheritic pellicle might be peeled off with forceps in fragments of considerable size, and the mucous membrane beneath it was swollen, intensely congested, and readily bled. The two eyes were in exactly similar conditions. The little patient was pale, with a hot dry skin and an oppressed aspect. His tongue was a perfect type of what is known as the strawberry tongue of scarlet fever. This state induced me at once to ask if the infant had had that disease. The reply was that he had not, but that his two brothers were then suffering from it. On further enquiry I found that one brother, a child aged 3, had sickened with scarlet fever, five days before the ophthalmia commenced in the infant. With regard to the latter, it appeared that the eyes had been attacked simultaneously four days before application at the hospital. There had been considerable

discharge from the nostrils, and the diphtheritic inflammation evidently extended in a slight degree to the nasal passages. Careful inquiries were made as to the sanitary condition of the patient's residence, but it could not be ascertained that it was at all of a character likely to be prejudicial to health. Scarlatina was said to be prevalent in the neighbourhood.

Treatment.—Having separated the lids by means of a speculum, I carefully peeled away, partly by scraping with a scoop and partly by forceps, the whole of the false membrane, and then brushed the conjunctiva in every part with an almost saturated solution of nitrate of silver. A saturated solution of chlorate of potash was prescribed to be used as an injection into the eyes. Internally the administration of chlorate of potash with liquor cinchonæ was prescribed.

Subsequent progress.—On the following day I repeated the application of the nitrate of silver. The diphtheritic exudation had been partially reproduced, but not very extensively. On the third day the condition of the eyes seemed much improved, the swelling of the lids had greatly diminished, and there was very little false membrane. The corneæ however were still quite opaque. The mother on this day directed my attention to a rash on the child's chest. It consisted of scattered minute red points, but more resembled certain forms of *lichen* than the eruption of scarlet fever; the skin was still harsh and dry, but the child's tongue was improving and its papillæ less prominent. There had been throughout no sore throat whatever, nor any inflammation of the mouth. On the fourth day the rash had disappeared. There were now central sloughs on both corneæ. On the seventh day the sloughs were separating, and it was evident that both eyes were lost. The diphtheritic inflammation had now wholly passed off. The child was still more feeble and looked very ill; ammonia in combination with bark was ordered. On the tenth day the mother of the infant directed my attention to a large abscess which had formed over the right shoulder. It fluctuated freely, and having very little induration of the surrounding cellular tissue, much more closely resembled a pyæmic deposit of pus than an ordinary abscess.

After the date of the last note the child was not brought to

the Hospital for several months. On Oct. 15th I again saw him. Both globes were then collapsed; their entire corneæ having been destroyed. The abscess over the shoulder had, I learnt, been opened, a few days subsequent to the last attendance at the Hospital, by another surgeon. It had healed, and no others had formed. The child still remained pale and cachectic, and its constitution had evidently received a most severe shock from the illness through which it had passed.

Remarks.—The above case was one of a class entirely new to myself: and so extensive and well-developed was the pellicular exudation which covered the ocular mucous membrane, that there could be no hesitation in considering it as a true diphtheria. The presence of scarlet fever in the same house, and the circumstance that the little patient himself, although without either sore throat or well characterised rash, had the scarlet fever tongue, are facts full of suggestive interest. The extreme constitutional depression, and the formation of a large *abscès froid*, are also strongly indicative of some severe and perhaps specific lesion of the blood. With regard to the treatment, it may be remarked that the remedies used were rapidly efficient in attaining their immediate object, that of preventing the re-formation of the false membrane. Had the case been seen earlier they might, in all probability, have saved the corneæ. As it was, the state of the latter was, from the first, almost hopeless.

PARALYTIC AFFECTIONS OF THE MUSCLES OF THE EYE.

(*continued*)

By Dr. John S. Wells.

(*Received September 16th.*—Ed.)

PARALYSIS OF THE RECTUS EXTERNUS.

As this muscle is the only one supplied by the sixth pair, and as it exerts no direct influence upon the vertical meridian, its paralysis affords the simplest specimen of the symptoms, *diplopia* etc, generally met with in paralytic affections of the muscles of the eye.

It is always advantageous in this class of diseases to follow a certain routine in the examination of patients, in order to prevent any symptom escaping our observation, and also to avoid the constant repetition which is apt to occur when we link together a number of unconnected and disjointed phenomena.

On a patient presenting himself with a supposed strabismus, his head should be steadily fixed, and he should be told to follow with his eyes an object (held at a few feet distance) moved in all directions, any abnormality in the movement of either eye will thus at once become apparent; we next, still letting him keep his eyes steadily fixed upon the object, cover one eye (say the right) with the palm of our hand, and then observe whether the left eye remains immoveable or makes an excursion before it can bring its optic axis to bear upon the object; in the latter case we know that the eye deviates from the object; if it moves downwards, it stood too high, and *vice versâ;* if it moves inwards, it had deviated outwards, etc.

Then covering the left eye we transfer the experiment to the right, and thus soon ascertain which eye is in general adjusted, and which deviates from the object.

Supposing a patient affected with a paralysis of the left *abducens* before us, let us go step by step through the different symptoms presented by him.

1. Holding an object (a lighted candle) in the horizontal median plane, about 4—5 feet from our patient, we find the optic axes fixed upon it (upon the closure of either eye the other makes no excursion). We move the object to the right of the patient, we move it upwards and downwards, still both eyes follow it accurately; when, however, it is moved somewhat to the left of the median line, the left eye lags behind, thus giving rise to a convergent squint, which increases in proportion as the object is moved to the left side. Every paralysis shows itself, when the eye is to be moved in a direction which necessitates the action of the paralized muscle; therefore in our case the inefficiency of the left *R. externus* does not become apparent until the eye has to be moved in any direction to the left of the patient. It is a curious phenomenon, the reason of which has not yet been properly ascertained, that every convergent squint appears the sooner, the lower the object is held, and is retarded if the object is held above the horizontal median line; with divergent squint it is just the reverse, for it shows itself sooner in proportion to the degree that the eyes look upwards.

2. In recent complete paralysis of the *abducens*, we shall find, when the healthy eye is closed and the object moved slightly into the left half of the field of vision, an attempt on the part of the left eye to follow it; not, however, in a horizontal direction, but in a zig-zag (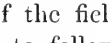) undulating manner, which movement is brought about by the alternating action of the two oblique muscles; the inferior oblique pulling the cornea slightly upwards and outwards; the superior oblique then contracting, pulls it downwards and outwards and thus the rolling, up-and-down movement is produced. It might be at first supposed that the two muscles would attempt a vicarious combination of their actions in order to produce a uniform horizontal movement, this, however, never takes place, owing

most likely to their combination not being required physiologically, and to the same reason must also be referred the fact, that in some cases (although the two oblique were healthy) the zig-zag movement was almost missing, and that it never exceeds 15°, somtimes reaching only 8°—10°,

3. *The secondary angle of squinting is greater than the primary.* We call the squint which arises from the deviation of the optic axis of the one eye from the object upon which the other is fixed, the *primary angle of squinting (or aberration)*. Upon covering the "fixing" eye with our hand, the other eye (making an excursion in order to adjust its optic axis upon the object) causes the covered eye to make an associated movement, thus giving rise to a squint, and this aberration is called *the secondary angle of squinting.*

In our case we shall find that on moving the object to the left side of the patient, a convergent squint (say of 1 line) will at a certain point arise owing to the inability of the left eye to follow the object; covering the right eye with our hand the left will make a movement (of 1 line) for the purpose of directing its optic axis upon the object, but the right at the same time makes an associated movement inwards of perhaps $1\frac{1}{2}$ — $2\frac{1}{2}$ lines; the secondary angle of squinting ($1\frac{1}{2}$ — $2\frac{1}{2}$ lines) is therefore greater than the primary (1 line). The reason of this is easily explained. The *Rectus externus* of the left eye being insufficiently innervated, it demands a greater impulse of the will to bring about this movement of 1 line, than would be required if its innervation were normal, but this increased impulse is also brought to bear upon the associated healthy *R. internus* of the right eye and thus produces a greater amount of movement in the latter. In all cases of paralysis it is therefore an invariable rule that the secondary angle of squinting is greater than the primary; and this is also a fact of great diagnostic importance, for in common squint dependent upon some changes in the muscle itself (the innervation being normal) we always find *the secondary angle of squinting equal to the primary.* If the left eye (squinting inwards) has to

make an excursion of two lines outwards in order to fix an object, the right eye will make an associated movement of two lines inwards.*

4. The erroneous projection of the field of vision is owing to the same cause as the last symptom.

If we close the right eye and tell the patient to strike with his finger quickly (if he does it slowly he will have time to correct his mistake) at an object held somewhat in the left half of his field of vision, he will miss hitting it, by going too much to the left; for the insufficiently innervated abducens demands, in order to bring the eye into the required position, as strong a contraction impulse as would in a normal state of the muscle effect a far greater amount of movement, therefore the patient at first, over estimating the amount of contraction, believes the object to lie more to the side of the paralized muscle than it in reality does, and consequently aims too much to the left of it. In time, however, if the paralytic affection be not too complicated, patients learn to correct these errors. The dizziness frequently complained of by them, is not necessarily owing to any cerebral lesion, but generally to the confusion which arises from the difference between the real and imaginary position of objects.

We have now to turn our attention to a symptom, the value of which cannot be too highly estimated, viz., the *diplopia;* for from the observance of the double images we

* Alf. Græfe directs the linear measurement of a squint to be taken thus; marking upon the lower lid the spot which would correspond to an imaginary vertical line drawn through the centre of the pupil of the squinting eye, the other eye is closed and the patient directed to fix the squinting eye upon an object held at 6-8 feet distance, the spot which now corresponds to the centre of the pupil is again marked upon the lower lid, and the distance between the two marks gives the linear size of the squint.

Fig. 1.

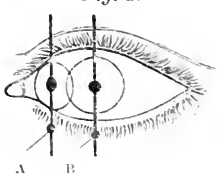

A the mark corresponding to the centre of the pupil when the eye is squinting, B the mark corresponding to the centre of the pupil when the eye is fixed upon the object, distance between A — B the size of the squint.

can diagnose which muscle is affected, we can ascertain whether a paralysis is progressing or not, and lastly we find in them a great aid for determining the means of cure.*

An object only appears single when both optic axes are directed upon it, any pathological deviation of either optic axis must necessarily cause diplopia, as the rays of the object do not then fall upon identical portions of the retina. The slightest degree of *diplopia* is that in which the double images are not yet distinctly defined (are masked), but seem to lie slightly over each other, so that the object appears to have a halo around it.

We meet with two kinds of double images. 1. *Homonymous images* where the image to the right of the patient belongs to his right eye, the left image to the left eye. 2. *Crossed double images,* where the image to the right of patient belongs to the left eye, that on his left to the right eye.

Homonymous diplopia is always produced (except in cases of incongruence of the retina) in convergent squint, for if the eye deviates inwards from the object, the rays coming from the latter will fall upon the inner portion of the retina, and the image will (according to the laws of projection) be projected outwards as in *Fig.* 2. Let I. be the right eye whose optic axis is fixed upon the object (*b*). II. the left eye

Fig. 2.

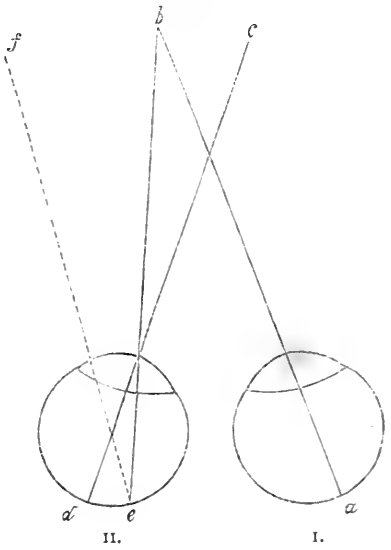

* When we find a difficulty in ascertaining with certainty which is the affected eye, owing either to the excessively slight defect in the mobility or

whose optic axis (*c d*) deviates inwards from the object, the rays from *b* therefore fall upon *e*, a portion of the retina internal to the *macula lutea* (*d*), and the image is consequently projected outwards to *f*; *b* and *f* are therefore the homonymous double images, the image *b* belonging to the right and *f* to the left eye.

Fig. 3.

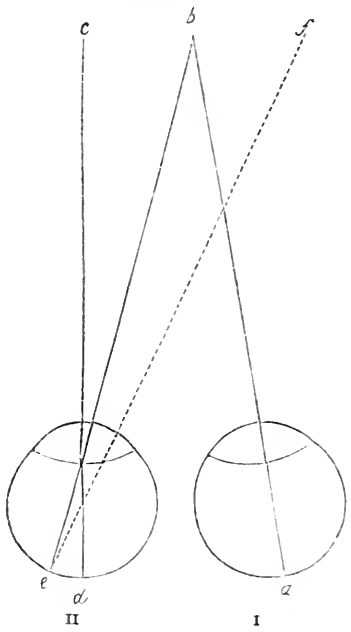

Crossed double images arise in divergent squint, for the one eye deviating outwards from the object, the rays from the latter fall upon a portion of the retina external to the *macula lutea*, the image is projected inwards, and crosses that of the other eye, as in *Fig.* 3.

I. The right eye, whose optic axis is fixed upon the object (*b*). II. The left eye, whose optic axis (*c d*) deviates outwards from the object, the rays from the latter therefore fall upon *e*, a portion of the retina external to the *macula lutea* (*d*), and the

to the very small amount of deviation, we may derive great assistance from the double images; let us, for instance, suppose that a paralysis of some muscle of the left eye has produced a very slight deviation of the optic axis and consequently *diplopia*; upon closure of the left eye its image disappears, but that of the right eye remains immoveable; if we close the right eye its image will also disappear, but the left eye having now to *fix* the object makes an excursion in order to bring its eccentric retinal image upon the spot of central vision and its image will not remain immoveable but moves to the situation held before by the image of the right eye. It need hardly be mentioned that the healthy eye must in these cases be the one always used for vision; if this be not so we may commit great errors by calling in the aid of the double images in the aforesaid manner.

image is therefore projected to *f*, crossing the image *b*; the image *f* which would lie on the patient's right hand, therefore would belong to the left eye, the image *b* which would lie on his left side, to the right eye.

If one eye squints upwards, the rays falling upon the upper portion of the retina, the image will be projected *beneath* that of the healthy eye. The reverse will be the case if the eye squints downwards, for then the rays fall upon the lower portion of the retina, and the image will be projected *above* that of the healthy eye.

We should never forget to ascertain whether the *diplopia* be uniocular or binocular, if it be the latter it will of course disappear upon closure of either eye.

5. Let us now examine the *diplopia* in our case. It will be remembered that the action of the *R. externus* is to move the eye horizontally outwards, without affecting the vertical position of the vertical meridian, the double images arising from a paralysis of the *abducens* consequently shew only *lateral* distances, being parallel and of the same height, and homonymous; the further the object is carried to the left of the patient, the more must the distance between the images increase, for the left eye, owing to its inability to follow the object, deviates the more from it the further the latter is moved to the left, and the retinal image, falling consequently more and more eccentrically upon a portion of the retina, internal to the *macula lutea*, will be of course proportionally projected outwards (to the left). The *diplopia* will be absent in the right half of the field of vision.*

It is an interesting fact, that although the *R. externus* has no *direct* influence upon the V. meridian, it yet, by assisting in the outward positions of the eyeball, helps in preserving the parellelism of the V. meridians of the two eyes: for

* In examining the double images of a patient, it is convenient to place a red slip of glass before the sound eye, for we thus enable him readily to distinguish the two images by their colour, and we also weaken the intensity of the image of the sound eye, and approximate it more to that of the affected one, whose image, owing to the rays from the object falling upon an eccentric portion of the retina, will be less intense in proportion to the distance of the spot upon which the rays fall from the macula lutea.

instance, if our patient be directed to look at an object held diagonally upwards to the left, the right eye will be moved into the necessary position by the *R. superior, Obliquus inferior,* and *R. internus*, its V. M. being inclined to the left; the left eye in order to be moved upwards and outwards, requires the *R. superior,* the *Obliquus inferior,* and the *R. externus,* but the latter is more or less paralized, therefore the eye remains almost straight, and the V. M. nearly vertical (instead of being inclined to the left) the parallelism of the V.MM. is therefore destroyed, and they *converge* at the top, the double images appearing to the patient to *diverge* at the top;* but as in conformity with the laws of normal vision, the image falling in the *slanting* meridian of the healthy right eye, appears *straight* to the patient, the image of the affected eye necessarily seems to him *slanting.*

6. The position of the head is characteristic; the patient carries it turned slightly round the vertical axis, to the left, in order to avoid *diplopia,* by bringing all objects more into the right half of his field of vision.

If a paralysis of the *Rectus externus* is acute, of not too great an extent, and not dependant upon a cerebral lesion, it may become radically cured; oftener, however, it is only relieved, the eye reacquiring only some of its mobility in the direction of the paralized musele; after this state has existed for some time, it often happens that the antagonist, from having only a diminished force opposed to it, pulls the eyeball over towards its own side, the structure of the muscle undergoing changes, which at last leave it in a permanent state of contraction, and in this way a convergent squint of the paralized eye is produced. When, however, the eye affected with paralysis enjoys the better sight of the two, the patient will, in spite of the inconvenience and effort, use it in preference to the other, and as it requires a greater will-impulse to bring the optic axis of the affected eye to bear upon an object lying towards the side of the paralized muscle, and as the sound eye at the same time makes an associated

* This will be explained in the next paper.

movement inwards (which *secondary* angle of squinting will be greater than the *primary*), its *Rectus internus* will in time become permanently contracted, owing to changes in its muscular structure, and thus we see a paralysis of one eye giving rise to a squint in the other.

ON THE USE OF PRISMATIC GLASSES.

As we shall have hereafter sometimes to mention the use of prismatic glasses in cases of paralysis, it may be as well just to glance at their action and mode of application. When a ray of light falls upon a prism, it is always refracted towards the base of the prism; if, whilst we look with both eyes steadily upon an object, the rays of which naturally fall upon both *maculæ luteæ*, a prism with its base towards the nose is placed before the left eye, the rays will be refracted towards the base of the prism, and fall upon a portion of the retina internal to the yellow spot, and be consequently projected outwards, giving rise to homonymous *diplopia*. As we are, however, very susceptible of double images, the eye will endeavour to unite them by a movement outwards, which will bring the rays again upon the *macula lutea*, but at the same time cause a divergent squint.

As the *recti interni* muscles are far more used than the *externi*, we find that the former are more capable of overcoming the effects of prisms than the latter, for if we place even a strong prism with its base towards the temple, we shall find but little difficulty in uniting the double images by the aid of the *Rectus internus;* let us, however, place a far weaker prism with its base towards the nose, and we shall most likely be unable to overcome it, owing to the comparative weakness of the *Rectus externus;* our power of uniting double images thus caused, is still less when the base of the prism is turned upwards or downwards.

As a means for curing paralysis, prismatic glasses are only indicated when no secondary contraction has yet occurred, when the deviation is but slight (not more than $1\frac{1}{2}$ line), when the power of uniting the double images by the

isolated action of one muscle exists, and a stronger prism than 14° is not required for overcoming the *diplopia*.

In a case of paralysis of the *abducens*, we apply the prism with its base towards the temple, for owing to the convergence of the optic axes, the rays from the object fall upon the internal portion of the retina; if a prism of 14° is found sufficiently powerful to bring the rays upon the *macula lutea*, and thus permanently to unite the double images, this number would be too strong to prescribe for the purpose of cure, as our object is to strengthen the paralized muscle, and stimulate it into slight contraction, by bringing the double images sufficiently close together for the muscle to be able to unite them without much effort, and then as the muscle gains power, gradually to diminish the strength of the prisms. We should, therefore, try a prism of 10°, and the effect would be the following:—

Let *Fig.* 4 be the left eye, suffering from paralysis of the *abducens*, and *a* an object, the rays from which (the eye being unable to bring its optic axis (*b*) to bear upon the object) fall upon a portion of the retina (*c*), internal to the *macula lutea* (*d*), the image is therefore projected outwards, to *e*; let us now interpose a prism of 10°, with its base towards the temple, and the rays will be refracted so as to fall upon *f*, which being still internal to *d*, the image will be projected outwards to *g*; but the double images *g* and *a* (the image of the right eye), are now so near to each other, that they become very confusing to the patient, and the eye, therefore, attempts to unite them, by turning its axis outwards, so as to bring the *macula lutea* (*d*) to the spot

Fig. 4.

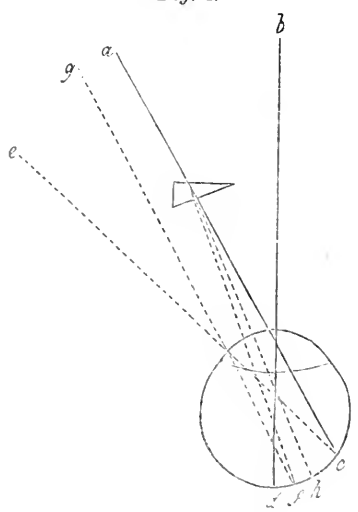

f, and this movement is brought about by the action of the *Rectus externus*, and if the patient can thus continue to keep the images united without any feeling of straining, we have chosen a prism of the right strength. When the muscle has been thus exercised for some time, we should try a prism of less power (7° perhaps), which would refract the rays only to *h* (*Fig.* 4), the muscle would then have to exert itself still more in order to make the *macula lutea* traverse the space between *d* and *h*, and thus by gradually decreasing the power of the prism, we shall in time cure the inefficiency of the muscle.

It is necessary, however, to be extremely careful in the selection of prisms, for we may on the one hand err by choosing them of too weak a number, and then the distance between the yellow spot and the place upon which the prism refracts the rays, will be too great for the muscle to overcome, and as double images are the more distressing and confusing the nearer they are to the *macula lutea*, the eye would endeavour (the muscle not being strong enough to unite them) to render them less distinct by giving the rays a a more eccentric position.

The rays from the object (*a*) *Fig.* 5. fall upon *c*, we apply a prism which refracts them only to *e*; the distance between *d* and *e* being too great for the paralized *abducens* to overcome, the *Rectus internus* contracts in order to bring the optic axis more inwards, and the rays will then fall upon *f*, a portion of the retina sufficiently eccentric to deprive the double image of much of its intensity and annoyance.

Fig. 5.

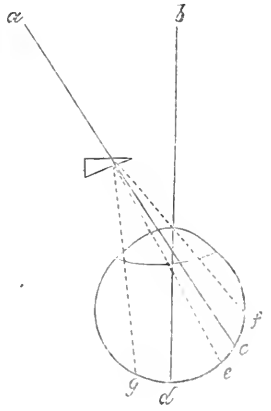

We may, however, on the other hand choose too strong a prism and bring the rays upon *g* (*Fig.* 5) a part of the retina external to the *macula lutea*, thus producing crossed double images; the *Rectus internus*

would then contract in order to unite the double images by turning the eye inwards and thus bringing the *macula lutea* (*d*) to *g*, and our intention of causing the *Rectus externus* to contract would be completely frustrated.

In cases where the patient suffering from squint is not affected with *diplopia* we should choose a prism which gives rise to double images with but a very small distance between them, and then the eye will endeavour to unite them.

We should direct patients when practising with prisms to look at a good sized object, placed at a distance of 10 — 15 feet, for the tension of the muscles is then far less than when they are accommodating their sight for an object at a very short distance.

We shall defer the consideration of the causes, prognosis and treatment of the paralytic affections of the muscles of the eye until we have gone through the diagnosis and symptoms of the individual paralyses.

(*to be continued.*)

FURTHER REMARKS

ON THE

FORMATION OF ARTIFICIAL PUPIL BY

IRIDDESIS.

By Mr. Critchett.

(*Received August* 31*st.*—Ed.)

In a former paper (Vol. I, page 220) I have described a method of forming an artificial pupil, then recently adopted in several instances, and that I had reason to believe possessed some important advantages over the operations usually had recourse to. It consisted in drawing a portion of the iris through a small wound in the cornea, and tying it with a fine loop of silk; its advantages, as I mentioned in that paper, are, that the iris-fibres are not torn or divided, that the pupil is merely altered in its shape and position, and retains permanently a definite size, a clearly defined boundary and contractility under the influence of light. Again, by this method we can regulate with great exactness the size and position of the pupil, and thus obtain every optical advantage that the circumstances and specialities of each individual case permit.

My present object is to describe some modifications that I have found it convenient to make in performing the operation of iriddesis, and also to describe some cases illustrative of the various morbid conditions for which this operation is suited.

In order to perform this operation with the requisite amount of minuteness and precision, a perfectly quiet state on the part of the patient is important. Except in rare cases this is best accomplished by the use of *chloroform*. The eye having been exposed by means of the wire speculum, and fixed in a convenient position, a broad needle must be

entered close to the junction of the cornea and sclerotic, and an opening made *just of sufficient size* to admit the cannula forceps. A small loop of fine *floss* silk, moistened, must then be *laid on the eye over the opening in the cornea*. The cannula forceps is then introduced through the loop and the opening in the cornea into the anterior chamber. The iris is then seized about midway between the ciliary and pupillary margin, or sometimes, if possible, rather nearer to the ciliary margin, and drawn out *to the requisite extent*. An assistant seizes the two ends of the loop with small broad-ended forceps, and *carefully ties it upon the eye*, so as to include and strangulate the portion of iris that has been drawn out. The ends are then cut off, and the operation is completed.

Usually about the second day all trace of the ligatured portion of the iris is gone, and the bit of silk, if it has not been washed off, may be taken away. It occasionally happens that the ligatured portion of iris, with the piece of silk attached to it, is drawn somewhat within the wound; when this is the case an end of the silk must be seized with forceps and drawn away. The possibility of such an occurrence proves the necessity of leaving the *ends of the knot rather long*. It is very rarely indeed that any irritation of consequence follows this operation; the iris becomes permanently adherent at the spot where it has been tied, so as to fix the pupil in its altered form and position.

This method of operating has been adopted with favourable results in the following groups of cases:—

1st. *Central leucoma*, corresponding in size and position to the natural pupil.

2nd. Where there has been a *penetrating ulcer* of the cornea, with some surrounding opacity, and the pupil is altered in shape, diminished in size, and drawn towards or behind the opacity.

3rd. Cases of *opaque capsule, with adherent pupil*, in which it is desirable to enlarge the pupil slightly in one direction, so as to expose a clear part of the lens.

I have performed the operation in each of these groups

of cases on several occasions, and I will select a specimen of each, as it may serve further to illustrate and explain the principles of the operation.

1. In November, 1858, a boy, aged 14, was brought to me by his mother at the Royal London Ophthalmic Hospital. He had dense central opacity of the cornea of both eyes, the result of severe strumous ophthalmia about five years previously. He could just manage to guide himself about, but his sight was so imperfect that he was unable to read even large print, and his education in consequence was entirely neglected; the pupils were active, but when contracted were hidden behind the opacity. The largest clear space of cornea was at the lower part of each, I therefore determined to alter the shape of the pupil in that direction, so as to bring it opposite to a clear part of the cornea; this I did in both eyes. The patient was placed under the influence of chloroform, and I drew out and tied a portion of the iris; but in the left eye I drew out rather more than I did in the right. The result of this was that the pupil in the right eye only extended to a point midway between the ciliary and pupillary margins of the iris (*a*), and retained its natural contractility, whereas in the left eye it extended as far as the ciliary attachment (*b*), and had lost its natural contractility. The boy made a rapid recovery without any unfavourable symptom. On the third day I was able to remove the silk, all trace of the prolapsed and ligatured portion of iris was gone, and the pupils were exactly of the size and shape that I had originally made them. Some weeks afterwards, when the eyes had completely recovered, I tested the sight, and found that in the right eye, where the pupil was small and moveable, it was much more perfect than in the left, where the pupil extended as far as the ciliary margin. With the right he could read ordinary print, but he could not read at all with the left. This may be partly due to the condition of the cornea in the

a. *b.*

right eye; but I am inclined to attribute it in a great measure to the more central position, to the mobility and limited size of this pupil, and, above all, to the circumstance of its not extending to the extreme margin of the cornea, as the pupil did in the left eye.

I have performed the operation in several similar cases, sometimes trying how small a portion I could draw out and tie. On the last occasion, the piece that I drew out, when included in the ligature, was only about the size of a small pin's head, and the pupil was very slightly altered in shape (*c*). The sight in this case was very perfect. The condition of the artificial pupil is not, however, always a fair test of the operation. It may be everything that can be desired, both as regards size and position, and yet the sight may be very imperfect. This may arise from an altered state of the cornea, the result of the same inflammatory attack that produced the opacity, and by the perfect smoothness of its convex surface having been changed into a series of little flat surfaces, or the retina and other structures may have been compromised by the original inflammatory attack.

c.

The conditions most favourable for a good result are a *clearly defined dense opacity* in the centre of an otherwise transparent and healthy cornea. If a pupil, rather less than the normal size, and retaining its natural boundary and mobility, be brought opposite to the clear part of the cornea, very excellent sight is obtained.*

The second group of cases, in which "there has been a penetrating ulcer of the cornea, with some surrounding opacity, and the pupil is altered in shape, diminished in size, and drawn towards or behind the opacity," to which it is adherent at one point, presents great variety, both as regards the size and shape of the remaining pupil, the extent of the opacity, and the condition of the transparent part of the cornea; and upon these circumstances must, in a great

* See also Case, vol. i., p. 223.

measure, depend the degree of sight that is obtained; at the same time, I think it must be admitted that iriddesis is peculiarly well adapted for these cases, enabling us to regulate the size and position of the pupil so as to bring it opposite the best part of the cornea, and at the same time to make it, with certainty, small and moveable, and with a well-defined and permanent boundary. I have operated upon several of these cases in this manner with satisfactory results, and will briefly detail one that presented some circumstances of peculiar interest.

2. A gentleman came to consult me, from Australia, suffering from severe ophthalmia in both eyes of about two years duration; in one, vision was entirely and hopelessly destroyed; in the other, there had been a penetrating ulcer that had produced a dense opacity extending over nearly half the cornea, behind which the pupil, of an oval shape, adherent at one part, and diminished about one-third, was drawn (*d*). For some months the eye remained so inflamed and irritable, that nothing could be attempted for the improvement of the sight; at last, however, under the influence of a generous diet, change of climate, and soothing topical treatment, the eye regained a healthy condition, the opacity diminished in size, and became more clearly defined and circumscribed, and the pupil extended just to its margin, so that in a subdued light the patient could make out the outline of an object; and under the influence of atropine, a further slight improvement took place, but not to such an extent as to give any useful vision. Under these circumstances, I proceeded to enlarge the pupil downwards and inwards, so as to bring it opposite to the clear part of the cornea, rather less than its normal size, retaining its defined border and its contractility, and occupying a position midway between the corneal opacity and the margin of the transparent cornea (*e*). The operation was performed in the usual way; two days afterwards the bit of silk came

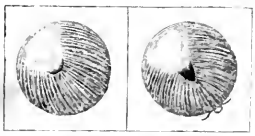

d. *e.*

away; every trace of the deligated portion of iris was gone, and in a few days the eye had regained its strength. Before this gentleman left England, he could not only see distant objects well, but could read writing and clear print; and I hear that, since his return to Australia, his sight has still further improved.

I think it will be conceded that every possible optical advantage was obtained in this case that the previous condition of the eye permitted, and that any other mode of operating, or any other form of pupil, would have produced less perfect results.*

The third group of cases are those in which the pupil is irregular, contracted, and opaque, or occupied by an opaque membrane. The object in such cases is to detach the pupil at one point from its adhesion to the opaque membrane, and then to enlarge it in one direction, so as to discover and expose a clear part of the lens and its capsule. This operation has been performed several times at the Royal London Ophthalmic Hospital, and on some occasions with very satisfactory results. It is more difficult to carry out successfully the various steps of the operation than in either of the other groups. One difficulty is the firmness of the adhesion, and another is the softness and rottenness of the previously diseased iris.

3. In a case that came under my care, I adopted the following method of proceeding. The patient was a female, between 40 and 50 years of age, who had formerly suffered from recurrent iritis, which had left a small, irregular, and adherent pupil, and some opacity of the capsule (*f*). The eye having been exposed, and fixed with speculum and forceps, and an opening having been made through the cornea, I first introduced Tyrrell's blunt hook, and getting it through the edge of the adherent iris, made gentle traction upon it, so as to detach it from its adhesion. This I succeeded

f. *g.*

* See also Case, vol. i., p. 224.

in doing. I then freed the hook from the iris, and drew it out. I then introduced my short cannula forceps, and seized the iris about midway between its pupillary and ciliary attachment, and drew it out, and tied it in the usual way. The effect of this method of proceeding was to form a small triangular pupil (*g*) by the side of the opaque part of the capsule, and opposite to a transparent portion of the capsule and lens. The sight was very much improved in this case.

This operation has been performed several times at the Royal London Ophthalmic Hospital, both by some of my colleagues, and by myself, and sometimes with a very satisfactory result; it is, however, only applicable to those cases in which the opacity of the capsule is limited to that part around which the contracted margin of the pupil is attached, and in which the rest, both of the capsule and of the lens, retains its transparency. It is scarcely possible, prior to the performance of the operation, to determine this point; but in the event of this further complication being revealed by the artificial pupil, it constitutes a good preliminary for further proceedings, and is in itself very safe. I find by referring to the Hospital records, that the operation of Iriddesis has been performed by my colleagues and myself sixty-six times during the past two years; and in a large majority of cases with very satisfactory results; I have also adopted it four times in private cases with good success.

It seems highly probable that the range of cases to which the operation is applicable, cannot yet be limited, and in proof of this I have much pleasure in adding a very interesting case furnished me by my friend Mr. Streatfeild, in which the operation has been applied by him in a novel and highly satisfactory manner.

"A farmer, aged about 50 years, came to me at the "Moorfields Hospital, on the 15th of September, 1859, he "had had cataract of one eye only, for which extraction had "been performed about a year previously, with subsequent "prolapse of the iris, through the corneal wound, by which

" not more than, if so much as, one-half of the natural cir-
" cumference of the pupil was left free *(h)*, and this was all
" above the axis of vision and partly
" hidden by the upper lid; never-
" theless he could, with it, dis-
" tinguish some objects, and by
" raising the upper lid and using
" a (2-biconvex) lens he could read
" small capital letters.



h. *i.*

" I performed iriddesis in the downward direction; it was
" difficult to seize the portion of iris to be tied, as it had lost
" the support of the lens, its fibres were much stretched, and
" therefore it receded before the forceps altogether. Having
" once failed to draw out, by the corneal opening, the portion
" held by the forceps, I succeeded the next time in securing
" it with the ligature of floss silk.

" On the 19th (the iris was adherent to the new corneal
" wound) I found the knot remaining in the cornea deeply,
" as if drawn into the wound by the tense iris fibres; it
" had not however passed through the cornea, and I readily
" removed it with forceps.

" The pupil now (*i*) acted perfectly; although before
" the operation, it had not seemed to act at all. The pupil
" was now in the axis of vision; but below it is a minute
" narrow vertical rent in the iris, probably made in the
" operation, when I, the first time, took hold of a portion of
" it; this however appears to be no great disadvantage, for
" the man voluntarily, without a lens, said he now could see
" better than he did.

" On the 26th the pupil remained as at the last date, and
" acted well; all that portion of iris not involved in the ill-
" result of the extraction operation *being now of about its*
" *natural width.* With a (2-biconvex) lens, he could
" already, without effort, read with the eye operated on,
" rather small type. The eye looks altogether as well as
" can be, and its external appearance is much improved by
" the operation on the pupil."

Mr. Streatfeild has since added to the above that he has had "a second case of similar displacement of the pupil "after 'extraction.' In this instance the cataract operation "had involved the iris to an amount as great as in the first "case, but the cornea retained a better form. The patient, "however, could not (with a lens) see capitals; but, by irid- "desis, he could tell the time by a watch, and (with a lens) "read the smallest type."

I have been anxious, in the present paper, to point out the easiest and best method of performing the operation, to indicate clearly the various classes of cases to which it is applicable, and to give the results and impressions which a more extended trial has given me. The only objection that I have been able to detect, is an occasional tendency to a drawing in of the loop through the wound into the anterior chamber. If the ends of the silk are left sufficiently long, this may be easily remedied by seizing a loose end and drawing it away three or four days after the operation; but the occurrence itself is exceptional, and may be obviated by making the opening in the cornea very small, and by inclosing the entire piece of prolapsed iris in the silk. The advantages of iriddesis I have already dwelt upon, and may briefly restate —it is applicable to nearly every variety of case in which an artificial pupil is required; it enables the operator to regulate with accuracy the exact size and position of the pupil he proposes to make; it ensures to it a defined boundary and the natural mobility (provided some portion of the pupil in its natural state existed prior to the performance of the operation); it secures stability to the artificial pupil, so that it will continue of the size and form it had when first made. After a little practice the operation is performed with great ease and certainty, and recovery is almost uniformly rapid and complete. I believe that it possesses important advantages over every method hitherto proposed, and that it enables the operator to ensure every optical advantage that the nature of the cases, and the previous condition of the eyes, permit; and I confidently anticipate its very general adoption.

ON CONICAL CORNEA AND ITS TREATMENT BY OPERATION.

By Mr. Bowman.

(*Received December 12th*—Ed.)

Conical cornea is a thinning and bulging of that structure in its middle region, coming on imperceptibly, and altering or destroying the natural focus of the eye. Up to this time its anatomical conditions have hardly been fully ascertained, and though many optical and operative correctives have been applied to improve vision, occasionally with some success, there is room for further efforts in the same direction.

I.—Its Anatomy.—The following is the only case in which I have had any opportunity of accurate examination. A young lady had had from infancy a slight prominence of one eye, and at 13 it had so increased as to excite alarm. A firm elastic tumor could be felt above the outer canthus, projecting the eye, which saw well. The tumor was punctured, fluid let out, and the eye receded, but in two years the eye had become once more prominent, and had now assumed the state known as conical cornea, remaining otherwise healthy. In three months more the tumor had thrust the globe more forwards, everting the upper lid, and almost destroying sight, apparently by pressing upon and stretching the optic nerve. The conicity of the cornea was very considerable, and as is usual in such cases was accompanied by opacity at the irregular apex of the cone. It was now necessary to remove, if possible, the whole disease. In company with Professor Syme I first excised the globe, then, partly through the space obtained, and partly by an incision below the brow, I succeeded in completely removing a very large sebaceous cyst, with bony plates in its wall, which was adherent to the very bottom of the orbit. The removal of a

V-shaped portion of the lid then corrected the ectropion. The recovery was most satisfactory, the young lady now wearing an artificial eye.

Mr. Hulke gave me the following account of an examination I requested him to make of the cornea.

NOTE ON THE PERFECTLY FRESH CORNEA.

The cone is a very prominent one, and is confined to the central region. The apex is nebulous, but elsewhere the cornea is quite transparent. Its surface is polished, and not facetted. The aqueous humor, iris, and lens are normal.

MICROSCOPIC EXAMINATION.

A section was carried through the line of the ora serrata, so as to remove the anterior ring of the sclerotic, with the ciliary processes, the iris and cornea entire; this portion was then pinned out flat on a piece of wood, with the iris downwards, and dried. Various sections were then made, and moistened with water or acetic acid.

The central conical nebulous portion was much thinner than the transparent periphery of the cornea, where the curve was natural. This thinning began at the base of the cone, and progressively increased towards the apex,

Fig. 1.

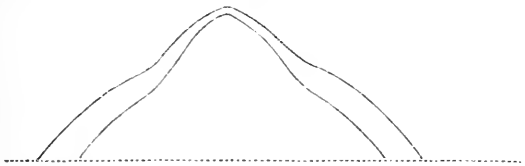

where it reached its maximum. (*Fig.* 1.) At this point the mean depth of several vertical sections was only one-third of that of the peripheral region. The continuity of the anterior elastic lamina was perfect, but upon the cone this structure was much thinner than elsewhere, and wrinkled; it was under

Fig. 2.

Fig. 3.

laid by a stratum of crowded, elongated, club-like nuclei, (*Fig.* 2,) and beneath these the normal lamellar tissue was replaced by a web of caudate and nuclear fibres (*Fig.* 3) amongst the meshes of which clusters of large oval

and fusiform cells were packed. The structure of the transparent peripheral region was perfectly normal (*Fig.* 4), and at the base of the cone there was a gradual transition from the healthy to the deceased tissue, the interlamellar corpuscles becoming more plentiful, branched and drawn out into fibres,

Fig. 4.

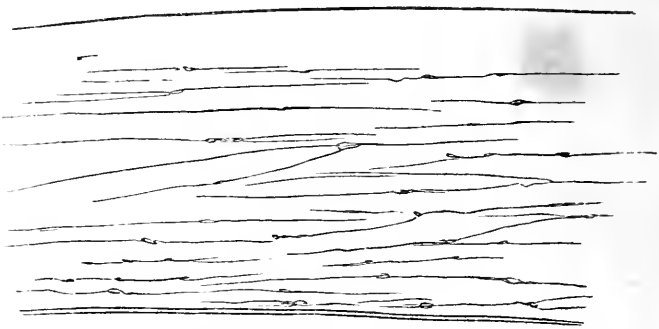

which in many instances coalesced with those from neighbouring corpuscles. (*Fig.* 5.) The posterior elastic lamina and the epithelium, both on the front and on the back of the cornea, were unchanged.

Fig. 5.



"The changes I have described," adds Mr. Hulke, "were confined to the laminated tissue of the cornea and the anterior elastic lamina. The substitution of a web of nuclear fibres and cells for the regular lamination of the cornea, explains the nebulosity of the cone, and the liability to bulge."

The above account is quite conformable with what might have been anticipated from such an examination, and sets at rest doubts which may have existed as to the condition of the bulging tissue. It may remain a question in what degree the cell growth in the opaque part may be regarded as a cause, and how far as an effect, of the stretching.

II.—Contribution to the general history of conical cornea drawn from my own observations. (1.) I have observed a very few cases in which it occurred in more than one member of the same family. The usual age at which it commences is from 15 to 25, but it may begin earlier, and as late as 50. (2) It is very often, but not always, attended by signs of delicacy of constitution, such as an hereditary tendency to phthisis, over rapid growth, a weak digestion, feeble circulation. (3) It very commonly occurs in both eyes, sometimes simultaneously and equally, more often unequally, so that vision is worse in one eye. I have seen several cases in which it has affected only one eye, but in these it has with very few exceptions remained slight. One man of 60 had an extreme degree of it in one eye, none in the other. (4) It may become stationary at any degree, from such a slight bulge as can be only detected by the ophthalmoscope up to an extreme irregular bulge, and opacity destroying the sight of all but the largest objects. (5) It never advances to bursting either by extreme stretching or by ulceration or sloughing. (6) It always proceeds gradually but with variable speed: when come to a stand it sometimes, though rarely, may take a fresh start. (7) When the tendency exists, it seems to be aggravated by whatever strains the eye; consequently over use and everything inducive of congestion is to be avoided; local fulness is to be combated by the usual remedies, while the general strength is to be upheld by all suitable means. (8) In many cases, especially those of a slight and slow progress, there is no mark of weakness or excitement in the circulation of the eye; in others the ciliary vessels are overcharged, often perhaps from imprudent efforts to use the organs when sight is failing. (9) Soon after the immortal invention of Helmholtz, I found the ophthalmoscope very useful in detecting slight degrees of conical cornea. For this purpose the concave mirror only is to be used without a convex lens. On turning the mirror so as to throw light at different angles, the side of the cone opposite to the light is darkened. Probably every one is

now familiar with this test. Professor Donders told me last year that he had himself observed it. It is a very useful one in discriminating the cause of slight defects of vision, somewhat resembling myopia and hitherto deemed anomalous. I have seen many such cases. (10) As to the physical state of the eye, I have observed that there is no undue tension of the globe appreciable by the touch; in some instances I have even thought the tension rather less than natural. In these examinations I have endeavoured to distinguish between the tension of the vitreous and aqueous regions of the eye, as I conceive it is desirable to do in reference to all the diseases in which the ocular tension comes under consideration. (11) The pupil is apt to be large, and sometimes the iris inclines to be tremulous.

III.—Rationale of the disease.—It seems certain that the bulging of the cornea is due not to an increase of the normal intraocular pressure, but to a diminution of the resistance of the cornea itself. In the natural condition, the cornea is sufficiently strong to maintain its true curvature under the ordinary tension; and even when this tension is augmented, and continues so for a long period, the cornea does not bulge, unless it has previously undergone visible change of structure, and rarely even then. The ciliary or posterior regions of the sclerotica bulge rather than the cornea. I conclude this softening of the cornea to occur only in the bulging part, and not near the margin. At first the softening is not attended with such alteration of the anatomical elements as to produce opacity; but as the bulging increases this alteration does take place, either as a further stage of the same process of softening, or as a consequence of the stretching of the softened part.

It has often seemed to me remarkable that the bulging never goes on to bursting. The reason, probably, is, that as the cornea becomes thinner, the escape of the aqueous humor by exosmose is facilitated, and thus the internal pressure is reduced so as to be no longer in excess of the

diminished resisting power of the cornea. A balance is re-established like that of health, only that there is a more than ordinary outflow of the aqueous humor by transudation through the cornea. This accords with my previous observation, as to such eyes being rather unduly soft. I do not pretend to explain why the cornea should thus occasionally tend to become less resisting and tough in its central region. Is it the consequence of some undefined change in the chemical constitution of the lamellated tissue? I can hardly venture to assign it with any plausibility to a primary alteration in either the anterior or posterior elastic lamina. Certainly the membrane of Descemet is not strong enough to bear any important part in the production of this disease; and as for the anterior membrane, I have many times extensively removed it with even some of the lamellated tissue without observing the slightest after-tendency to conical bulging of the cornea.

IV.—Treatment.—No reliable testimony exists as to the success of any measures hitherto adopted for the restoration of the cornea to its natural curvature, though, possibly, it would be wrong to say that that is not an object to be aimed at in slight and early stages.

Indications for the treatment by arrest.

These are two, to check the softening process, and to diminish the intra-ocular pressure. As to the former, in the imperfect state of our knowledge, we can only pursue measures of a tonic kind, which, indeed, are very commonly indicated by the general symptoms. When there are signs of congestion it is most important to meet them by the cold douche, by very moderate and cautious local abstraction of blood in certain cases, by abstinence from all that kind of use and exposure of the eyes which excites and reddens them, and from shedding tears.

My friend, Professor v. Graefe, has, within the last

three or four years, discovered the important fact that the excision of a portion of iris diminishes the intra-ocular pressure, a fact of pregnant interest in many diseases of the eye, and which he has applied with consummate skill to the treatment of glaucoma, of certain staphylomata, and last autumn to that of conical cornea. While agreeing that when this latter disease has attained a certain degree, and a certain age, all medical treatment is useless, he gives a case in which he practised iridectomy with the double object of favourably modifying the position of the pupil, and of lessening intra-ocular pressure, and he thinks with good results in both respects. (Archiv fur Ophthalm., vol. iv., part ii., p. 271.) The history of operations undertaken in cases of conical cornea is interesting; but up to this time none has come into general use. Mr. Wardrop repeatedly tapped the aqueous chamber. Sir Wm. Adams removed the lens by solution. Mr. Tyrrell drew the pupil outwards and downwards with the blunt hook, excising the prolapsed portion of the iris. If the iris then remained in the puncture, the pupil must have been balloon-shaped, and probably useful (see further on); but if it receded—an equal chance—the pupil would be a large irregular one, partly opposite the margin, and partly behind the central bulge of the cornea, and probably of little value. This operation has been the only one yet attended with any good result. Mr. Tyrrell himself tried it in several instances with advantage; in two with great improvement of sight. His great authority led surgeons to repeat his suggestion, but with variable and conflicting results, and I believe the proceeding has never come into common use with any surgeon. One eye was lost by destructive inflammation. In two the confusion of vision was aggravated. Mr. Walton has several times performed it without the slightest benefit. Mr. Wilde modified it by refraining from the excision of the prolapsed iris, and with marked advantage. Mr. Cooper and others had also variable, and, on the whole, unsatisfactory results. (See a good *resumé* in the American edition of Lawrence on the

Eye, by Dr. Hays, p. 393.) At present, I believe it may be safely said that operative proceedings in conical cornea have been generally abandoned as hazardous and uncertain. Some patients have been unwilling to submit to an operation when the surgeon could not promise a definite advantage, and the surgeon himself has often preferred the less formidable contrivances devised by the optician, which have been frequently found of great use. In fact, at Moorfields, I hardly remember that any operation for the relief of conical cornea had been practised of late years until it occurred to me in 1857 to attempt to modify the pupil by a new method.*

It has long been known that an eye thus affected often sees much better when either a small hole or a narrow slit in an opaque diaphragm is placed immediately before the eye. This is owing to the interception of all but a narrow pencil or plane of rays, which passing either laterally or centrally, form a more or less true image, unconfused by admixture with others less accurately converged, entering through neighbouring and more distorted portions of the corneal surface.

Such a contrivance has to be applied with a certain amount of skill, and to be moved as the eye itself moves, and it is seldom useful except for very near vision, because the area of the field is so contracted. To be useful, the aperture must be brought very near the cornea, and on the whole, though often far better than nothing, it is ill-adapted to poor and uninstructed persons. The idea on which I proceeded was so to operate on the iris as to give the pupil a slit-like shape, and to fasten it to the cornea in such a position as to conduce to the formation of the most correct image compatible with the altered curve of the cornea in each particular case.

* From 1824 to 1856, the records of Moorfields contain only two cases of operation for conical cornea, one of which was in 1825, and one in 1841. In November 1857, and January 1858, Mr. Critchett extracted the lens in the left and right eye of a patient, but without a definite improvement of vision, and iriddesis was subsequently performed in July and October.

It seemed likely that if the slit-like aperture could be placed within the eye, immediately behind the cornea, it would be more useful than the artificial perforated diaphragm placed outside. Without confining myself, however, to this idea, I have been endeavouring for the last two years to discover experimentally what modification of the pupil artificially produced was most effectual in improving vision. In no case have I had reason to regret having operated; no case has been made worse; all, with one exception, have been improved and none has caused anxiety by inflammatory threatenings consequent on the operation.

The first case* I shall relate is that of Sarah Collins, æt. 26, who for eight years had been delicate, and for six years had suffered from conical cornea, both being equally prominent and both transparent. With this exception, the eyes were quite natural, she could with an effort read the smallest type for a few moments if held very close, but had been compelled to abandon her employment on account of the impossibility of seeing the objects around her.

On April 30th, 1858, I operated on each eye in a different manner, but with the same object, viz., that of drawing the pupil outwards to a fixed point at the margin of the cornea, as the first step towards forming it into an horizontal slit. On the left eye I excised a minute marginal portion of the cornea by the help of a broad needle (*corneëctomy*—the operation of Guepin modified) a small portion of iris was immediately protruded and the pupil became transversely balloon-shaped, the margin of the pupil not being involved in the hernia. On the right eye I performed the operation of *tying the iris*, then just devised by my friend Mr. Critchett, to meet the want we had long felt of a sure method of fixing the iris to the point of puncture in cases of artificial pupil (*See* Ophthalmic Hospital Reports, vol. i, p. 225, October, 1858). In both eyes the canula-forceps was used to seize and draw out the iris to the degree desired, the point seized being about one-third from the pupillary margin, so

* A brief note of this case is given in the Ophthalmic Hospital Reports for July, 1858 (vol. i, p. 211).

as to leave that margin still free within the aqueous chamber. The object in each eye was attained, but with so much less irritation from the iriddesis that in all subsequent operations I had recourse to this method, which I regard as one of the most useful improvements made of late years in the operative surgery of the eye, giving as it does precision and certainty, with perfect security under all ordinary circumstances, to the operation for artificial pupil, in the very numerous cases to which it is applicable. The sight being now much improved, but most so in the right, I operated inwards, or at an exactly opposite point, in both eyes on the 21st of May, the immediate result being a transversely oval pupil in each. In the right eye the margin of the pupil was entirely free; in the left, the margin was adherent to the site of the corneal wound. Hardly any irritation ensued. At the end of two days the ligatures had dropped off; the pupils acted promptly, the left being more slit-like than the right. In both eyes vision was immediately much improved and a gradual further amendment has since gone on, apparently owing to a certain receding of the corneal bulge.

This girl has become able to resume her occupation of a housemaid, and is able even without concave glasses to see the objects in a room with tolerable accuracy; with a glass she can see distant objects still better.

I have operated since on six other patients, on five of them in both eyes. I have operated so as to make the pupil vertical rather than horizontal in all these cases, and in several have experimentally modified the operation in regard to the point of the iris seized by the canula forceps, and so as to test the value of that instrument, compared with the short blunt hook for seizing the pupillary edge. This last I now prefer, as being simpler and less apt to injure the iris, while it affords greater precision in fixing the pupillary edge to the wound. I find, too, no disadvantage in engaging the pupillary edge in the wound, the pupil acting as well afterwards as when the natural pupil is still entirely within the chamber. I have tried to perform iriddesis in the opposite directions on the same eye on the same occasion, but found

that the point first tied was apt to be drawn unduly into the chamber while the opposite point was being drawn out, so that I think it better to do the second iriddesis on the same eye a week after the first.

In one of the earlier operations with the canula forceps there was a little bleeding from the stretched iris into the chamber, sufficient to disguise the later steps of the operation, but with the short hook this has never occurred. These operations from their extreme delicacy should be done under chloroform, the influence of which should be sufficiently complete to place the organ in complete repose; one minute is sufficient for each eye when dexterously managed. If sickness ensue it does no harm to the eye. No iritis suffusing the pupil has followed in any case, but of course the usual care has been taken to keep the eye cool and quiet for a few days after the operation. If the thread remains on after three or four days, it may be pulled away with forceps. It is of great importance to the perfection of the operation that the puncturing instrument and the blunt hook should be of equal size, so that a sufficient opening, but not more than sufficient, is made for the free passage of the hook; otherwise, either the hook does not enter easily, or, on the other hand, the knot is prone to slip back into the puncture, or even into the aqueous chamber. The recurved part of the hook should be long enough to hold the pupillary margin, but so short as to admit of the ligature being tightened the moment this margin is outside the puncture. I always leave one end of the silk nearly an eighth of an inch long, so that it may be readily laid hold of afterwards, should it chance to have fallen at all inwards, or be concealed by a coating of lymph. These may seem trifling points, but in my opinion have their importance, and are not unworthy the attention of any one performing this operation for the first time—they pertain to the excessive delicacy of the structures, and of the whole proceeding.

It has been a matter of great interest with me to ascertain, as far as the limited number of cases presenting themselves enabled me, how far the second iriddesis was useful,

in other words, whether an elliptical or slit-like pupil gave better sight than one of a balloon-shape; and again, whether the vertical direction was better than the horizontal, or the reverse; also whether other modifications in the direction of the altered pupil were desirable.

Of course, this is is a subject which must be worked out in detail by surgeons, and the following remarks are but hints for future experimental enquiries.

The slit-like figure of the pupil suggested itself to me as the most feasible method of much limiting the size of the pupil while changing its situation. If the thing be well considered, it will be found difficult to conceive any plan of rendering the pupil *very small* by operation; it is much more easy to *enlarge* it. While the pupillary margin is free any displacement of the iris is most likely to enlarge the pupil, for I despaired of being able to seize the iris at one side of the pupil and draw and fix it over towards the other side. Any excision of the iris must, of course, enlarge the pupil, and so must any marginal iriddesis; but by a double iriddesis in opposite directions the central region becomes slit-like. By making this slit *horizontal* the light is admitted from each side, as well as through the centre, and the range of the field would probably be expanded, while the precision of the image would be impaired by the inequality of refraction through the central and marginal regions respectively. The appearance of the horizontal pupil was besides not agreeable. The *vertical* position of the slit offered the prospect of its virtual reduction in size, by the overlapping of its angles by the lids in ordinary vision; and I hoped that the patient would learn to use the lids for this purpose, so as to clarify the image. I cannot say that this expectation has been borne out in any marked degree, but nevertheless the vertical slit is much more sightly than the horizontal, and certainly equally good for vision, so that at present I prefer it.

The improvement of vision from a first iriddesis downwards has been in almost every case decided, the patients

being delighted with the result. In some the second iriddesis upwards has not seemed further to increase the precision of view, in others it has certainly done so, and in the present state of the enquiry I am disposed to continue to practise it in cases of considerable conicity. The improvement, however, consequent on the second operation, is never so marked as that which follows the first, and it can only operate by narrowing that part of the pupil which lies behind the bulge. Its more or less influence in different cases may perhaps depend on varieties in the curvature of the apex of the cone.

The influence of these operations in lessening the corneal bulge has been very remarkable. It is not easy to give in any case the exact amount of this result, but that the bulge diminishes speedily, and continues to do so for a considerable time subsequent to the operation, admits of no doubt, and I attribute it to the moderation of the ocular tension. Further experience will show whether I am right, but at present I am for operating quite early in slight cases in a downward direction only, if only to arrest the progress of the conicity; and certainly to obtain this result in almost any degree will make it worth while to perform so safe an operation in a disease otherwise so intractable, and, in its advance, so destructive of all useful sight.

It is interesting to observe the movements of the pupils after these operations. The following diagrams exhibit the states of dilatation and contraction in the case of horizontal slit, of vertical slit, and of the balloon-shaped pupil from iriddesis downwards; *a*, dilatation; *b*, contraction.

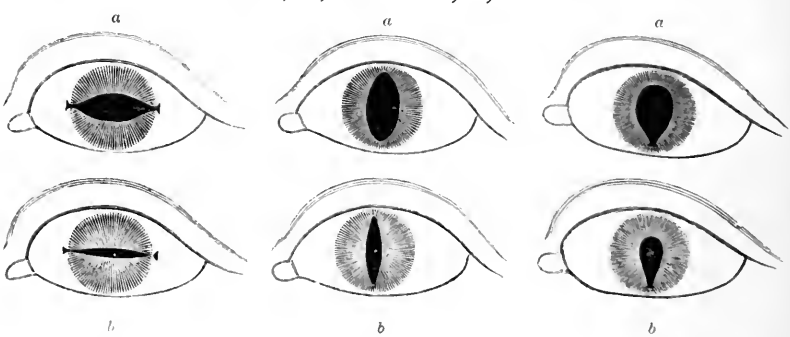

The following represents the stages of treatment in one of my cases recently in the hospital.

Lucy Milton, æt. 18, a fair, healthy girl, has suffered from conical corneæ for two years, and the defect increases. There is no opacity. She has been quite unable to keep in service. The left eye, having the worst sight, was the first operated upon by iriddesis downwards. This was on the 14th of October in the present year. The improvement was so great that the right had now become the worse eye, and accordingly it was in its turn subjected to the same process on the 26th. Before these operations the left could not count fingers at a greater distance than eight inches, and the right at a greater distance than four feet. After them both eyes could do the same at twelve feet. The second iriddesis was performed on the right eye on the 11th of November, and on the left eye on the 22nd. The girl herself was in each case positive in her assertion that vision was still further improved, though such tests as she could be put to, by the optometer or other wire, did not seem to bear this out in the case of the second iriddesis.

The amount of conicity before the operation, and a week after the last of them, is exhibited by the accompanying figure, where the cornea is shown in ideal section. The improvement has been little exaggerated by the draughtsman.

After the second iriddesis, the left eye accommodated for the optometer wires from 1 inch to 1 foot 9 inches; the right eye from 1 inch to 2 feet 1½ inches.

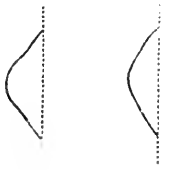

a Before operation.
b After operation.

In addition to the six patients operated on by myself, four others have been operated on by my colleagues, Messrs. Critchett and Poland, with satisfactory results as to the influence of this method. Two of these, however, were complicated with extraction of the lens. My friend, Mr. Lawson, has also had a satisfactory case.

REPORT

OF (78) *IRIDECTOMY* OPERATIONS (FOR GLAUCOMA) PERFORMED AT THE ROYAL LONDON OPHTHALMIC HOSPITAL FROM MAY 1857, TO SEPTEMBER 1859, INCLUSIVE.

By Dr. Bader, *Curator and Registrar.*

The first instance of glaucoma treated by excision of a portion of iris by Von Graefe's method, was, in a case of chronic glaucoma, operated upon May 1st, 1857; a second case was treated in the same manner in October in the same year. Both were cases of chronic glaucoma in an advanced stage, and their immediate result for vision was not such as would recommend the operation. Then came several cases of acute and subacute glaucoma, in which a striking improvement followed shortly after the operation. Since then iridectomy has been tried extensively at Moorfields, and with good and lasting results in many cases; so that if it were not for the comparative novelty of the treatment, it would not be required thus at length to report on so great a number of cases.

Some cases of cerebral amaurosis, and others of atrophy of the optic nerve, have been elsewhere treated by excision of a portion of the iris; and this application of iridectomy appears to have injured the character of the operation as applied to glaucoma.

For the particular diagnosis of chronic, subacute, and acute glaucoma, Von Graefe's papers,* and former "Reports" in this Journal may be referred to.

The prognosis of chronic glaucoma depends upon the stage in which the eye affected is operated upon; when *blind* for some time it is not expected to regain sight; and the operation is performed only to relieve pain and tension. A chronic glaucomatous eye, with mere perception of light,

* Now about to be published (translated) by the New Sydenham Society.

is *rarely* improved by the operation; but generally the pain and the progress towards blindness is arrested. An eye with subacute glaucoma, and still more one suffering under an acute glaucomatous attack, offers the best prospects of success for the operation, especially if the attack has occurred very recently, and if the turbid state of the media contributes much to the loss of vision.

In the whole number of cases, those in which no restoration of sight was expected as a result of the operation, will be noted; and others in which accidents during the operation have occurred, will be kept apart from those in which the regular course was followed throughout.

The technical part having repeatedly been described,* the accidents which have happened during the operation, and the difficulties which the operator meets with in the different groups of glaucoma, will only be given.

Six of the seventy-eight were cases of chronic glaucoma without perception of light; one of them had both eyes operated on, two the right, and three the left eye only. Fifty-three more cases of chronic and subacute glaucoma, with different degrees of impaired vision; of these, nineteen had both eyes operated on, sixteen the left, and eighteen the right eye only. Nineteen were cases of acute glaucoma, eight of which had both eyes operated on, five the left, and six the right eye only.

Before operating upon a glaucomatous eye, the state of its tissues and the high degree of intraocular pressure to which they are exposed must be recollected. The *conjunctiva* is thinner and tears easily, the *iris* is almost in opposition with the *cornea*; the *suspensory ligament* easily gives way and allows the *vitreous* to protrude; the vessels (*veins*) of the *choroid* and those of the *retina* are diseased, and very apt to burst.

In several of these cases of hemorrhage, in which the eye had been removed after the escape of the vitreous, it was found that the blood was extravasated from the large vessels of the choroid, had displaced the choroid and retina inwards, and pressed the other contents of the eye through the corneal section. (The occurrence of intra-ocular

* Ophthalmic Reports, vol. i, pp. 102, 93, 207, etc.

hemorrhage is less likely when the aqueous is allowed to drain away slowly.) In several glaucomatous blind eyes, which had been removed on account of the severe pain in them, circumscribed patches of hemorrhage were found also between the sclerotic and the choroid, near the equator of the eye.

A corneal incision has been practised in the first cases, which were operated upon, and recently in some cases of deep-set eyes, at its outer and lower margin; in other instances carried through its upper margin; but for a year past it has been made in the sclerotic 2 — 3 lines behind the upper corneal edge, either with a lance-shaped or with a cataract knife. The incision has been enlarged with scissors when the rotten state of the conjunctiva prevented the steadying the eye as is usually done with forceps, and when the globe has rolled inwards and so prevented the passage of the knife through the tough sclerotic tissue. The iris, when presenting in the section, has been seized with forceps, in some cases with the cannula forceps, and in others, in which *synechiæ* appeared to prevent its prolapse, it was withdrawn with an iris hook.

The drawing down the eye with forceps, for the purpose of fixing it, appeared, in several cases, to have caused rupture of the suspensory ligament and escape of the vitreous, etc. Great care has been taken when seizing the iris not to touch the lens or suspensory ligament, for the iris being atrophied and rotten, is easily perforated by an instrument.

The other accidents which may complicate the operation shall be reviewed with reference to—

1*st.*—*Chronic glaucomatous blind eyes.*

2*nd.*— *Chronic and subacute and acute glaucomatous eyes.*

1st.—Of the seven chronic glaucomatous blind eyes operated upon for the relief of pain and tension one only now requires mention. In this instance the lens capsule was touched, and hard portions of lens of a transparent yellowish appearance presented in the section; the eye was at once closed, and pressure with a piece of cotton-wool applied; no

further escape of the contents of the eye followed, and the wound healed well; though the patient had a severe attack of what appeared to be catarrhal ophthalmia, with pains for three days.

2nd.—Of the seventy-two eyes with chronic or subacute glaucoma operated on, with a view of restoring vision as well as of relieving pain and tension, bleeding from the iris into the anterior chamber occurred in twelve cases; the blood escaped in some cases from the ciliary attachment of the iris; in others, from near the pupillary edge, and in some it was seen oozing from the free surface of the iris. The bleeding came on either during the operation, or not unfrequently after the speculum had been removed. In one case it began a quarter of an hour after the operation; and in another the day following; in the latter case it was followed by suppuration of the globe. The blood as it oozes out should be removed at once, otherwise it may clot, assume the shape of the anterior chamber, and is difficult to remove. The end of the scoop is generally placed in the corneal wound, and pressure with some other instrument is made upon the cornea from below towards the wound; or simply pressure is made on the cornea with the scoop. It appears to be less safe to pass the scoop quite into the anterior chamber and thus to remove the blood. A counter puncture has been made in one case to allow the blood to escape. It takes, if allowed to remain, from three to nine days to become absorbed. The subacute form of glaucoma appears to be most liable to bleeding after the operation.

The lens in seven cases became opaque, without any fragments escaping, most of these cases had been operated upon with the lance-shaped knife.

Hard portions of transparent lens, where its capsule had been wounded, escaped in three cases; the remainder of the lens became opaque in two of them: pressure to avoid further escape of lens or vitreous was applied. In the third case the remaining fragments of the lens appear to have escaped *some time after* the operation, a clear pupil with improved vision being found the third day after it. There had been much pain in the eye for some time.

In one case the lens in its capsule, presented in the section, and six hours after the operation, was found with about a third of the vitreous humor (of abnormal consistence) at the side of the patient; the pain, which had been severe, subsided after this had happened. Some lenticular fragments escaped also in another case in which the lens had not been touched; some vitreous followed while removing the remainder of the lens with the scoop, but the application of pressure stopped any further escape that might have happened, and no pain followed.

The opaque lens of several of the above cases was extracted with a favourable result.

The section was, in some of the first cases operated upon, kept open by portions of iris which were left there, to allow the fluid which might accumulate in the anterior chamber during the first days after the operations, to drain off.

A gaping of the section, with accidents similar to those accompanying an irritable prolapse of the iris after extraction, was in two cases caused by fluid vitreous, which distended the wound. It was gradually coated over with lymph and flattened down; the lens remained transparent in both cases.

One case presented all the fatal accidents of the operation—first some difficulty in seizing the iris, then escape of some vitreous, then of the lens, then of a large portion of vitreous with the hyaloid fossa attached to it, then of the remainder of the vitreous, followed by about half an ounce of blood. Slight pressure was applied; no pain followed.

Twenty-seven eyes attacked by acute glaucoma were operated upon. Three of them were followed by bleeding from the iris, which appeared to stop after the small iris vessels were emptied. In one case the lens was wounded, it escaped with some of the vitreous, and a troublesome *iritis* with lymph formation followed.

Sixteen out of a hundred and seven eyes may be said to have been injured by the operation; that is to say, so many patients who would have lost vision if no operation had been

done, went through a certain amount of pain and anxiety with a chance of having sight restored.

Anticipating the analysis of the cases successfully operated upon, it may be said that in about eighty cases the operation has had a good, and, so far, a lasting result.

A second portion of iris was excised in two cases, and the distended section (new increase of intra-ocular pressure) was punctured in two others.

The cases which failed through the operation will be kept apart from the rest, when giving the results of the operation for vision, for relief of pain, etc.

(*to be continued*)

PLATE VIII.

A, 1. *Edema* of the *Retina.*

A, 2. The other eye of the same case (XXIV.) p. 16.

B. *Anemia* of the Optic Nerve and of the *Retina.*—See case (XXII.) p. 14.

C, 1. *Fundus* (of a deep-brown eye) with Night blindness.

C, 2. The other eye of the same case (XXIII.) p. 15.

This leaf is printed on paper of this colour for the reason given in the foot-note at page 117.—Ed.

PLATE IX.

This Plate illustrates the case of *Phthiriasis palpebrarum* (Case XXIX.) at page 125.

Fig. 1. The appearance of the eggs adherent to (and separating) the hairs of the upper lid only. The insects are hidden among the roots of the lashes.

Fig. 2. The *Phthirius inguinalis,* (× 80.) from the specimen best distinguished (mounted in Glycerine).

Fig. 3. Part of the same specimen (× 200.) showing two branches of the respiratory tubes and four of their external openings. At the extremity of the leg appears to be a muscle to flex the large terminal claw.

Fig. 4. An *Ovum* (× 80.) unmounted. Lumps of dirt (?) are adherent to many of the hairs.

Fig. 5. An egg (containing a fetal louse) and an egg shell (with lid detached and puckered internal membrane) mounted in Glycerine (× 130).

The necks of the eggs of the much-developed young, or of the empty egg-shells, seemed to be much widened, but not otherwise enlarged. Another of the young (in the egg) which I saw, was much more developed than that above represented (its claws, etc. were visible) but it was damaged.

J. F. Streatfeild.

Plate IX.

Fig 1.

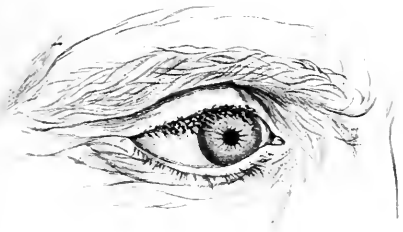

Fig 2

Fig 3

Fig 4.

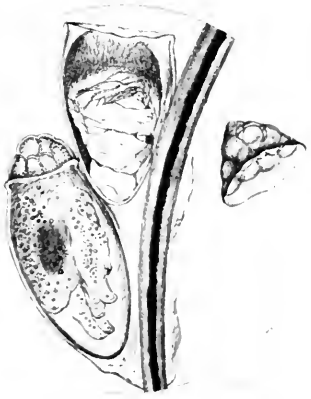

J.F.Streatfeild del. Turfen Wo

OPHTHALMIC HOSPITAL REPORTS,

AND JOURNAL OF THE

ROYAL LONDON OPHTHALMIC HOSPITAL.

No. X.

January, 1860.

The following remarks on Case XXXI have been addressed by Dr. Mackenzie to Mr. Hutchinson since it has been published (page 130) :—

DR. MACKENZIE ON "SO-CALLED DIPHTHERITIC OPHTHALMIA."

"I have read with interest your case of destructive inflammation of the eyes, consequent to *scarlatina*, in the last number of the Ophthalmic Hospital Reports; and only regret your using the name 'Diphtheritic Ophthalmia.'

"That the exudation on the surface of the eyeball and eyelids, in such cases, is of a nature similar to what occurs on the tonsils, *velum, pharynx*, and *larynx* in *diphtheria*, is no doubt true; but as in the cases where this pellicular formation occurs externally, there are constantly much more serious changes going on in the deep-seated textures of the eye, and as this external formation is not constantly present in the cases in question, the fixing on this symptom as affording the distinctive character of a *genus* or *species*, is, I conceive, an error in classification, and is likely to lead to the inert treatment of a very formidable disease; viz., *Ophthalmitis*— by some called *Panophthalmitis*, and by others *Endophthalmitis*.

"The cases of *ophthalmitis* to which I refer are of different kinds — idiopathic, traumatic, and phlebitic; they follow measles, small-pox, *scarlatina*, and *typhus*, being in these last instances, in all likelihood, pyæmic, or dependent on purulent infection of the blood. In all of them, exudations of inflammatory lymph, degenerating into pus, take

place within the eye, having been found, on dissection, in contact with the choroid and the *retina,* within the vitreous humour, and in the aqueous chambers. Along with these changes there are hardness and protrusion of the eyeball, white *chemosis* of the *conjunctiva,* eversion of the eyelids, and, occasionally, but not constantly, the formation of an external lymphatic pellicle, which can be torn off in shreds and layers, leaving the denuded surface raw and oozing out blood.

"If, then, the diphtheritic exudation is only one of the symptoms of the disease in question—if it is the least weighty of them all—and if it does not constantly, but only occasionally, occur—it ought not to be adopted as the ground on which to establish a new nosological distinction. Were it so adopted, the attention of practitioners might be drawn away from the destructive—often, indeed, fatal—nature of the disease on which it is an occasional attendant; so that instead of using active and appropriate means of cure, they might busy themselves with stripping off the conjunctival pellicle, or touching the eye with a solution of lunar caustic, appliances which, in such circumstances, must prove of no avail."

VOLUNTARY POWER OF USING THE *TENSOR TARSI* AND OF CAUSING *ENTROPION* OF THE LOWER LIDS.

Since Dr. Jago's communication was published in the last number of the Journal, Mr. C. Gayleard, a surgeon, about twenty-four years of age, came to me to let me see the extraordinary muscular power he has in the lower lids. He has also kindly approved of these notes as they are now given.

In either lower lid he can, at will, contract powerfully the *Tensor Tarsi,* and independently, or at the same time, so exert the *Orbicularis Palpebrarum* as instantly to invert, and keep inverted, either or both lower lids.

Description. — 1. *Tensor Tarsi, its action* (*cf. Case XXVIII.*)

This act, in this case, seems to be limited to the lower of the two divisions by which this muscle is inserted, as it is usually described. He draws the lower lid somewhat up and strongly inwards over the caruncle (the lower being approxi-

mated to, and then carried inwards beyond, the upper *punctum*); but he does not, and cannot, move at all the upper lid. The action is most decided on the right side—it is, in either, immediate. Taking the *punctum* as a mark, the extent to which the position of the lid is changed is nearly two lines. The skin of the lid over the muscle is raised by the action. The inner angle of the lower lid can be retained over the caruncle for a quarter or almost half a minute; whilst thus in continuous action the eye must be kept in any one position, for if moved the *tensor* relaxes at once. There is no movement of the *orbicularis, corrugator,* or other muscles with the *tensor*. The closure of the eyelids does not prevent the peculiar movement.

2. *Orbicularis Palpebrarum, its* (*peculiar*) *action* (*cf. Case XXXIV.*)

By this Mr. G. produces *entropion* immediately at will; before he does so the skin is brought as much as possible to the orbit, by use of the entire *sphincter,* the zygomatic and other muscles, the angle or angles of the mouth being drawn out and upwards, as in grinning, and the brow down, as in frowning, before the lid is inverted, then it is done instantly, the left lower lid being always the first turned in, and the most powerfully. He cannot invert the lower lid easily without quite closing the lids. The eye must be turned out, and a little downwards, for the inversion to take place. The ciliary portion (*ciliaris,* Quain) of the *orbicularis* seems to twitch once when he inverts the lid, but the whole circumference of the muscle is, especially at its outer part, seen to be steadily contracted. It is done suddenly and forcibly. The lashes are black and numerous—their ends are just to be seen when the lid is turned in. The skin is not at all lax or thin. He says it requires a constant slight effort to keep the lid inverted; it causes slight pain, so that he cannot continue it for more than three or four minutes together. The sensation of the inverted lashes is, for the time only, rather irritating; it causes no redness of the *conjunctiva,* but very much lacrymation, and therefore, after three or four times, he, although never tired, cannot repeat the trick, to keep the lid inverted, without each time wiping away the tears from the skin of the lid. He can keep both lower lids together inverted, or one or the other, but he never could invert either of the upper lids. He can bring together the

lids when the lower one is inverted; he can also open them widely, and look in any direction but upwards, without remedying the *entropion*.

Early History.

These two unusual movements of the lower lids are of spontaneous origin, and have been possible to him since childhood, 'as long as he can recollect.' At this time he never had any illness. No parent or relative of his had any such extraordinary powers, nor had he known any person whom he could have imitated. As a boy he had, he believes, greater powers than he now has. He used, when the lid was turned in, to rub the inverted lashes against the ocular *conjunctiva* with the finger, and boasted he could cry at will —a rapid flow of tears, as above mentioned, following the voluntary *entropion*. He is myopic, and at one time he used an eye-glass, which he could keep in its place with peculiar facility.

General Comparison with Cases XXVIII and XXXIV.

Mr. G. has the two different peculiarities of these cases. He has less power than Dr. Jago over the *tensor*, and as he cannot move at all the upper lid, the caruncle is never quite covered. In Mr. G. there are not any folds produced at the inner angle of the palpebral aperture, perhaps because the upper is not moved with the lower lid. He has more of the peculiar power than Mr. Taylor over the *orbicularis*, and the eye must be turned in the same direction to produce the *entropion*. It is singular that Mr. G., although he can, by pressing the skin upwards with a finger, readily cause the *entropion*, cannot keep the lid of itself inverted, unless it has been brought about by the muscle of the lid.

Comparison of the Powers of the two Muscles.

If, as it has been said, the *tensor* brings the *puncta* into the best position for receiving the tears, it signifies, I suppose, that it, in some degree, turns inwards the inner part of the lids—and, if it were so, its excessive action might, in the present case, be the cause of the voluntary *entropion*,* but the *puncta* certainly are *not* turned inwards when the *tensor* is put in action. Mr. G. can, at will, produce, in either eye,

* The *tensor* has been proposed as a cause of *entropion* by some authors.

a *partial entropion*, such as Mr. Taylor can on the left side; this is done by looking very much down and outwards, and then a fold of skin, the margin of the lid and the lashes are brought up to the cornea with little separate movements, but these also being at the outer and not at all at the inner part of the lower lid, seemed to be of the *orbicularis* and not of the *tensor*. I believe the action of the *tensor* is quite distinct from that of the *orbicularis*. Dr. Jago, with so much power over the former muscle, cannot produce *entropion*. Dr. Horner,* indeed, says it is probable that the "small muscle" is, in some ways (acting on the *sac*) opposed to the *orbicularis*. Again, speaking of the *tensor* being distinguished from the *orbicularis*, he says (having remarked its very distinct origin):—"The superior fork, however, of the muscle has a few of its fibres blended with the *ciliaris*." Here I will remark that the *superior* division of the *tensor* is in Dr. Jago much the weakest, and that Mr. G., who has at the same time so much power over the *ciliaris*, has no control over this division at all, which also goes to prove the individuality of the "small muscle." I have repeatedly seen patients (*not* cases of *entropion*, that I can recollect), in whom the *tensor* could be seen in action involuntarily whilst the *orbicularis* was quiet. Mr. G. can distinctly contract the *tensor* at the time when the *orbicularis* is keeping the lid inverted.

1. *Remarks on the present Case.*—2. *Use of the Tensor Tarsi.*—3. *The Voluntary Powers are cherished, and why.*

Both peculiarities are, as he believes, congenital. The upper lids, which cover so much more of the convexity of the globe, cannot be inverted. As it is necessary to turn either eye down and outwards to produce the *entropion*, one lid is always inverted an instant before the other. The unusual power over both muscles is confined to the lower lids. He is left-handed—the voluntary *entropion* is most active on this side, but the *tensor* is most powerfully influenced by the will on the right side. For the *left* eye he used to wear the eye-glass. The *tendo* in Mr. Taylor is, on either side, very large, hard, and prominent, but in Mr. G. it is not even distinguishable. He cannot move the ears, but, with the *platysma*, he has an extraordinary power over

* "Description of a small muscle," etc. Philadelphia, 1824.

the skin of the neck. He can, as others can, contract the pupils very decidedly, and at once; this, he says, he does by some muscular exertion, and that he then sees any object he is looking at very indistinctly. He continues to look in the same direction, and possibly it is done by an increase of attention given to the object, or by looking particularly at some nearer object in the same direction.

2. Horner says, in his pamphlet (where he mentions "two cases" in which, at will, the muscle "draws the eyelids towards the nose, and buries the *puncta* and the internal commissure under the fold of skin which is formed at the same time on the internal *canthus* of the orbit,") that his muscle is, *in all conditions*, to keep the *puncta* applied to the surface of the eye, and to assist in conducting the tears from it to the nose. I doubt if the latter is true in any active sense. I asked Mr. G. to try the following experiment:—To create the lacrymation by inverting the lids, and then to use the right (most active) *tensor* repeatedly, that I might observe if, on that side, the accumulated tears were more rapidly removed. He inverted both lower lids, and rolled the eyes, looking downwards, from side to side. Both eyes were then overflowing with tears, which I wiped away until an equal quantity appeared to remain in each. He then, for about a minute and a half, exerted the one *tensor* (about sixty times) equally, and then no tears remained *in either eye*. This he did again, and the eyes were, at the same time, equally dry, the left eye not less quickly than the right. The outer palpebral commissure does not seem to be affected by the *tensor*, which, when in action, appears to press the lower lid upon the globe—the *punctum* and the lid being *neither in nor everted* by its action. During some time, when I took these notes, I could not say that I saw the muscle act involuntarily, but Mr. G. believes that its use to him is, in a lesser degree, one of those especially belonging to the *orbicularis*,—that it clears the eye occasionally by a slight nictation, which can thus be done without closing the lids. I believe the *tensor* is intended, *in all circumstances of health*, to keep the lids duly in apposition with the globe and only passively to assist the passage of the tears.

3. Mr. G. still uses the power he has of inverting the lower lids, from time to time. I, of course, advised that he should learn not to do so, lest, at any time when he should become thinner than he is now, or from any other cause, he should get permanent *entropion*. This is, perhaps, less to be feared

than it is by Mr. Taylor, who has not the correcting power, as it may be called, of also using the *tensor* voluntarily. It does not seem that Mr. G. inverts the lower lid now merely by persistence in an early-discovered and practised trick; but, as it has been said, that the *tensor* exerted voluntarily acts for him as winking the eye involuntarily does for others, so he believes that the *entropion*, complete or partial, as I have above mentioned, does for him, by this muscle, the *orbicularis*, at will, that which rubbing the eye does for those who have only ordinary means of clarifying their vision.

J. F. Streatfeild.

PUBLISHED CASES.

Case XXXII.—Amaurosis from Fatty Degeneration of the Retina, originating in Bright's Disease.

By Dr. Mackenzie (*of Glasgow*).

T. M., æt. 25, consulted me 3rd January, 1860, on account of dimness of sight of both eyes, chiefly of the left, with which he could not see to read at all, and with the right only capital letters. His eyes had a normal appearance externally; the pupils were not dilated, and they responded tolerably to the light. Struck by the pallid and somewhat puffy appearance of his face, I suspected that he might be affected with Bright's disease of the kidneys, and inquired if he had ever had swelling of his feet. He answered, that he had had that symptom, about eighteen months before; that it had been removed at that time by pills containing mercury, which acted as a diuretic; but that it still occasionally occurred. He stated, that about two weeks before calling on me, he had been affected with headach, followed by vomiting, to which was added the deterioration of sight. The earliest visual symptom experienced was photopsia; but this had subsided.

Previously to the occurrence of his complaints, his occupation as a clerk in a quarry, had exposed him much to cold and wet.

On his first visit to me, applying a drop of a solution of sulphate of atropia, so as to dilate the pupils, I found, on

examination with the ophthalmoscope, the humours perfectly clear, both optic disks of a pale red colour, and their outline by this change of colour rendered indistinct; while the retinæ around, but not quite close to the disks, were studded over with numerous, small, circumscribed, opaque-white spots, of irregular figure. I concluded these spots to be of the nature of fatty degeneration, as they answered, in general, the description given of this lesion of the retina, by Heymann,* Virchow,† Wagner,‡ Liebriech,§ and others.

The spots in question did not exist more on the temporal side of the optic disks than on the nasal. On careful examination, in the indirect method, by means of a convex lens of two inches' focus, held in front of the patient's eye, I observed in the centre of several of the white depositions in the right retina, a minute dark-reddish or blackish point, which I concluded to be remains of extravasated blood; and I particularly observed that the white depositions lay in the interstices, and several of them plainly in front of the retinal vessels, and not behind them. They occupied only a zonular space, at some distance around the optic disks. none of them being close to the disks, nor any of them extending as far forward as the vertical equator of the eyeball. The vessels on the surface of the disks, especially the small ones near their edge, were much more numerous than usual; those distributed through the retina did not seem enlarged. The choroid appeared normal.

The patient continued under my care till the 26th January. During this time, I gathered from him, that although his urine was not abundant, he was generally called to pass it three or four times during the night. On the application of heat and nitric acid, it showed itself, on the 4th January, only moderately albuminous; but on the 12th, it was strongly coagulable. From 1000 grains of it 6 grains of urea were obtained. Its specific gravity, taken on the 17th, was 1·007. On examination with the microscope, a few fibrinous casts were detected in the urine. The serum discharged from a blister on the left temple yielded a distinct trace of urea.

The patient informed me that he had perspired almost

* Archiv für Ophthalmologie, Band ii, Abth. 2, S. 137, Berlin 1855.

† Archiv für Pathologische Anatomie und Physiologie, Band x. S. 170, Berlin 1856.

‡ Ib. Band xii, S. 218, Berlin 1857.

§ Archiv für Ophthalmologie, Band v, Abth. 2, S. 265, Berlin 1859.

none from the commencement of his complaints. He had, also, from about the time when his feet had become œdematous, suffered from palpitation of the heart and dyspnœa; these symptoms being much increased on exertion, such as in going up stairs. I found the impulse of the heart very strong and greatly diffused, being felt as much opposite the 7th and 8th ribs as opposite the 5th and 6th, if not rather more. The heart was evidently dilated and hypertrophied, especially the left side; but I did not detect any distinct change in the sounds of the heart, indicative of valvular disease. The pulse was generally quick.

The œdema came and went slightly. The thirst became intense. The tongue was reddish and raw. The patient was troubled with frequent watery vomiting, and rejection of food from the stomach. He had also purging, with tenesmus.

Before he left Glasgow, the optic disks appeared redder, and their outline still less distinct. There also appeared, unless I deceived myself, some new points of extravasated blood in the retinæ. Notwithstanding this, his sight, he thought, improved; and he could read somewhat better, especially with convex glasses of about 25 inches' focus. This he was able to do, no doubt from the vertices of the retinæ remaining in a great measure free from the fatty depositions.

The treatment followed consisted in blisters behind the ears, and afterwards to the temples; the warm bath, every second or third day; a pill, thrice a-day, consisting of two grains of sulphate of iron with as much extract of gentian; when the œdema returned, powders containing squills and nitrate of potash, in place of the pills; and small doses of laudanum, to check the diarrhœa.

On the 26th, the patient expressed a desire to return home, a distance of 77½ miles. He did so by railway on the 27th, which proved an extremely cold, frosty day. He arrived in the forenoon, and was seen shortly afterwards by Dr. Chalmers, of Thornhill, Dumfriesshire, who had formerly attended him, and to whom I am indebted for the following particulars:—

He was in a drowsy, listless condition, and answered questions only after being roused, and with hesitation. He was weak, exhausted, and cold. His pulse 120, and very weak. He said that he had made no urine since the evening of the 26th. Dr. Chalmers ascertained that there was none

in the bladder. Hot drinks were ordered internally, and hot applications externally; with a dose of castor oil; and the hair to be cut off all over the head. Being sent for to see him between 10 and 11 P.M., Dr. Chalmers found him in convulsions, and unconscious during and after the paroxysms, with pupils dilated and fixed. Surface warm; pulse small, indistinct, and very frequent; no flushing of face, nor suffusion of eyes. He gave him two drops of croton oil, and not being able to remain with him, left some more, to be given in three hours, if the first should not have taken effect, with instructions generally about the case. On his return home next morning, and when on his way to see him, he learned that he had died at 8 A.M.; the convulsions continuing up to the last, only less frequent towards the end.

No inspection of the body was obtained.

Such is an example of a species of amaurosis, which has of late years attracted much attention, namely, that which depends on granular degeneration, or Bright's disease, of the kidneys. Amaurosis may arise during any of the three stages of this disease; the hyperæmic, that of exudation and granular degeneration, or the atrophic. It has been observed chiefly in coincidence with the second stage.

Two remarkable changes of the blood occur in Bright's disease; *viz.*, a diminution of its solid contents, especially of its albumen and red corpuscles, and the presence in it of urea. The albumen of the blood is transferred in this disease to the urine, and with it is discharged from the body; while the urea, which should pass off in the urine, is transferred to the blood. The consequence is, that an impoverished and at the same time poisoned fluid is circulated through the body, incapable of maintaining healthy nutrition, and which acts as an irritating poison, on both the nervous and the vascular system. No part of the body, in fact, escapes the influence of the circulating fluid, so altered in composition; but the heart, the brain, and the organs of vision seem peculiarly liable to suffer from it. Hence it is, that during life, as well as in the dead body, morbid changes, in almost every other organ, are so often found associated with the various forms of granular degeneration of the kidneys.

So far as the eyes are concerned, the vessels of the retina are first of all congested, which leads to minute extravasations. These become the foci of spots of induration, in the interstitial substance of the retina, and chiefly in the gray nervous

layer, where the capillaries are situated. These spots of induration gradually undergo the fatty degeneration. The appearances are sometimes such as occurred in the case above-related, the depositions being in front of the vessels; but more frequently the vessels have been seen coursing over the depositions. The retina has also been found much more extensively affected, showing broad patches, or even an uninterrupted elevated zone round the optic disk. The degree of degeneration present regulates the deterioration of sight, from dimness up to total insensibility to light.

As happened in the case above related, *coma* and convulsions, from suppression of urine, generally end the scene.

Case XXXIII.—Persistence of some Remains of the Pupillary Membrane, in a Girl of Sixteen.

By Mr. Wharton Jones.

The subject of this case presented herself at University College Eye Infirmary, complaining of some degree of dimness of sight with pain in the right eye. She was healthy looking, but her menstruation was irregular.

No complaint was made of the left eye. After examining the right eye (which was only a little congested), I proceeded, as usual, to the examination of the left, and was surprised to see, what appeared thin bands of adhesion between the iris and capsule of the lens, notwithstanding that the iris did not present the slightest trace of having ever been inflamed. Continuing the examination, aided by a magnifying glass, I observed that the bands did not spring from the pupillary margin of the iris, nor from behind it, but from the anterior surface of the iris, where the pupillary joins the ciliary ring, and that they had the appearance of prolongations from the substance of the iris itself. The ends of the bands were adherent to the capsule of the lens, a little above the centre of the pupil.

The pupil dilated and contracted, in obedience to the light, quite naturally. In connexion with the movements of the pupil, I noticed that during dilation, the bands were stretched, but that when the pupil contracted, they became

relaxed and fell into a curve. This was especially remarkable in the case of the largest band.

The figure represents the appearance described, as seen by the aid of a magnifying glass.

What was the nature of these bands? It is quite evident that they were not bands of lymph, the product of any preceding iritis. Taking into consideration their connexion with the iris, at the place where the pupillary joins the ciliary ring, and remembering that that is the place where the pupillary membrane is connected with the iris, we can scarcely have any hesitation in viewing the bands as vestiges of the pupillary membrane—vestiges of those parts of it, into which the vessels of the nascent iris shoot to anastomose with the original vessels of the membrane.*

The adhesion of the ends of the bands to the capsule of the lens, may be viewed as the result of inflammation of the pupillary membrane, when it existed entire during fœtal life. The persistence of the vestiges of the membrane in the form, as we conceive, of the bands themselves, indeed, may also be viewed as in some manner owing to the same cause.

Case XXXIV.—Voluntary Power of using the Orbicularis Palpebrarum, so as to invert the lower lid.

By Mr. Robert Taylor.

(*To the Editor of the Ophthalmic Hospital Reports.*)

Sir,—I have verified the following notes of my power of inverting the lower lids; and, as you request, I beg you will make use of them.

I have possessed the power as long as I can remember. As a child, I was in the habit of amusing myself thus, and could produce complete inversion of both lower lids, simultaneously or separately, with great rapidity. So far as I know, none of my relatives had this power. My father had rather more than usual command over the muscles of the scalp, and could move his ears upwards. I can move my ears backwards, either alternately or together.

* See my Anatomical Introduction, explanatory of a horizontal section of the human eyeball, in Mackenzie's Practical Treatise of the Diseases of the Eye. Fourth edition, pages xxix and xxx, London, 1854.

For many years I have avoided inverting the lids, except occasionally for the purpose of illustration, as I feared that permanent entropium might result; and I now find that I have nearly lost the power on the left side. Having made a few trials since you asked for these notes, I find that I can tilt the edge of the lid so as to bring the lashes in contact with the ocular conjunctiva, but cannot produce complete inversion. I believe that I could readily regain the power by a little practice. On the right side, as I have always used this eye in demonstrating the action of the muscle, I can produce complete inversion with tolerable facility. In doing so, the whole of the orbicularis is called into action, so that the eye is nearly closed, but the will is directed especially to the ciliary portion of the muscle, and the effect is more readily produced by gently opening and closing the lids several times, the eye at the same time looking outwards. The inversion takes place with a sudden snap, the cartilage turning over so that its inner surface is directed outwards, and the skin and eyelashes are in contact with the ocular conjunctiva. In this position it remains without any muscular exertion, but on the eye being turned upwards, it resumes its proper position with a jerk. It does not require much muscular exertion to produce the inversion, and I have never felt the muscle fatigued after frequent use. While the lid is inverted, I can with great ease bring it into apposition with the upper lid, or can open both widely, as in staring. The eye, also, can be turned in any direction, except upwards, without replacing the inverted lid. I can produce entropium in either eye without the action of the orbicularis, by tilting over the cartilage by gentle pressure with the finger. The lashes produce very little irritation when in contact with the conjunctiva, but they are rather soft and weak.

At the Central London Ophthalmic Hospital, we have for many years performed the operation devised by my colleague, Mr. Haynes Walton, in cases of entropium, which consists in removing the ciliary portion of the orbicularis muscle. So far as I recollect, the operation has been uniformly successful. I have more than once removed the muscle without excising any of the skin, and the only objection to this mode of operating is, that it requires a little dissection, and is thus rather more tedious.

I remain, Sir, Yours, etc.

FOREIGN BODIES IN THE EYEBALL.

By Mr. White Cooper.

(*Received Nov. 30th.*—Ed.)

The following cases present points of interest, and their publication may be of some practical use:—

Case I.—Chip of wood imbedded in the eye three months.

On May 27th, 1859, I was sent for into Norfolk to see a young gentleman, under the following circumstances. Eight days previously whilst endeavouring to break a stick, it suddenly gave way, and the sharp jagged end of the portion held in his right hand was violently jerked up into his right eye; at first the injury was considered slight, and two days elapsed before medical advice was sought. The severity of the accident becoming evident, I was summoned on the above day; he had been placed under the influence of mercury and strict antiphlogistic treatment pursued.

The eye presented a lacerated wound at the lower and outer margin of the cornea, through which there was slight protrusion of the iris; the lens was opaque, and the distorted pupil adherent to it. The iris was discoloured, and there was general, though by no means intense, injection of the sclerotic and conjunctiva. I made a careful examination, but could discover no trace of a foreign body in the eyeball. The patient complained little, his pulse was 60, and as he was of a strumous habit it was not thought advisable to push antiphlogistic treatment further. A continuance of mild mercurials with quinine was recommended; and topically, cold water dressings, with belladonna to the brow.

Under this treatment the inflammation gradually subsided, but it was reported to me in August, that the cornea had become prominent, with a dark spot in the centre. To

satisfy myself as to the nature of this, I requested the patient to come to town, and he visited me on the 22nd of August.

The condition of the eye was now very different to its state when I had previously seen it. The cornea projected forwards in a conical form, the apex corresponding with the original wound; it was clear at its base, and the iris was there visible lining the cone. The apex was densely opaque, much thickened, and contained a dark substance, evidently a foreign body. This I drew out with forceps, and it proved to be a chip of wood, concealed behind the iris when I first saw the case, but which had gradually worked forward. The cause of irritation being removed, the wound in the cornea quickly healed, the dense thickening diminished, and when the patient left town, at the expiration of a week, the prominence of the cornea had already decreased.

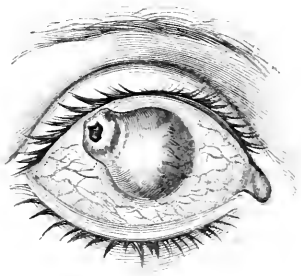

Case II.—Shot in the eyeball upwards of thirty years.

The Rev. H. W., aged 60, was struck by a shot pellet in the right eye, when a student at Oxford, thirty years since; sight was immediately extinguished, and considerable inflammation followed, but gradually subsided under depletion, mercurialisation, etc. Nevertheless, the eye continued irritable and prone to inflammation from slight causes; the patient was also a great sufferer from neuralgia, which, with the serious disturbance of vision of the left eye, led him to seek advice in town. I had no hesitation in recommending excision of the injured eye, which was performed by me on the 9th of August, 1859, and recovery was rapid.

The special points of interest in this case are contained

in the following report of the condition of the eye, kindly communicated to me by Dr. Bader:—

"The eye had shrunk to about one-third its normal "size. The iris was in apposition with the opaque cornea; "the lens, an irregular white, hard, chalky substance, was "adherent to the uvea. No vitreous humour was present; "the retina was displaced and funnel-shaped; it contained "no retinal elements, but consisted of obscurely fibrous "tissue.

"The inner surface of the choroid was lined by a thin "shell of bone, thickest round the entrance of the optic "nerve; the choroid was adherent to this shell. The space "between the bone shell and the displaced retina was filled "with a transparent yellow (albuminous) fluid with choles-"terine. On the bone shell, and loosely suspended in "some cellular tissue, lay a small shot, which must have "entered the eye through the sclerotic, passing the suspen-"sory ligament." (The preparation is in the Moorfields Museum.)

Case III.—Dislocation of the lens, the effect of vomiting eight days after keratonyxis.

On Tuesday, October 18th, 1859, I operated with the needle on a congenital cataract in the left eye of Miss S., aged 20. The instrument was used lightly, and the capsule moderately lacerated at its centre; the position of the lens was unaltered, and so little irritation followed, that at the expiration of a week the eye appeared to have recovered.

On the eighth day, however, she was attacked with obstruction of the bowels attended with so much irritability of the stomach, that for forty-eight hours everything was rejected by vomiting. It was not until after the administration of ten grains of calomel and repeated doses of purgative medicine, that a passage through the bowels was obtained; then an enormous quantity of offensive fœcal matter came away.

On Thursday, the 27th, I was sent for, and found the eye in the following condition:—The lens had been dislocated, and was pressing the iris forward, obliterating the anterior chamber and partly filling the pupil, which was so widely dilated that the iris was reduced to a mere circular strip. The conjunctiva and sclerotica were acutely inflamed, and there was intense neuralgia of the branches of the fifth pair on that side of the head and face.

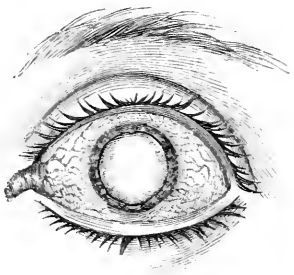

I at once proposed to place the patient under chloroform, and extract the lens; but this proposition did not meet the approval of the patient or her relatives; calomel and opium were therefore administered, leeches applied, and general antiphlogistic treatment adopted. Nevertheless, the inflammation became so acute, and the patient's sufferings so intense, that on the following Monday the required permission for the operation was granted. The patient having been chloroformed by Mr. Potter, I carefully made an incision with a broad iris knife through the cornea near the outer margin, and carried the point into the lens, which was broken up by a few movements of the instrument; the knife was then somewhat turned on its axis, whereby the edges of the wound were separated, and the bulk of the lens was instantly expelled from the eye; the remaining fragments were easily removed with a scoop. The lids were then closed, secured with plaister, and cold water dressings applied.

From this time the cessation of pain was complete; the patient, who had been five nights deprived of rest, slept profoundly more than ten hours; the inflammation, which had been intense, speedily subsided under simple treatment, and at the expiration of a week scarcely a trace remained. The iris, however, continued paralyzed, and the pupil as widely dilated as when the lens was removed; this state of things

yet continues, and, according to my experience, many months may elapse before the activity of the iris is restored. With this exception, the eye is now (November 21st) well, and the vision improving daily. With a three-inch lens large type can be read with facility.

This case forcibly illustrates the advantage arising from extraction of the crystalline lens when displaced, and causing irritation. Instead of the existing inflammation, being aggravated by the wound inflicted on the eye, and the use of the scoop, there was from that time a diminution of all the symptoms; and though it would have been better to have performed the operation when first suggested, as the iris would thereby have been relieved from the injurious pressure which for the time paralyzed it, the retina has fortunately received no injury, and a condition of mydriasis is the worst result which has followed the unfortunate displacement of the lens.

PARALYTIC AFFECTIONS OF THE MUSCLES OF THE EYE.

(*continued*)

By Dr. John S. Wells.

(*Received January 5th.*—Ed.)

PARALYSIS OF THE THIRD PAIR (MOTORES OCULORUM).

The third is the principal *motor* nerve of the eyeball; in the orbit it divides into an upper and lower branch. The former supplies—

The *Rectus superior* and *Levator palpebræ superioris.*

The latter—

The *Rectus internus, Rectus inferior, Obliquus inferior* and *Sphincter pupillæ.*

According to Volkmann and Fäsebeck, the *oculomotorius* also sends a branch to the superior oblique and *abducens*.

The paralysis may differ in degree and in extent, it may be complete or partial.

1. *All* the muscles supplied by the third may be more or less implicated; they may be all completely, or all partially paralyzed, or again, some may be completely, while the rest are only partially affected.

2. One or more branches may be *completely* paralyzed, the rest being unaffected.

3. One or more branches may be *partially* affected, the rest being free.

Complete paralysis is generally owing to some cerebral lesion, whereas the partial is commonly caused by some peripherical affection.

Before entering into the consideration of the symptoms presented by the isolated paralysis of the individual muscles, supplied by the *oculomotorius*, let us first glance at those caused by a paralysis of the third pair *as a whole*.

Paralysis of the Oculomotorius of the left eye.

The upper eyelid hangs down over the eye, upon lifting it, and moving an object in different directions, we find that the eye fails to follow it in an upward, inward, and downward direction; but that it can still accomplish an outward movement by the aid of the *Abducens*, and a slight downward and outward rolling movement, through the action of the Superior Oblique. But we generally find a secondary contraction of the *R. externus* soon supervening, which pulls the eyeball outwards, thus giving rise to a divergent squint with crossed *diplopia*.

If we move the object over to the right of the patient, a divergent squint arises, which increases in proportion as the object is moved in this direction,—the *diplopia* is consequently *crossed*. Upon moving the object in an upward direction, the right eye will follow it, but the left not being

able to do so, the rays from the object fall upon a portion of the retina *below* the *macula lutea*, and the image is projected *above* that of the right eye.

The reverse will be the case when the object is moved downwards, for owing to the inability of the left eye to follow it, it will stand higher than the right eye, the rays from the object will fall upon a portion of the retina, *above* the *macula lutea*, and the image will be projected *beneath* that of the right eye.

It is important to ascertain whether the superior oblique is implicated or not.

How is this to be done?

We have stated that when the patient endeavours to look downwards, the eye shews a rolling movement, owing to the action of the *trochlearis* muscle; this would be a very good guide to us, if the *oculomotorius* paralysis were always complete, and the optic axis steady, but frequently this oscillates so much, that it is almost impossible to ascertain exactly, whether or not the *trochlearis* is acting.

But we have two other means of ascertaining the freedom of the superior oblique.

1. On looking downwards, the divergence must increase if the *trochlearis* is not implicated, for as the *R. inferior* is paralyzed, the unopposed action of the *trochlearis* will pull the cornea downwards and outwards, thus giving rise to, or increasing the divergent squint.

2. We call the *diplopia* into requisition in order to assist our diagnosis.

As the *obliquus superior* acts most upon the height of the cornea when the eyeball is moved inwards (the *R. inferior* then exercising least action upon it), there will arise a point, when the patient looks downwards and inwards (in our case to the right), at which the differences as to the height of the cornea (and of the double images), will be reduced to a minimum or even altogether annulled.*

* This of course only holds good in cases of very partial and slight paralysis (Pareses).

The action of the *trochlearis* upon the height of the cornea diminishes, its influence upon the V. M. increases as the eyeball is moved outwards, consequently we shall find, if the muscle be intact, that the differences in the height of the double images *increase* (owing to the paralyzed *R. inferior* being unable to move the cornea sufficiently downwards), and that they also appear to slant the more as the eye is moved downwards and outwards. For the action of the superior oblique upon the V.M. (inclining it inwards), is now unopposed, and thus the parallelism of the V.M. of the two eyes is destroyed; the double images are crossed, and the image of the left eye slants inwards, so that they appear to the patient to converge at the top, as in Fig. I (II,3, a′ b′).

Fig. I.

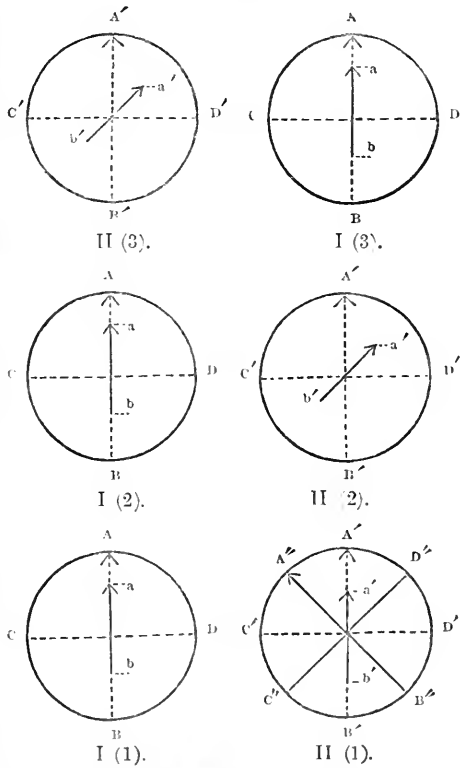

I (1). The healthy right eye, its V.M. (A B), remains vertical.

II (1). The left eye affected with an *oculomotorius* paralysis, in consequence of which the superior oblique exercises uncontrolled sway over the V.M. (A′ B′), and inclines it inwards (A″ B″), (when the eyeball is moved downwards and outwards). The parallelism of the V.M. of the two eyes, is

therefore destroyed, for the V.M. of the left eye, instead of being vertical (II (1), A′ B′), is inclined inwards (A″ B″), so that the V.M. of the two eyes *converge* at the top (A B I (1), and A″ B″ II (1)).

In I (1), the image (a. b.) of a vertical object would fall in the V.M., but in II (1), the V.M. is inclined inwards (A″ B″), therefore the image (a′ b′), will not fall in the V.M., but in the outer and upper (A″ D″), and inner and lower (B″ C″), quadrant of the retina; therefore, the *pseudo* image would, if the *diplopia* were homonymous, appear to the patient to be inclined outwards, and the images *diverging* as in I (2) a b, and II (2) a′ b′; but the *diplopia* is crossed, and the image of the left eye is transferred to the right side of the patient (a′ b′ II (3)), and the right image to the left side (a b I (3)), consequently the tops of the images converge, that of the left eye leaning *towards* that of the right eye.

If the branch to the *sphincter pupillæ* is paralyzed, the pupil is slightly widened (about $2\frac{1}{2}$ lines in diameter) and immoveable. Von Graefe has seen several cases in which the paralysis of the pupillary branch was the precursor of a general *oculomotorius* paralysis, the re-innervation of the *sphincter pupillæ*, also heralding that of the other muscles.

The pupil enlarges *ad maximum*, upon the application of atropine. In some rare cases of paralysis of the third pair, we find the pupil dilated to its fullest extent, and this phenomenon we can only explain, by supposing that whilst the branch to the *sphincter pupillæ* was paralyzed, that of the sympathetic to the *dilatator* was only irritated, thus causing the contraction of the latter, and consequent dilatation of the pupil, and yet this paralysis and irritation might be dependant upon the same cause (pressure from tumours, etc.), for it is a well known fact, that the amount of pressure which causes a paralysis of a motor nerve, may only suffice to irritate a sympathetic branch.

We cannot leave this part of our subject, without glancing at the effect which a paralysis of the third pair may have upon the power of accommoda-

tion, and we shall find that the adjustment of the eye to different distances is preserved, as long as the innervation of the *sphincter pupillæ* (and ciliary muscle) remains intact, even although all the external muscles of the eyeball are paralyzed, but that the accommodation is destroyed if the *sphincter pupillæ* (and *tensor choroideæ*) is paralyzed. We shall however, return to this directly.

The view that the muscles of the eyeball play the chief *rôle* in the mechanism of accommodation, has long been a favourite one, and has found one of its chief and most able supporters in Professor Arlt, of Vienna, who says, "The accommodation or adjustment of the eye for near objects, is brought about by the elongation of the eyeball in the optic axis, by the pressing back of the posterior wall of the eyeball, by the retrogression of the *macula lutea* and its neighbourhood. The organs which cause this, are, on the one hand, the straight and oblique muscles of the eye, on the other the ciliary muscle, they being simultaneously placed in a higher state of tension," etc.*

That the action of the muscles of the eyeball is not however, the *sine quâ non* of accommodation, is illustrated in an incontrovertible manner, by a case of Professor von Graefe's, in which all the *Recti* and *Obliqui* of both eyes, were paralyzed, so that the eyes were perfectly immoveable, the branches to the *sphincter pupillæ*, were, however, not implicated (the innervation of the *tensor choroideæ* must have been also intact), and yet the accommodation of the patient was perfect.†

It is also incomprehensible how so tough and unyielding a membrane as the sclerotic, can undergo the requisite changes of form in a sufficiently rapid manner, to meet the exigencies and subtleties of the ever varying, ever rapid changes of accommodation; and how the amount of pressure necessary for these changes of form, does not call up *Phosphènes*, when ordinarily, even the gentlest touch of our finger awakens them.

It must however, be admitted, that the external muscles of the eyeball possess accessory qualities with regard to the accommodation: for pressure applied to the eyeball can remove the "*far point*,"‡ still yet a little further from the eye; this pressure may be brought about by the *Orbicularis*, as well as by the action of the external muscles of the eyeball; and from this reason we see shortsighted persons nipping their eyelids together, in the endeavour to see a distant object more distinctly; for in this way they not only exclude the dispersed rays of light, but also by a slight flattening of the cornea lessen the amount of their *myopia* (the effect of this is of course very trivial), Normal eyes are made slightly presbyopic, by the same amount of pressure.

Max Langenbeck, Cramer, Donders, and Helmholtz, have paid most

* Arlt's Krankheiten des Auges, vol. iii, p. 207.

† Archiv für Ophthalmologie, vol. iii, part 2, p. 299.

‡ The *far point* (fern punkt), is the furthest point of distinct and accurate vision. The *near point* (nahe punkt), is the *nearest* point at which we can see distinctly.

particular attention to, and examined most carefully into the intra-ocular changes during the accommodation. It was found by Langenbeck, that during the accommodation for near objects, the anterior lenticular capsule approached the cornea, he made use of Purkinje's experiment, and ascertained that the reflex image of the anterior surface of the lens became smaller and approached that of the cornea. Helmholtz has constructed a most ingenious instrument (after the plan of the astronomer's heliometer), and with it has calculated these changes during accommodation.

The changes which he observed in the eye during the accommodation for near objects, were the following:

1. The pupil contracts.
2. The pupillary edge of the iris moves forward.
3. The peripheric portions of the iris recede.
4. The anterior surface of the lens becomes more arched, and its centre moves forward.
5. The posterior surface of the lens becomes likewise a little more vaulted, but does not perceptibly change its place. The lens therefore becomes thicker in the centre.*

These changes of the lens appear according to calculation, to suffice for the explanation of the changes of the accommodation of the eye.

The mechanism which causes these accommodative changes in the form of the lens, is, however, still enveloped in great uncertainty, and cannot be definitely determined, until the different opinions as to the origin, insertion, innervation, action, etc., of the ciliary muscle, are accurately and conclusively settled. Cramer thought that these accommodative changes could only take place, as long as the iris remained intact. But this hypothesis is contradicted by our daily practical experience, for we see patients accommodate perfectly, after the performance of iridectomy, etc.

The arching of the lens in accommodation for near objects, was attributed by Cramer, to the action of some contractile structures situated within the eye. He supposes that the iris exerts a pressure upon the periphery of the lens, the *dilatator* and *sphincter iridis*, being both in a state of contraction, the anterior portion of the lens, therefore, bulges forwards towards that spot where alone no pressure is brought to bear upon it, viz., the pupil. As the *sphincter pupillæ* is contracted during accommodation, it forms, so to say, a fixed point for the radial fibres of the iris, so that these can press upon the lens and the vitreous humour. The *tensor choroideæ* is, according to him, only of secondary consideration, and useful chiefly in preventing the receding of the lens during the pressure of the iris. When the *sphincter choroideæ* is paralyzed, of course the fixed point anteriorly is lost, and thus the want of accommodation in the *oculomotorius* paralysis (the branch to the *sphincter* being implicated), might appear to verify this theory of Cramer's; but this cannot be accepted, as long as it is doubtful whether the ciliary muscle is supplied by the third pair, or by the sympathetic; for if the *tensor choroideæ*

* Archiv für Ophthalmologie, vol. i, part 2, p. 68.

is supplied by the former, may not the loss of accommodative power in an *oculomotorius* paralysis, be with justice attributed less to the loss of the fixed point, than to the paralysis of the branch which supplies the ciliary muscle? In fact, we often see in cases of paralysis of the third, the re-innervation of the pupillary branch perfected, and yet the re-accession of accommodation delayed for some time; it is only probable that although the *sphincter pupillæ* acts, the branch to the ciliary muscle is still affected, and the accommodative power thus hindered. Helmholtz and Donders, both consider the iris, in conjunction with the *tensor choroideæ*, as the chief factors of the accommodation, but H. Müller vindicates the consequence of the *tensor choroideæ*, and estimates the value of the iris, in bringing about the necessary changes of form in the lens at far less; and this opinion is gaining ground rapidly.

Just as I had finished this paper, I had the opportunity of seeing the following most interesting case in the clinique of Professor von Graefe (who has kindly permitted me to publish a short notice of it), which links itself most admirably on to our consideration, "whether or not the iris plays so very important a part in the mechanism of accommodation as has been attributed to it by some observers?" Karl Sange, aged 21, by business a locksmith, had the misfortune to be hit, on the 26th November, 1859, upon the right eye by a chip of metal, about an inch in length; upon the 1st December he presented himself at the clinique of Professor von Graefe, when a *prolapsus iridis* was found in the right eye, near the outer horizontal margin of the cornea, the *sphincter pupillæ* being included to such an extent in the *prolapsus*, that the inner portion of the iris was much widened (which might perhaps predispose it to a *dialysis*), and that the inner edge of the pupil laid nearly opposite the centre of the cornea. As the *prolapsus* became somewhat swollen and thickened von Graefe determined a few days after his admission to remove the prolapsed portion; during the operation the patient made a sudden violent jerk with the eye, which caused an *iridodialysis* at the inner portion of the iris. The patient was at once put under chloroform, and von Graefe *removed* the *whole* of the iris. There was no reaction, but very little bleeding, and the patient recovered perfectly in the course of a few days. The eye was then most carefully examined (also ophthalmoscopically) and was found perfectly normal, and then a most minute and careful examination was entered into, as to the state of vision and accommodation, with the following results:— The field of vision of the right eye is normal; the sight most excellent, so that the patient can count fingers at the distance of 120–140 feet, and can read the *smallest* print (No. 1 of Jæger's Print Scales) He possesses great power over the dispersed rays (*zerstreuungs kreise*) and does not find himself in the least dazzled by the light. And lastly, to crown all, the accommodative power of this eye, with its *irideremia totalis*, is *almost* perfect ($\frac{1}{6}$th–$\frac{1}{7}$th).

Upon the application of atropine, another most important phenomenon presented itself, viz. the complete destruction of the accommodative power, which can only be attributed to the paralysis of the *tensor choroideæ*.

It is hardly possible to over estimate the importance of this extraordinary case with respect to the mechanism of accommodation and the opinions which are even yet prevalent, concerning the great dazzling caused by iridectomy, the confusion produced by the dispersion of rays of light, etc., and I trust that a full account of this patient will be published by Professor von Graefe himself.

Let us now return to the phenomena presented by an *oculomotorius* paralysis.

Upon closing the healthy eye and telling the patient to walk up to a certain object, we find him seized with giddiness and faintness, so that he reels about in his gait, owing to the illusion existing in his mind between the real and imaginary position of objects. We have before stated that when one muscle is alone affected, patients get used to this illusion, and in time learn to correct it, but here so many muscles are implicated that the confusion becomes most harassing and too great to be rectified.

The *exophthalmos*, which shows itself after paralysis of the *oculomotorius*, differs much in extent according to the firmness of the attachments of the eyeball, in some cases where they are tense it is hardly perceptible; it is caused by the paralysis of the *recti* muscles, whose office it is to pull the eye *into* the orbit; in paralysis of the *trochlearis* we find that the double image belonging to the affected eye stands *nearer* the patient than that of the other eye, and at first it was supposed that the turning point of the eye was moved slightly backwards through the action of the *recti* muscles, if this were the case we ought certainly to find that in cases of *exophthalmos*, brought about by *oculomotorius* paralysis, the *pseudo*-image would stand *farther* from the patient than the image of the healthy eye, but this is not so.

H. Müller has lately found that the inferior orbital fissure is blocked up with a reddish grey mass, consisting of bundles of unstriped muscular fibre with elastic tendons, analagous to the *membrana orbitalis* of the *mammalia*. He supposes that this *membrana orbitalis* acts as an antagonist

to the *membrana retractor* and *orbitalis*, viz.: that it protrudes the eyeball; it is supplied by the sympathetic, and it has been found that when the nerve was irritated in the neck, the eyeball protruded (owing to the action of this muscle), if I am not mistaken, this has also been verified by Rudolph Wagner upon the body of a person who had been executed.

I saw the other day in the *clinique* of Professor von Graefe a patient who had been for some time suffering from an incomplete paralysis of the *oculomotorius* and *trochlearis* of the left eye, the pupil was at first only dilated to the extent usual in a paralysis of the third, the *exophthalmos* being excessively slight; a few days ago the paralysis increased, the eye became almost immovable (except in the direction of the *abducens*), the pupil dilated *ad maximum* and the eyeball showed a very marked and rapid increase in the protrusion. May we not suppose that the sudden *exophthalmos* and dilatation of the pupil were here owing to an irritation of the sympathetic occasioned by the same cause (pressure) as the paralysis of the *oculomotorius* and *trochlearis?*

In paralysis of the third pair, the *levator palpebræ superioris* is implicated and the upper eyelid hangs down over the eyeball (*ptosis*). This *ptosis* is, however, not so excessive as when the *orbicularis* is also paralyzed. The eye can still be somewhat opened by the relaxation of the *orbicularis* and contraction of the *frontalis*.

In the upper and lower eyelids unstriped muscular fibres have also been found by H. Müller. The muscle lies in the upper lid just beneath the *conjunctiva* and beneath the anterior portion of the *levator palpebræ*, with which muscle it is posteriorly connected; anteriorly it passes forwarded very nearly to the upper portion of the *tarsus*. In the lower lid this muscle lies also just below the conjunctiva and passes forward to the lower edge of the inferior *tarsus*. These muscles are in both eyelids surrounded with a good deal of adipose tissue. Their action appears to be asso-

ciated with the action of the muscles which move the eyeball.*

Some very interesting experiments in connection with this subject, have been made by Rudolph Wagner upon the body of a person who was executed. Eighteen minutes after the execution he irritated the sympathetic nerve in the neck with the aid of a magneto-electric apparatus; after 3–5 seconds from the commencement of the irritation the eyelids opened, the upper lid particularly receding—the vertical diameter of the opening was about 8 mm. in the middle portion of the eyelids. The pupil dilated gradually to almost its fullest extent.

Wagner remarks that the opening of the eyelids could not be caused by the contraction of the *levator palpebræ superioris* as has been lately supposed, as the character of the movement was quite akin to that manifested by organic muscular fibres when irritated, viz.: a certain time elapsed between the irritation and the visible effect, and the latter lasted longer than the irritation.†

We must now turn our attention to the consideration of the phenomena presented by the isolated paralysis of the individual muscles which are innervated by the third pair; for although this isolated paralysis (particularly of the *obliquus inferior*) is not of frequent occurrence, it is still necessary and useful to be able to analyze and, if need be, construct the different combinations of muscles which are or might be implicated in an *oculomotorius* paralysis.

Paralysis of the Rectus Internus of the left eye.

The action of this muscle was said to be the following in our introductory chapter.

* H. Müller uber einen glatten Muskel, etc. Zeitschrift für wissensch. Zoologie, Vol. IV., Part 4, p. 541. H. Müller. Würzburger Verhandlungen, Vol. IX.

† R. Wagner.—Zeitschrift für rationelle medicin, Vol. V., p. 331.

"The *R. internus* moves the cornea horizontally inwards without exerting any influence upon the vertical meridian, it also assists in moving the cornea diagonally upwards and inwards, and also in moving it diagonally downwards and inwards."*

If we move an object from the left to the right side of the patient, both eyes will be adjusted upon it nearly up to the median line; the left eye will, however, lag more and more behind (owing to the paralysis of the *R. internus*) the further the object is carried into the right half of the field of vision, thus causing a divergent squint.

When the object is held but very slightly to the right of the median line and the right eye covered, the left will make an excursion inwards in order to *fix* the object (thus showing that it had deviated outwards), the right eye making at the same time an associated movement outwards, which secondary excursion, from reasons already explained, is greater than the primary; the patient, if told to strike at the object quickly, goes to the inside (right) of it.

If the paralysis is complete and the patient endeavoured to move his left eye inwards, a vicarious movement of about 10°–15° in an upward and inward and downward and inward direction is brought about by the *RR. superior* and *inferior*. The divergence shows itself sooner upon looking upwards, than downwards; another interesting fact is that the cornea is somewhat raised (normally) when the person looks inwards and somewhat lowered when looking outwards.

The *diplopia* must be *crossed*, as the squint is divergent, for the rays from the object fall upon the outer portion of the retina (when the patient looks to the right) of the left eye and the image is consequently projected inwards (to the right), across that of the right eye, so that the image belonging to the right eye will lie upon the left of the patient, and the *pseudo* image of the left eye upon his right side. The

* Page 50.

lateral distances between the images will increase the more the object is carried over to the right side; there will be no difference in the height or straightness of the images in looking vertically upwards or downwards. This will, however, be different in the diagonal positions of the eye upwards and inwards and downwards and inwards, for in these the *R. internus* assists in preserving the parallelism of the V.M. of the two eyes; we, therefore, find that when the object is moved into a diagonal upward and inward (to the right) position, the right eye follows it, its V.M. being inclined to the right; which movement is brought about by the *R superior, O. inferior,* and *R. externus,* the associated diagonal upward and inward movement of the left eye requires the action of the *R. superior, O. inferior,* and *R. internus,* (its V.M. being inclined inwards, and parallel with that of the right eye), but the *R. internus* is paralyzed, therefore the eye remains vertical, and its V.M. is also vertical instead of slanting to the right, the double images consequently diverge at the top, and the *pseudo* image is inclined towards the right side.

We also meet with a curious phenomenon in this position of the object, viz.: a difference in the height of the double images, without a difference in the height of the corneæ; this apparent anomaly is to be thus explained. In looking diagonally upwards or downwards (to the right) the right eye is fixed upon the object; the left, however, remains nearly vertical, thus giving rise to a divergent squint, the rays from the object fall in the right eye upon the *macula lutea,* but in the left eye, owing to the divergence of the optic axis upon an outer portion of the retina. The V.M. of the two eyes also diverge at the top, that of the left eye being inclined outwards, consequently the rays fall in this eye, not only upon the outer portion of the retina but also, owing to the inclination outwards of the V.M. upon the outer and upper quadrant of the retina, the image is therefore projected inwards (to the right) and *beneath* that of the right eye, as in Fig. II.

Fig II.

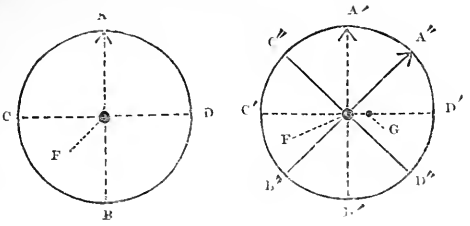

I. II.

Let I. be the right eye, whose V. M. (A B) is vertical and whose horizontal meridian (C D) is horizontal; as the optic axis of this eye is fixed upon the object the rays from the latter fall upon the *macula lutea* (F).—Let II. be the left eye, suffering from paralysis of the *R. internus,* owing to the divergence which occurs upon looking diagonally upwards and inwards (to the right), the rays from the object do not fall upon the *macula lutea* (F′) but upon (G) a portion of the retina external to it—the image is, therefore, projected inwards (to the right). Again we have said that the V.M. instead of remaining vertical (A′ B′) is inclined outwards (A″ B″), the horizontal meridian assuming the position C″ D″, the spot G (upon which the rays fall) lies, therefore, in the upper and outer quadrant of the retina (A″ D″), its image is therefore, projected *inwards* and *downwards.* It lies, therefore to the right side and *beneath* that of right eye.

When the object is held diagonally downwards and inwards (to the right) the right eye is moved downwards and outwards,* its V. M. being inclined inwards; the left eye, however, remains vertical and its V. M. straight, so that the parallelism of the V. MM. of the two eyes is destroyed and they converge at the top, and the *pseudo* image appears to the patient to lean towards that of the right eye (which, owing to the divergence, is upon the left side of the patient),

* In my paper upon the Paralysis of the *R. externus* I forgot to mention that in the diagonal position upwards and outwards (of the left eye), and downwards and outwards, the double images suffered not only an inclination, but assumed also a difference in height; so that the *pseudo*-image lies in the former position *beneath* that of the right eye, and is inclined to the left; in the latter position it is *above* it, and inclined to the right.

the rays fall upon the lower and outer quadrant of the retina and the image is, therefore, projected *above* that of the right eye, as in Fig. III.

Fig. III.

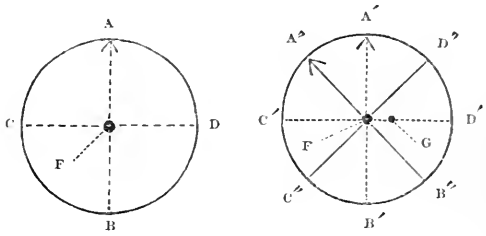

I must again refer to the fact that the inclinations of the V. MM. are merely relative; so that, although in reality the image of the healthy eye may be the one which is inclined, it generally appears to the patient to be straight, and the image of the affected eye is the one which suffers an inclination, although its V. M. may remain vertical. The case before us illustrates this. In the position diagonally upwards and inwards (to the right) the V. M. is inclined to the right, that of the left eye remaining vertical; but the images appear to the patient to be crossed and to diverge at the top, the image of the right eye standing straight (upon his left side), the *pseudo* image leans towards the right of the patient (the images, therefore, diverge at the top). The line which would divide the portion of the field of vision, in which *diplopia* exists from that in which the patient enjoys single vision is not to be represented by a line running vertically from above downwards, in cases of paralysis of the *R. internus*, for, as the divergence appears sooner when the eyes are directed upwards, and is retarded when they look downwards, the line runs obliquely from the left to the right, deviating from the vertical line *upwards* towards the left side; *downwards* towards the right side, as in Fig. IV.

Fig. IV.

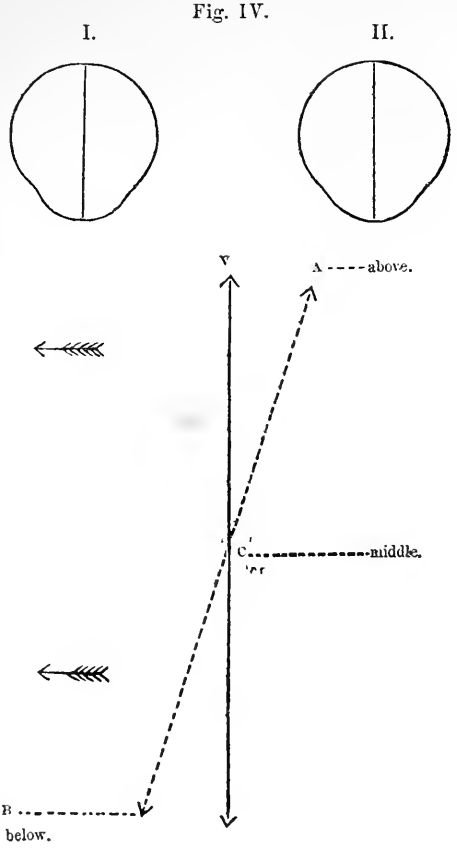

I. The healthy right eye.

II. The left eye affected with paralysis of *R. internus*.

V. The vertical line.

A B. The boundary of the *diplopia* and single vision.

The course of the arrows indicates the territory of the *diplopia*.

With regard to the position of the head of a patient affected with paralysis of the *R. internus;* we find that he carries it turned towards the right; so as to avoid *diplopia* by bringing objects more into the left half of his field of vision; thus evading as much as possible a position which would call upon the action of the paralyzed muscle. Prisms must be applied with their base turned inwards in order to unite the double images.

The paralyses of the next group of muscles we shall find far more difficult and complicated than those of the *R. externus* and *R. internus;* for whilst these act chiefly in the horizontal movement of the eyeball, without any *direct* influence upon the height of the cornea or the position of the V. M., the muscles, to the consideration of which we now turn, viz.,

the *R. superior*, *R. inferior* and the two *Obliqui* exercise not only a lateral action upon the eyeball but influence likewise the height of the cornea and the position of the V. M.; thus complicating the position of the double images very materially. It is therefore essentially necessary to familiarize ourselves with the actions of these muscles and to pay particular attention to the fact that their influence over the height of the cornea and the inclination of the V. M. varies according to the positions of the eyeball. The effect of these muscles upon the height of the cornea increases the more the optic axis approaches their muscle plane; their action upon the V. M. increases the more the optic axis approaches their axis of turning.

Paralysis of the Rectus Superior of the left eye.

This muscle moves the cornea upwards and inwards, inclining the V. M. towards the inner side.

The inefficiency of the paralyzed *R. superior* does not appear in any of the movements of the eye beneath the horizontal median line, for its action is not then called into play; it however makes itself felt when the object is carried above this line, for the left eye will not be able to follow it and lags behind, this deviation increasing as we elevate the object; at the same time a divergent squint will arise, for the *R. superior* also pulls the cornea inwards, but this action is now wanting, and the cornea will follow the unopposed action of the *O. inferior* and deviate outwards. If we cover the right eye and direct the patient to look at an object held slightly in the upper half of the field of vision, the left eye will move upwards and inwards (the degree depending upon the amount of paralysis), showing that it had deviated downwards and outwards; at the same time the covered eye makes a *greater* associated movement upwards and outwards. The patient in attempting to strike at the object will aim too high.

The *diplopia* shows itself in the upper half of the field of vision. The double images will show lateral distances, will

be crossed (as the squint is divergent), will be of a different height and not parallel. The cornea deviating downwards and outwards, the *pseudo* image must lie above that of the right eye and to the right of it (crossing it); for the rays from an object held above the horizontal meridian line fall upon an outer and lower portion of the retina, and must therefore be projected upwards and inwards.

In accordance with the fact that the action of the *R. superior* upon the height of the cornea increases in proportion as the eye is moved outwards (here to the left), the inefficiency of the paralyzed *R. superior* in raising the cornea makes itself felt more and more as the eyeball moves outwards, and as the rays from the object will then fall upon a successively lower portion of the retina, the *pseudo* image will be projected more and more above that of the healthy eye. *The difference in the height of the double images therefore increases as the eye is turned outwards, but decreases as the eye is turned inwards.*

The V. MM. loose their parallelism when the patient looks vertically above the horizontal line. Normally the vertical position of the V. M. is preserved by the combined action of the *R. superior* and *O. inferior* (in the movement vertically upwards); but the former muscle is paralyzed, therefore the *O. inferior* being unopposed will incline the V. M. outwards; the parallelism of the V. MM. is consequently destroyed, they diverge at the top, the double images are crossed, and also diverge at the top; the *pseudo*-image lying upon the right of the patient, and being inclined towards the right, away from the image of the right eye.

The inclinations which the *pseudo* image undergoes are illustrated in fig. V.

Let I (1) be the right eye, A B its vertical meridian, C D its horizontal meridian, which remain vertical and horizontal. II (1) the left eye, whose V. M. (A′ B′) owing to the paralysis of the *R. superior* is not parallel with that of the other eye, but is inclined outwards by the unopposed action of the *O. inferior* (II (1) A″ B′).

Fig. V.

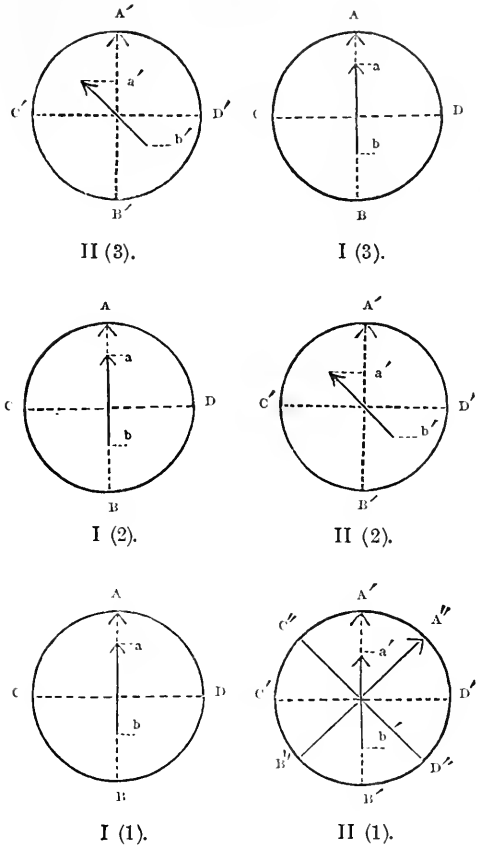

The V. MM. of the two eyes consequently diverge at the top.

In I (1) the image of a vertical object (a b) will fall in the V. M.

In II (1) it will fall in a′ b′, but here the V. M. instead of being vertical (A′ B′) is inclined outwards (A″ B″) and a′ b′ falls therefore in the upper and inner (A″ C″) and lower and outer (B″ D″) quadrant of the retina; therefore a vertical image, when the V.M. is turned outwards as in II (1), would appear to the patient to be inclined inwards (a′ b′ II (2)) and to converge at the top towards the vertical image of the right eye as in I (2) and II (2). But in our case we have crossed double images, owing to the divergence, therefore the right vertical image (a b I (2) will appear on the left side of the patient (a b I (3)), and the inward inclined image of his left eye (a′ b′ II (2)) appears on his right hand as in a′ b′ II (3), but owing to this change of position the image a′ b′ appears inclined outwards, and

the double images diverge at the top. (a b I (3) and a′ b′ II (3)).

As the *R. superior* exercises most influence upon the V. M. when the eye is turned inwards, its inefficiency when paralyzed must also make itself most felt in this direction; we therefore find the obliquity of the *pseudo* image *increases when the left eye is turned inward* (the object carried to the right) and *diminishes when it is moved outwards;* the differences in the height of the images, we have said, *increase when the left eye is turned outwards and diminish when it is moved inwards.**

The patient carries his head thrown back, so as to bring all objects as much as possible into the lower half of his field of vision. Prisms have to be turned with their bases upwards and slightly inwards.

Paralysis of the Obliquus Inferior of the left eye.

Although the isolated paralysis of this muscle occurs most rarely (if ever), being generally paired with the paralysis

* Patients often find it difficult to estimate accurately the degree of obliquity of the image; this may have two reasons according to the position of the object; if the latter be in our case moved outwards the difference in the images would concern chiefly their height and not their obliquity; if we take a lighted candle of ordinary length for our object, the two images of it would be at some distance above each other, so making it rather difficult for the patient to compare their straightness; again, the lighted portion of the candle represents but a small portion of the object, the rest of the candle is more or less shrouded in darkness, the patient will therefore judge chiefly as to the obliquity of the "wick" portion, and this obliquity must be in the outer portion of the field of vision but very small, therefore frequently difficult to appreciate; if we, however, take a white staff or a piece of white paper rolled up, having a length of 12 — 18 inches the differences in the obliquity are generally apparent. When the eye is turned inwards (when there is in our case most effect upon the V. M., and least upon the height of the cornea) the obliquity of the images will be very annoying as they are so close together, and the patient sometimes succeeds in turning the V. M. straight; this we can counteract by giving, through the aid of prisms, a greater distance to the double images and thus prevent their coalescence, in which case the obliquity will usually become at once perceptible; here we should apply the prism with its base downwards, before the left eye.

of one or more of the other muscles supplied by the *oculo-motorius*, I have yet thought it advantageous to consider the symptoms which would be presented by its paralysis, particularly as we shall then be able better to estimate and diagnose the symptoms of its contraction which is so frequently a successor of paralysis of the *trochlearis*.

In the lower half of the field of vision both eyes will be fixed upon the object, when it is raised above the horizontal median line the left eye will lag behind, deviating downwards and inwards, thus causing a convergent squint. If we close the right eye the left will make an excursion upwards and outwards; in aiming at the object the patient will strike too high.

The *diplopia* like that in the paralysis of the *R. superior* appears only when the object is carried above the horizontal median line and shows also difference as to height and straightness of the double images which are, however, homonymous owing to the convergence; the image of the left eye will be projected above that of the right as the left eye stands lower than the right eye.

As the action of the *O. inferior* over the V. M. (inclining it outwards) is annulled, the *R. superior* exercises unopposed sway over it and inclines it inwards, and thus the parallelism of the V. MM. of the two eyes is destroyed and they converge at the top, the double images appearing to the patient to diverge as in fig. VI.

Let I (1) be the healthy right eye A B and C D the vertical and horizontal meridians, which retain their position.

II (1) the left eye whose V. M. (A′ B′) does not remain vertical, but owing to the paralysis of the *O. inferior* follows the unopposed action of the *R. superior*, and is inclined inwards, A″ B″, the parallelism of the V. M. of the two eyes is therefore destroyed, and they converge at the top. (A B and A″ B′ in I (1) and II (1)).

In I (1) the image of a vertical object will fall in the vertical meridian (a b). In II (1) it will fall in a′ b′—but

Fig. VI.

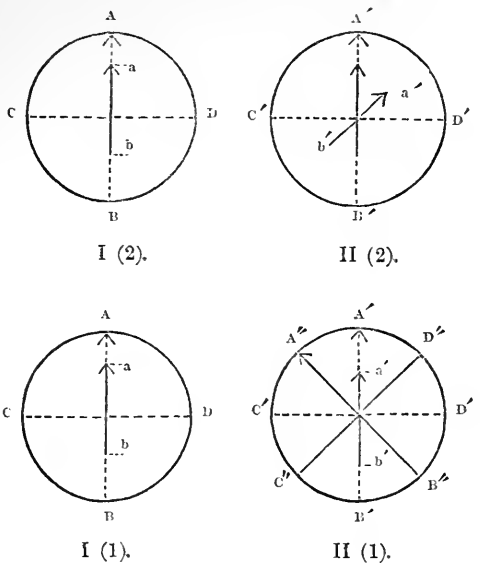

I (2). II (2). I (1). II (1).

here the V. M. instead of being vertical (A′ B′) is inclined inwards (A″ B″) and a′ b′ falls therefore in the upper and outer (A″ D″) and lower and inner (C″ D″) quadrants of the retina: therefore a vertical image, when the V. M. is turned inwards as in II (1) appears to the patient to be turned outwards (a′ b′ II (2)) and to diverge at the top from the image of the other eye (a b I (2)). As the squint is convergent the double images are homonymous, the image of the right eye lying upon the right of the patient, the *pseudo* image of the left eye upon the left side.

The action of the *O. inferior* upon the height of the cornea increases as the eye is moved inwards; when it is paralyzed the double images must therefore show most difference in height when the object is moved inwards (to the right) the image of the left eye rising more and more above that of the right eye as the left eye is moved inwards; this difference *decreases* as the eye is moved outwards. As the *O. inferior* exercises most influence upon the V. M. when the eyeball is moved outwards (to the left) the obliquity of the double images must *increase* when the object is moved outwards and *decrease* when it is moved inwards. This is therefore just the reverse of what takes place in paralysis of the *R. superior*.

The patient likewise throws his head back, in order to avoid *diplopia*. Prisms are applied with their bases turned upwards and slightly outwards.

Paralysis of the Rectus Inferior of the left eye.

The action of this muscle is to move the eye downwards and inwards, inclining the V. M. outwards. In paralysis of this muscle both optic axes will follow the object accurately as long as it is moved *above* the horizontal median line; upon carrying it into the lower half of the field of vision the left eye will lag behind, deviating upwards and outwards; for upon closing the right eye the left makes an excursion downwards and inwards in order to bring its optic axis to bear upon the object, the right eye making at the same time a *greater* associated movement downwards and outwards. The patient in aiming at the object quickly goes *beneath* it.

As we have a divergent squint in the lower half of the field of vision, the cornea at the same time standing slightly *higher* than that of the right eye, the *diplopia* will be *crossed* and the rays from the object falling in the left eye upon a portion of the retina above the *macula lutea* the *pseudo* image will be projected *beneath* that of the right eye.

As the *R. inferior* inclines the V. M. outwards, the *O. inferior* will in a paralysis of the *R. inferior* exercise uncontrolled influence over the V. M. and incline it inwards, thus annulling the parallelism of the V. MM. of the two eyes and making them converge at the top; and the double images will as the *diplopia* is *crossed* appear to the patient also to *converge* at the top, the image of the right eye lying upon his left side, the *pseudo* image of the left upon his right side, and seeming at the top to lean *towards* that of the right eye as in fig. VII.

I (1), the right normal eye, its V. M., (A B) and H. M., (C D) in their proper position. II (1). The left eye, whose V. M. (A′ B′) owing to the paralysis of the *R. inferior* is not parallel with that of the right eye but is inclined *inwards* by the unopposed influence of the *O.*

Fig. VII.

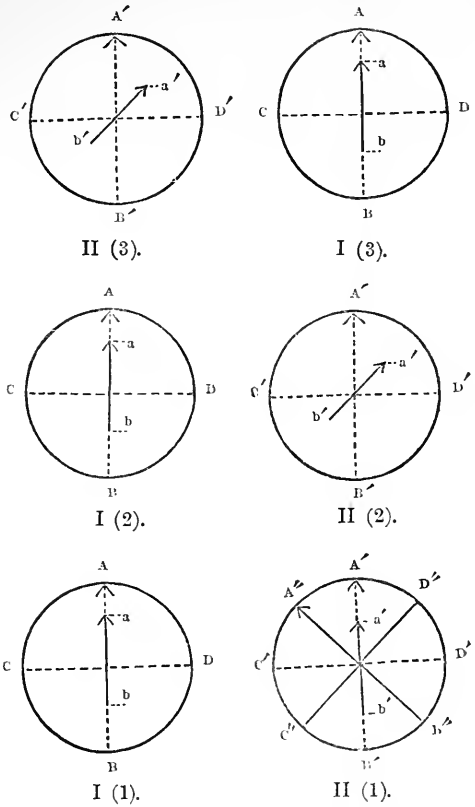

superior (A″ B″ II (1)), consequently the V.MM. of the two eyes *converge* at the top. In I (1) the image (a b) of a vertical object will fall in the V. M. In II (1) it will fall in a′ b′, but here the V. M. (A′ B′) instead of being vertical is inclined inwards (A″ B″), and a′ b′ falls therefore in the *upper and outer* (A″ D″) and *lower and inner* (C″ B″) quadrant of the retina; it would therefore appear to the patient to be inclined *outwards* as in II (2), if the *diplopia* were homonymous, but it is *crossed* owing to the divergence, and therefore the right vertical image (a b I (2)) will appear on the left of the patient (a b I (3)), and the outward inclined image of his left eye (a′ b′ II (2)) lies on his left side (a′ b′ II (3)), but owing to this change of position the image a′ b′ appears inclined inwards, and the double images *converge* at the top (a′ b′ II (3) and a b I (3)).

The inefficiency of the paralyzed *R. inferior* in moving the cornea downwards must make itself more and more felt as we move the cornea downwards and outwards (to the left),

for normally the action of this muscle upon the height of the cornea increases in this direction, as the optic axis in this movement then approaches more and more the muscle plane of the *R. inferior;* owing to this inefficiency the *pseudo* image is projected more and more *below* that of the right eye as the object is moved outwards, the obliquity diminishing in this direction; the latter increases, and the difference in the height decreases as the object is moved downwards and inwards (to the right), for the *R. inferior* exercises most influence upon the V. M. in this direction.

Prisms are to be placed with their bases turned downwards and slightly inwards. The patient inclines his head forward in order to avoid *diplopia* by bringing the objects as much as possible into the upper half of his field of vision.

(*to be continued.*)

PROTRUSION OF THE EYEBALL.

(*continued*)

By Mr. Poland.

(*Received February* 13*th.*—Ed.)

The following cases are illustrations of causes, situated within the orbit, inducing the protrusion of a healthy eyeball from its socket; and further exemplify some kinds of protrusion (of the third division, according to the classification given in Vol. I., page 22) which have not yet been demonstrated.

Case VII.—Foreign body within the orbit; orbital inflammation; protrusion of the eye; extraction of the foreign body; recovery.

C. L.—æt. 10. A strong healthy looking lad was returning from school, having his slate and slate pencil in his hand,

when he tripped and fell, receiving a wound in the upper lid. He hurried home and stated that he thought he had fallen on his slate pencil; this latter was found broken off at the point, to the extent of an inch. There was a small wound in the upper lid, below the eyebrow, accompanied with slight bleeding; but, after careful examination, no indication was found of any portion of the slate pencil having been left in the wound. Some strapping was applied, and no further notice was taken of the occurrence, and it was considered that the missing piece of pencil was lost at the place of the accident. In the course of a few days inflammation of the upper lid set in, which was accompanied with some degree of hardness and slight constitutional disturbance; this increased, and was attended with a good deal of throbbing in the orbit, together with supra-orbital pains. The eye soon began to be more prominent than that of the opposite side, but not to any great extent, although sufficient to indicate the existence of some deeply-seated cause. In this condition he was brought to Moorfields, but careful manipulative proceedings failed to detect anything abnormal, otherwise than the hardness from inflammatory effusion. Considering the history of the case, it was deemed necessary to explore the upper part of the orbit, and, in so doing, thus to relieve the tension caused by inflammatory effusion. A transverse incision was carried along the upper lid, so as to include the cicatrix of the original wound; the scalpel was plunged deeply into the orbit, when the knife grated along some foreign body; this was carefully exposed, seized with forceps, and extracted; it proved to be the missing portion of slate pencil. The inflammation subsided, the eye receded to its natural place, and a speedy recovery followed.

Remarks—

Foreign bodies entering the orbit, and becoming fixed therein are at all times to be regarded with apprehension and fear; the more if they approach to the character of sharp pointed substances (or if they are small shot), the greater the

difficulty of ascertaining their existence in the orbit; for these wounds being of the "punctured" variety, the external opening or aperture of entrance is but comparatively small and readily closes, cicatrizing over before one is made aware of the lodgment of the penetrating body. In the above illustration, the broken pencil entered the orbit through a very small aperture, passed into the orbit through the fascial capsule of the eye, and was then completely lost to external evidence. In the majority of instances nature resents the presence of extraneous matter and sets about its work of expelling it forthwith, and generally this is done by the several processes of inflammation, suppuration, and ulceration carried on progressively either towards the surface of the body, or towards the interior of a mucous canal. But in other, rarer, instances the foreign body is retained in its locality and is shut off from surrounding tissues by being locked up in a cyst and there remaining quiescent for an indefinite period, sometimes for the whole life of the individual; unless, by chance, some accident should occur so as to set up inflammation in the cyst, when suppuration will take place and the dislodgment of the substance will follow. In the case of penetrating wounds of the orbit from small shot, these may become encysted and produce no untoward result, provided that the shot has not lodged near the optic nerve, the globe of the eye, or any important vessel or nerve, but in most cases, as in the present, of foreign bodies entering the orbit, inflammation is speedily set up, and when this takes place in this region, behind the fascial capsule of the eye, severe symptoms are induced, effusion takes place in the loose cellular tissue, which necessarily tends to displace and thrust the eye forwards until a free vent is given by laying open the fascial curtain. Suppuration and the sense of fluctuation should never be waited for in inflammation of the orbit, because in these cases, as in thecal abscess, and in inflammations under other deep fasciæ, mischief may go on to a very dangerous extent without any external tactile evidence. A very characteristic and diagnostic mark for surgical inter-

ference is the presence of a hard, circumscribed, inflammatory swelling, as occurred in the present instance. This should always be attended to and immediately relieved, especially when it is situated near vital and important structures or organs: for, if we wait until it softens, irreparable mischief may have taken place. Again, a foreign body entering the orbit should always be extracted forthwith, so as to aid in preventing other serious consequences, such as diffused inflammation of the orbit, ophthalmitis, inflammation of the brain and its membranes, etc.: as we have always to bear in mind that the dura mater forms a lining roof to the orbit, and that the upper wall is but a thin shell of bone between it and the brain.

Case VIII.—Supposed aneurism in the right orbit; protrusion of the eye; ligature of the carotid of the same side; beneficial effects; subsequent recurrence, etc.

A stout hardy sailor, about 23 years of age, presented himself at Moorfields on my day of attendance. He stated that he had just arrived from America, and would be returning in the course of the following week; he merely requested advice upon his case. As far as my scanty notes serve me (for the full history of the case, taken at the time, has been mislaid) the following account was given.

About three or four years ago, whilst employed as a labourer in New York, he met with an accident, or injury to his head, by the falling of the walls of a house. He was stunned and had concussion of the brain. He was taken to the hospital, and, in three or four weeks, he recovered: but, soon afterwards, this was followed by uneasiness and throbbing about the eye and orbit of the right side, which became much increased, especially whenever he attempted to stoop. The eye soon began to protrude; it became much bloodshot, and was accompanied with distressing pain in the eye and head. There was felt a swelling behind the eye, which

was more prominent on the inner side, and it throbbed and beat so that at times he could scarcely bear it.

The surgeon, under whom he was, at the New York Hospital, he stated to be Dr. Mott, who told him that he had an aneurism of the orbit, and who tied his right carotid artery for its cure. Immediately after the operation, all the throbbing disappeared, as did also the intense pain, and the eye gradually resumed its normal position in the orbit. He left the hospital in a very short time, and was pronounced cured. Some few months after, the former condition of things reappeared; the eye gradually protruded again, and the throbbing and beating recurred, and he could again feel the swelling at the inner and back part, behind the eye. This, however, did not assume such a formidable character as on the first occasion, and he did not seek any advice. He became employed as a seaman, and has been continuing such for the past year. His great difficulty consisted in stooping, for then the rush of blood to the eye would be so great as almost to prevent his persevering with his work. As he had arrived in England he took the opportunity of showing himself at Moorfields for an opinion.

On examination there were the marks of the cicatrix of an incision on the right side of his neck, in the course of the common carotid, which confirmed his statement as to its having been tied. The right eye was protruded forwards and outwards to some extent, and the conjunctival vessels were much injected and distended; the ball of the eye was of normal size: the iris active, and vision good. There was a pulsating tumour behind the eye, becoming prominent on the inner side. This was greatly increased in size when he bent the head down, then causing much pain, with a distressing feeling of tension. There was a decided aneurismal thrill on manipulation, and a distinct *bruit* on auscultation. Pressure on the left common carotid immediately commanded all pulsation, relieved the pain, and allowed of the partial emptying of the tumour, and recession of the eye. The young man himself suggested the propriety of having

his left carotid tied, in consequence of the great relief he always experienced by pressure on the vessel, whenever the tumour became more than ordinarily enlarged. To his proposition I readily consented, and agreed to perform the operation of ligature of the vessel forthwith, provided it was assented to by my colleagues. He was admitted into the hospital, but left in the course of a few hours and did not return again.

Remarks—

This interesting case will add another to the series of traumatic aneurisms of the orbit, collected and published in the Medico Chirurgical Transactions (vol. 42, for 1859) by Mr. Nunneley. The rarity of the disease and the not common operation of ligature of the common carotid, would alone make the case fit for publication. Hence reference has been made to the American journals for information on this subject. The operation seems to have been performed previous to the collection of cases of ligature of the carotid, published in the New York Journal (for July, 1859), and one of these, in all important respects, resembles the present one, viz.: in the sex, age, nature of the accident, the subsequent formation of an aneurism in the orbit, the ligature of the common carotid, and the partial success; but the aneurism is stated to have occurred on the *left* side, and the *left* carotid artery to have been the one tied. I cannot help thinking the case to be the same as the one I have recorded, and that *left* has been misprinted for the word right. However, be this as it may, I have extracted the particulars thereof from that journal (p. 49.)

"Case communicated by Dr. Van Buren, Surgeon to the New York Hospital."

"*Ligature of the left common carotid for traumatic aneurism of the orbit; recovery from operation and arrest of disease.*"

"Robert Duggan, æt. 21, was brought to the New York Hospital with symptoms of fracture at the base of the skull, from the falling of the walls of a house in which he was labouring. There was no external injury; but profuse

bleeding from the left ear, paralysis of the facial nerve of the left side, and concussion of the brain. He recovered from these symptoms, and during the fourth week of his convalescence, projection of the left eyeball was noticed, which continued gradually to increase, accompanied by tension, pain, and injection of the conjunctival vessels. This was at first suspected to be caused by the formation of an abscess at the bottom of the orbit, but every suspicion of the existence of aneurismal lesion being aroused by the unwonted throbbing of which the patient complained I placed my stethoscope over the eyeball one day, and immediately recognized a well-marked aneurismal thrill. This was arrested by pressure applied upon the main trunk of the carotid, and, in subsequent consultation, the ligature of this vessel was advised and performed with the result of arresting the pulsation, throbbing, and tensive pain at once. The exopthalmia gradually subsided, but never entirely disappeared. Slight aneurismal thrill returned about three weeks after the operation, but this has since subsided, and the patient, whom I have recently seen, suffered no inconvenience from the condition of the eye, except from occasional double vision which he noticed only when a little out of sorts."

Remarks continued—

All the questions of the existence of traumatic aneurism in the orbit, viz.: of the symptoms, diagnosis, prognosis, and treatment have been so fully detailed in Mr. Nunneley's paper, that little comment is here required. We have, however, in this instance an evidence of complete failure of the operation on one carotid artery and should be perfectly justified in ligaturing the other carotid, as a means of arresting the disease; inasmuch as pressure thereon seemed to have so good an effect, and as ligature of both carotids may be, and has been, performed at different and distant periods, and has been attended with good results.

In the last number of this Journal (Vol. II., p. 127), there is detailed an instructive case of "Protrusion of the Eyeball, accompanied with some symptoms of Aneurism," but no aneurismal swelling could be detected. It appeared to be one of those anomalous cases of supposed aneurism, requiring the evidence of post mortem examination to clear up the obscurity.

In the 7th number of the Journal (Vol. II., page 6), there is an interesting case, reported by Mr. Hulke, of

"Supposed Orbital Aneurism," wherein all the physical signs were present, necessitating the operation of ligature of the carotid, but with only partial success. The case terminated fatally, and an opportunity was allowed to prove the fact that *bruit*, pulsation, and protrusion of the eyeball may take place to a very marked degree, and yet no aneurism or erectile tumour exist. The pathological appearances in the case were those of phlebitis of the cavernous, transverse, circular, and petrosal sinuses.

This latter case will, of course throw some doubt upon the real condition of the pathological changes in the orbit of the young seaman here recorded as those of aneurism.

Case IX. Syphilitic nodes affecting the frontal bone and roof of the orbit; protrusion of the eyeball; beneficial effects of iodide of potassium; convalescence.

John M.—æt 41, a large, bony, well developed man, became an out-patient at Moorfields, suffering from an extensive swelling of the bone at the upper part of the orbit, encroaching upon the eyeball so as to displace it downwards and forwards. The history of the case, as well as the present marks of old mischief, at once led to the nature of the growth.

From his statement, it appeared that about ten years ago he had undeniable syphilitic inoculation; hardened chancre and a non-suppurating bubo, followed by secondary symptoms of a rather protracted form. He underwent mercurial treatment, both internally and by ointment, and with benefit: ultimately he became free from all symptoms, and since that time at intervals he has had occasional attacks of rheumatism, which have been relieved by iodide of potassium, and on more than one occasion he has had nodes on the tibia, which were relieved by blisters. The present swelling on the frontal bone had been in existence for nearly six weeks, and, within the last few days, had increased most rapidly in size; it was perfectly firm and hard, but very tender and painful,

and seemed to extend towards the orbit, instead of taking the usual course over the forehead, and had already encroached upon the eyeball, slightly displacing it downwards and forwards. There were no cerebral symptoms whatever.

The man was ordered to take three grains of the iodide of potassium three times a day, and to rub an ointment of the same on the swelling night and morning. By persevering with this treatment for three months, the swelling entirely disappeared. The most marked changes took place during the first two weeks of his attendance, but the subsequent progress was slow.

Remarks—

Nodes may be met with in any situation, but generally attack the tibia, sternum, frontal bone, and such others as are little covered by soft parts; for, although these affections are in distinct connection with syphilis, yet in a great many instances the exciting cause of the disease is exposure to external influences. On the other hand, nodes are found in situations removed from all chance of external mischief, such as in the interior of the skull, inner walls of the orbit, inner aspect of the ribs, etc.; in these instances the disease is the more grave, not only on account of the obscurity of its diagnosis, as to the symptoms induced by the encroachment thereof on the contained structures and organs; thus nodes in the interior of the cranium at first involve the membranes of the brain and then the brain substance; in the orbit, however, plain evidence is given by ocular and tactile demonstration. I have seen instances of the development of nodes on the outer as well as the inner walls of the orbit, and these are more generally situated at the anterior part of the socket, yet in rare cases they may be found commencing deeply from the interior. The diagnosis of these cases will mainly depend upon the history of each case, the rapid progress of the disease, and its subsidence into a suppurating state. The most formidable case I have ever witnessed was that of a woman, nearly six feet in height

and of immense bony development. She came under my care at Moorfields some eight or nine years ago, having a large node growing from the inner wall of the orbit; it was perfectly solid to the touch, but pushed the eye outwards and forwards; and had caused tension on the optic nerve, so that there was loss of sight, dilated fixed pupil, and perfect immobility of the eye. She soon afterwards had severe cerebral symptoms and died suddenly in a comatose condition. There was no examination of the body.

REPORT

OF (78) *IRIDECTOMY* OPERATIONS (FOR GLAUCOMA) PERFORMED AT THE ROYAL LONDON OPHTHALMIC HOSPITAL, FROM MAY 1857, TO SEPTEMBER 1859, INCLUSIVE.

(*concluded*)

By Dr. Bader, *Curator and Registrar.*

The most marked changes which the different parts of the glaucomatous eye undergo after iridectomy will be first given, and then the results of the latter as to loss of pain and recovery of sight.

Those cases which were complicated with chronic iritis, or in which escape of vitreous etc. followed the operation, and the after treatment of the eyes operated on are not included in the present report. The irregular attendance of hospital patients has rendered it impossible to arrive at an accurate analysis of all the cases; but so many as could be observed for a year or more are now spoken of.

The *incision* in the sclerotic has generally united from the 2nd to the 6th day after the operation. (The incision is generally made from $\frac{1}{2}$ to $1\frac{1}{2}$ of a line behind the margin of the cornea, and not 2 — 3 lines, as stated in the first part of this report.) It had remained open for a week in one case, and became fistulous in another case—the fluid of the chamber communicated with a small cavity formed between the sclerotic and the conjunctiva—this has been so for eighteen months, and the case is otherwise very satisfactory, the state in which it is appears to be rather favorable, the elasticity of the conjunctiva acting as a kind of safety valve. The incision, when it is made in the cornea, heals quickly, but being at some distance from the periphery of the iris, it renders the removal of the whole breadth of a portion of the iris more difficult.

A *bulging* (staphylomatous state) of the tissue, which

united the incision, has occurred in four cases, in three of them bleeding had occurred into the chamber; the bulge formed during the absorption of the blood in these cases; it was punctured and did not return; the fourth case was one of chronic iritis following the operation.

The *cornea* which in many advanced cases appeared to be sprinkled with numerous minute gray dots, or of which portions of the epithelium were raised in vesicles or peeled off in large flakes, had resumed its transparency and smoothness from the second to the fifth day. Its convexity became changed, the portion corresponding to the excised portion of iris becoming more prominent than the remainder of the periphery of the cornea.

The *anterior chamber* returned almost entirely to its normal size, in recent cases of acute glaucoma. In cases of chronic glaucoma it became larger than it had been before the operation but of course remained still very small. In a case of subacute glaucoma, where hardly any anterior chamber existed for some time before the operation, it was found to have resumed its normal size a year later.

The *area of the pupil* generally became clear immediately after the operation and remained so, unless complications with bleeding or chronic iritis ensued.

In many cases the *iris* speedily recovered its contractibility (sometimes on the second day). In others it remained paralysed. This difference probably depends upon the time and the degree of pressure which preceded the operation, for in recent acute cases it resumed its activity (making allowance for the excised portion of iris).

The *pain* generally subsided from the second to the sixth day. Attacks of pain were observed in a fortnight after the operation in a few cases of acute glaucoma; and in some other cases, which had been operated upon under chloroform and in which the subsequent sickness, etc., appeared to act unfavourably.

No fresh attacks of pain have occurred in those cases, in which the tension of the eye operated upon remained normal. The eye has been tender to the touch sometimes for several weeks after the operation.

The increased *tension* (undue hardness) of the eye subsided from the second to the fifth day. In a few of the cases the tension became even a little less than is natural. In four, out of the whole number of cases, the increased tension continued for several weeks; one of these was complicated by bleeding into the anterior chamber.

In speaking of the *media* and *fundus* of a glaucomatous eye as seen with the ophthalmoscope, only the most striking appearances are now alluded to. The media (*i. e.*, all the naturally transparent parts of the eye in front of the retina) recover their transparency generally during the first week; and in most instances the optic nerve can be seen on the third day. I believe, from dissection of glaucomatous eyes, the impairment of the transparency of the vitreous space to be chiefly due to the temporary loss of transparency of the retina, which prevents the light reaching the choroid, and thus prevents our forming an idea of the transparency of the parts in front of the choroid. A good view of the fundus of the eye (*i. e.*, of the optic nerve, sclerotic, choroid and retina) is generally obtained after a week or ten days. In one case of about seven, round bloodspots are found in the retina, which disappear rapidly (in 3 — 5 weeks) leaving in most cases the transparency of the retina but slightly impaired. Blood effusions beneath the choroid have been observed at or near the equator of the eye; the corresponding retina was displaced and appeared opaque and projecting into the vitreous space. The appearances of the optic nerve are in the order of their frequency as follows:

α. The cupped anemic optic nerve; the sides of the cup being bluish, the centre whitish gray.

β. The cupped optic nerve, the cup being either filled with blood or reddish fluid; this cup assumes after a few weeks the appearance of *α*. Both forms (*α* and *β*) are commonly observed in subacute and in the later stages of acute glaucoma.

γ. The shallow cupped, large, gray, anemic optic nerve as seen in chronic glaucoma.

δ. An anemic (pressure?) optic nerve, with gorged veins and spontaneously pulsating arteries and an optic nerve which is dimly seen through a grayish, slightly opaque substance in front of it have been observed in acute glaucomatous eyes. Both forms change gradually into *α*. A change observed in all glaucomatous eyes, which had perception of light, has

been a restoration of the passage of blood out of the eye; the veins which had been pressed upon the margin of the cup could again be traced over that margin and in many chronic and in all acute cases became again visible in their whole course. An increase of the fulness and number of arteries and a decrease of the diameter and number of veins has been noticed at a later period. The improvement of vision, and the fact of the vessels being among and beneath the optic nerve fibres, make it certain that the latter are relieved from the pressure, to which they were exposed at the margin and along the walls of the cup.

Dissections and the ophthalmoscopic appearances make it probable that the attachment of the connective tissue to the retinal vessels, and to the hyaloid membrane, becomes torn (or stretched in chronic glaucoma), and that the space is filled by serum or blood. The gradual change of shape of the contents of the eye (glaucomatous eyes are generally small) or some change in the connective tissue of the optic nerve or both, may lead to such a rupture.

In many cases it happens that the larger retinal vessels are pressed towards the nasal side of the cup (inverted image); the cups being deepest on the temporal side of the eye; the state of vision generally corresponds to this anatomical fact.

The result of iridectomy, as to vision, is given in the subjoined tables. The results for vision, later than those tabulated, are equally satisfactory: stationary in nearly all cases as regards the power of distinguishing small objects; and greatly improved as regards the recovery of sensibility of the more peripheral parts of the retina in many others.

A report of the ophthalmoscopic examination of glaucomatous eyes (which have been operated upon) as the best means of ascertaining their prognosis, shall be given on some future occasion.

Which eye or eyes affected.	How long before iridectomy began to use convex glasses.	How long before iridectomy attacks of dimness of vision.	Vision immediately before iridectomy.	Vision (generally the second or third week) after iridectomy.
Both	Never used glasses	Gradual loss of vision, R. 6 years, L. 2 years	R. blind, L. perception of light	Both as before
Both	4 months	3 months (gradual loss of vision)	R. faint perception of shadows, L. recognizes objects with the inner (nasal) and central parts of the retina	R. recognizes the hand with the central parts of the retina, L. as before the operation
Both	8 years	R. 2 years. Gradual loss of vision	R. perception of shadows opposite the inner (nasal) half of the retina, L. normal vision with + 10 glasses	Both as before
Left	20 years	Gradual loss of vision 5 years	Perception of light lost for the last 2 months	Faint perception of shadows
Right	(?)	Occasional attacks for 2—3 years	Perception of shadows opposite a circumscribed portion of retina outwards from the yellow spot	Perception of light
Left	15 years	1 month (gradual loss of vision)	Fair perception of shadows	As before

Both	10 years	L. 3 years (gradual loss of vision); R. 2 years	L. no perception of light, R. fair perception of shadows	Both as before
Left	2 years	Gradual loss of vision 18 months	Perception of shadows opposite the inner (nasal) segment of the retina	Recognizes fingers opposite the inner segment of the retina, and has fair perception of objects opposite all the lateral parts of the retina
Both	(?)	L. 2 years, R. 6 months (gradual loss of vision)	L. perception of shadows, R. fair perception of shadows	Both as before
Both	Never used glasses	R. 2 years, L. 8 months (gradual loss of vision)	R. blind, L. faint perception of shadows for 6 months	Both as before
Right *Left lost*	30 years	2 years (gradual loss of vision)	Faintest perception of light	Fair perception of shadows opposite the inner segment of the retina
Both	40 years (several times changed)	L. 3 years, R. 1 year (gradual loss of vision)	L. no perception of light, R. fair perception of shadows (opposite the central part of the retina)	L. as before, R. the whole of the retina has fair perception of shadows
Right	25 years	4 years (gradual loss of vision)	Perception of light and of shadows opposite the outer and upper segments of the retina	Hardly as good as before the operation
Both	14 years	7 years (gradual loss of vision)	L. faint perception of light, R. perception of shadows (opposite the inner segment of the retina)	L. as before, R. faint perception of light of the whole of the retina; otherwise as before

CHRONIC GLAUCOMA—*continued.*

Which eye or eyes affected.	How long before iridectomy began to use convex glasses.	How long before iridectomy ‡ attacks of dimness of vision.	Vision immediately before iridectomy.	Vision (generally the second or third week) after iridectomy.
Left	15 years	3 years (gradual loss of vision)	Faint perception of objects	As before
Right	10 years	3 months (gradual loss of vision)	Perception of light	Recognizes small objects
Both	14 years	3 years (gradual loss of vision)	Perception of light	Both as before
Both	8 years	1 year (gradual loss of vision)	R. perception of shadows, L. perception of objects	R. counts fingers at 6 feet distance, L. slightly improved
Left	15 years	1 year (gradual loss of vision)	Hardly any perception of light	As before

SUBACUTE GLAUCOMA.

Which eye or eyes affected.	How long before iridectomy began to use convex glasses.	How long before iridectomy attacks of dimness of vision.	Vision immediately before iridectomy.	Vision (generally the second or third week) after iridectomy.
Right	12 years	2 years (several attacks)	No perception of light for 2 months	Fair perception of shadows
Right	20 years	6 months (several slight attacks)	Faint perception of light	As before
Both	(?)	L. 4 years, R. 2 years (L. several attacks, R. gradual loss of vision)	L. no perception of light for 7 months, R. no distant vision, but reads large type	L. as before, R. reads average type; sees distant objects
Right	40 years	2 years (many slight attacks)	No perception of light for 1 month	Faint perception of shadows
Both	4 years	2 years (many slight attacks)	L. reads large type, R. perception of light	Both slightly improved
Both	Never used glasses	6½ years (numerous slight attacks of dimness)	B. fair perception of light	R. as before, L. recognizes fingers
Right *Left lost*	14 years	3 years (many attacks)	Fair perception of light for 3 months	Fair perception of shadows

SUBACUTE GLAUCOMA—*continued.*

Which eye or eyes affected.	How long before iridectomy began to use convex glasses.	How long before iridectomy attacks of dimness of vision.	Vision immediately before iridectomy.	Vision (generally the second or third week) after iridectomy.
Left	12 years	12 years (about 12 attacks)	Accidentally discovered that he had mere perception of shadows with this eye	Fair perception of shadows, opposite the inner segment of the retina
Right	Used no glasses	3 months (5 rather severe attacks)	Faint perception of shadows	As before
Left	6 years	1 year (repeated attacks)	Perception of light and fair perception of shadows (opposite the inner and lower segments of the retina)	As before
Right *Left lost*	Never used glasses	3 years (numerous slight attacks)	Could no longer read a year ago; fair perception of light at present	Fair perception of shadows, except opposite the upper segment of the retina
Both	5 years	2 years (repeated attacks, had lost perception of light several times)	Faint perception of light	Both fair perception of light
Both	1 year	R. 2 months, L 6 months (repeated attacks of dimness)	L. no perception of light, R. reads large type; perception of distant objects.	L. as before, R. accommodates from 3″ to 10″; reads average type and recognizes distant objects

Both	13 years	R. 9 months, L. 4 months (several slight attacks)	R. no perception of light, L. recognizes large objects	R. perception of light, L. improved perception of objects
Right	12 years	4 months (repeated attacks)	Perception of objects (opposite the outer (temporal) segment of the retina)	The whole retina has regained its sensibility; reads average type at 10″
Both	12 years	R. 6 months, L. 4 months (one severe attack, followed by several slight ones)	R. perception of shadows (opposite the inner segment of the retina), L. faint perception of light	R. somewhat better than before, L. as before
Both	15 years	L. 2 years (gradual loss of vision), R. 2 months	B. perception of shadows	L. as before, R. improved; the peripheral parts of the retina more sensitive
Left	2 years	2 months	Can see (not to read) large letters	Reads large letters, and tells the time on a distant clock
Right	30 years	4 months	Perception of objects (opposite the inner segment of the retina)	Recognizes fingers, and has fair perception of objects opposite the inner and lower segment of the retina
Both	10 years	18 months (many slight attacks)	No perception of light for 4 months	Both as before

Which eye or eyes affected.	How long before iridectomy began to use convex glasses.	How long before iridectomy attacks of dimness of vision.	Vision immediately before iridectomy.	Vision (generally the second or third week) after iridectomy.
Both	4 years	R. two weeks, L. 11 days (one attack)	R. faint perception of light, L. fair perception of shadows	R. recognises large objects L. reads average type
Both	6 years	R. 4 months, L. two months (one attack)	R. no perception of light (for one month), L. recognised small objects (such as keys)	R. as before, L. reads average type
Both (*R. subacute.*)	35 years	R. 4 years (three severe attacks), L. one week	R. perception of light for 4 months L. perception of shadows	B. recognise distant objects, R. reads average, L. reads small type
Both	25 years	2 years (one attack)	L. no perception of light for 20 months, R. perception of objects (opposite the inner segment of the retina, 1 year)	Both as before
Both	6 years	3 months (one attack)	L. fair perception of light, R. counts fingers	Both read small type
Both	25 years	4 weeks (one attack)	Blind for two days; then vision returned to perception of large objects	Both read average type
Right	10 years	10 days (one attack)	No perception of light	Counts and recognises fingers

Right	?	4 months (one attack)	No perception of light for 3 months	Fair perception of shadows
Right *Left lost* 16 *years.*	51 years	2 days (one attack)	Reads large type, no distant vision	Reads average type and recognises distant objects
Right	25 years	9 weeks (one attack)	Fair perception of shadows for 3 weeks	Tells time on a small watch and sees distant persons
Right	30 years	One attack 5 weeks and a second 2 days	No perception of light	Recognises fingers and sees distant objects
Both (*L. subacute.*)	20 years	R. 2 days, L. (2 attacks) a year	R. perception of light, L. blind for 8 months	R. counts fingers and sees distant objects, L. as before
Both	10 years	R. 3 months (one attack, vision lost within 3 weeks), L. 7 weeks	R. no perception of light, L. faint perception of light	B. no perception of light
Both	Never used glasses.	10 weeks (one attack)	No perception of distant objects, counts fingers with difficulty	Recognises fingers and distant persons
Right	10 years	5 weeks (one attack)	Faint perception of shadows for 8 weeks	Sees distant objects, and counts fingers at from 6″ to 10″
Both	Never used glasses.	6 months (two severe attacks)	R. faint perception of light for 3 months, L. fair perception of light for 2 months	B. see distant persons and recognise fingers

OPHTHALMIC HOSPITAL REPORTS,

AND JOURNAL OF THE

ROYAL LONDON OPHTHALMIC HOSPITAL.

No. XI.

April, 1860.

It is not without interest to learn that sunlight can be depended upon, and employed for ophthalmoscopic work altogether in another country, Dr. Macdonald, ophthalmic surgeon to the Demilt Dispensary of New York, having sent me the following observations on

THE SUN-OPHTHALMOSCOPE.

"The use of sunlight instead of artificial light in ophthalmoscopy first suggested itself to me about a year ago, as a means of examining the patients attending the Institution to which I am attached, and in which I had no facilities for examining by the ordinary method. The advantages which I have found it to possess are such that I now prefer to use it in my private practice. Of course, the plane or concave mirrors hitherto used could not be employed with sunlight, as its intensity would be too great; *convex* mirrors, however, by diverging the rays of light reflected from them, diminish its intensity, and the sun's rays reflected by such mirrors can be easily borne. Those that I employ are of glass, about one inch in diameter, have curves, one of 4, and one of 8 inches radius, and from their centres a disk of the silvering, about $\frac{1}{12}$ of an inch in diameter, is removed. With photophobic cases, the weakest mirror, *i.e.* the one having the greatest curve, is used; in ordinary cases I use the other. The patient is seated in, and with his back to, the sun, and the surgeon proceeds as with the ordinary ophthalmoscope.

"Sunlight is much superior to other means of illumination, its intensity may be increased to any extent, and with it

the fundus of the eyeball is seen of a more natural colour and appearance. By the use of convex mirrors, the field of the retina illuminated is much greater than when concave instruments are employed; for this reason, this instrument is much less difficult to use than others, and a tyro will distinguish all the points of interest in the retina at his first attempt. Dr. W. Zehender, in the first volume of the 'Archiv für Ophthalmologie,' first proposed the use of convex mirrors, but only with artificial light."

In this country, especially perhaps in London, sunlight is too uncertain for us to think of its being commonly used; but I recollect, that some years ago, in the case of a foreign body to be removed from the vitreous space, I availed myself of the sunlight for a final examination in the operating room: the sun was shining dimly through a fog, so that I could use the concave mirror we have for an ordinary lamplight examination without distressing the patient, and with very effective illumination for my inquiry. It may be worth consideration for sunlight ophthalmoscopists who prefer, or who happen to have the ordinary concave mirrors adapted for lamplight examinations, that the same should be used with sunlight, as it could be easily and well qualified, I suppose, by diminution of the too great illuminating power it had at any time. For this purpose, the patient might be seated with an upright screen attached to the high back of his chair, and thus would be protected from the heat of the sun, and on either side of the screen might be a shutter, to adjust, by sliding up and down to the height of the patient's head, with an aperture at which the sunlight would be admitted, and its extra power of illumination there reduced and regulated by one or more white curtains of crape or muslin.

J. F. S.

VARIOUS OPHTHALMOSCOPIC APPEARANCES OF THE VESSELS OF THE OPTIC DISK, WHEN EXCAVATED.

An optical illusion may be observed with the ordinary ophthalmoscope (the biconvex lens being used) when the optic nerve is "cupped." In a case of mine in which it was particularly observable, the *media* being clear and the "cup" deep, I have drawn the entrance of the optic nerve in three different conditions, and given diagrams to illustrate the various appearances of the illusion of which I speak.

The case was in appearance one of those called "amaurosis with excavation of the optic nerve."

Michael Giles, able seaman, aged 30, came to me at Moorfields, on March 19th, 1860, complaining of his left eye, in which his vision was so much impaired, that, although he said it did not trouble him himself, as his right eye was sound, the captain of his vessel had discovered it and complained of him because sometimes, in a dim light, he could not well see the compass at the binnacle.

In the left eye there was a nebula, but only near the inner and lower margin of the cornea; the iris was tremulous; the pupil was circular, of fair size or rather large, responding tolerably to the influence of light; there was no external evidence of inflammation past or present; the globe was of about normal tension: he could only tell fingers or other large objects held near it. The right eye appeared altogether healthy, and with it he could see well at average distances.

His history was, that his sight in either eye was quite perfect until six months previously when he had received a violent blow of a shovel on the temporal side of the left orbit; he was stunned and taken to the London Hospital: he had not his right senses, was blistered, and took pills: he had great pain in the head and eye, the latter was very painful, and afterwards very sensitive to light, however he soon left the hospital quite well, excepting occasional headaches which he did not lose for some weeks afterwards, and but for indistinctness of vision, of the left eye only, he thought he had quite recovered. He went back to sea for two months, again for about the same length of time, and made a third voyage of six weeks, after which he came to the hospital for the reason I have mentioned: he had not remarked that in either voyage his sight had become much worse: he had had no pain and did not seem to be in any trouble about it. Sometimes, especially in the evenings, he had seen "like sparks," or a "cloud" passing over the eye for a few minutes together.

I put atropine to both eyes: the right eye presented nothing noteworthy, but a slight congestion of the entrance of the optic nerve: the left showed a very deep cup (Plate XI, X, Y, Z) with two veins (X, Z) passing out, and one artery passing in by it; the pulse could be detected in the latter by a close examination; the vessels dipped over the edge and curved down the sides of the cup with a perspective appearance: slight pressure on the globe stopped the circulation in the veins. There were two marks, like separations or ruptures of the choroid, showing through them the sclerotic below (above) the entrance of the optic nerve: one close to it (*a.b.*) having a curve corresponding to about a quarter of a circle of which the optic nerve was the centre, and another also curved to the same centre but more remote from it, nearer the yellow spot, and of less extent.

Pulsation being visible and all the vessels somewhat pressed against the margin of the optic nerve, I admitted the patient thinking to perform iridectomy. He had the full diet of the hospital, and, of course, complete rest besides belladonna used for the ophthalmoscopic examinations, and before I did the operation the pulsation was no longer visible without pressure exerted on the globe, and vision in this eye had improved so that (especially as the indications were never very promising) I did not operate, the patient being contented, and he left the hospital to go to sea again, although I had advised him to engage in some other employment. He never allowed that at sea he had been worked very hard, or had lived badly.

First—*of the illusion.*—It is well known that, when a collecting lens is used with the perforated mirror, for an

ophthalmoscope, and is moved in any direction at a distance of the focus most convenient to the observer, the position of all that is seen appears to be moved in the contrary direction to that in which the lens is moved. In the case of a cupped entrance of the optic nerve, the vessels as they pass through it (the most conspicuous objects) appear (if the depth is appreciable) to move more than those of the retina (which is supposed to be in focus) at the margin of the excavation, when the lens is moved, and most at the bottom of the cup where they are most remote and disappear in the substance of the optic nerve: so it was in the case I have related and from which my illustrations are drawn, the least movement of the lens seeming to thrust the vessels at the bottom of the cup forcibly in the opposite direction to the movement I had made.

These appearances may be demonstrated with a (small coffee) cup and a stick of liquorice, one end of which is stuck at the bottom of it, which, with a biconvex lens held before it, will be seen as it is affected at different parts of its length, the end next the observer being most distinct, least magnified and least altered in position apparently by the movements. In examining a patient's eye, however, with the lens, the parts are also apparently reversed in every way (not antero-posteriorly), but this addition of other refracting powers (the crystalline lens, etc.) does not alter the relation of the parts, so that with objects external to the eye and one lens the demonstration is good.

When the object (*retina*) is examined through the axis the most correct image is presented and when the ophthalmoscope lens only is moved, the same object is seen through the margin of the lens, which refracts more, and (always reversed) is therefore more and more bent as it is nearer the margin.* When some part of an object is more distant than another (*bottom and margin of the optic nerve excavation*) the former, if it is visible, is more affected thus apparently, and by different movements, the image may be turned in as many ways, and thus the vessels at the bottom of the cup appear differently placed in relation to other parts as in the

* Whilst centrally, by this movement, other parts are brought into view; so that, as the readiest way, this movement is ordinarily used in examining parts near to those in the axis of an ophthalmoscopic examination, although it is only to some slight extent available on account of the size and position of the pupil interrupting the light, so that the observer has to move his head also or change the direction of the patient's eye.

diagrams. (Plate XI, A, B, C, D, each of which shows the altered appearances of the veins in the cup when the lens was moved (A up, B down, C to the right, D to the left), as compared with the central figure in which the lens was held correctly in the axis of vision). The illusion is also increased by the nearer position of the pupillary margin which is seen when the object is viewed through it, and as one side of the cup is brought more into view and the opposite less by each movement of the lens, one or other side being thus hidden by its margin. This is to say, I believe, that spherical and other aberrations are greater for more distant parts as they are more magnified by the biconvex lens.

This exaggerated aberration of the vessels in the cup will show that an excavation exists, (that the vessels are not on a level with the retina is proved by their not being seen ophthalmoscopically when, *without the lens,* they are visible on the margin of the cup) and the greater amount of aberration in any case will by experience indicate the amount of excavation, which, if it was of importance, might be thus measured to a scale.

Sometimes I could have imagined that the vessels in the retina were the most remote; the cup was so deep, and its margin so projecting, that the vessels were hidden as they passed along the sides of the excavation, and seen in the cup, they appeared unconnected with those at its margin and in the retina; so that, without intervening parts for comparison, or perhaps in some other way, a *false* illusion could be produced: it then appearing that the vessels on the plane of the retina moved more than those at the bottom of the cup, and, passing from before, exposed them more in the cup on either side *towards* which the lens was moved.

In these cases no real doubt of the concavity of the optic nerve's entrance could be entertained: the last of this kind, I have seen, was an ordinary case of chronic glaucoma.

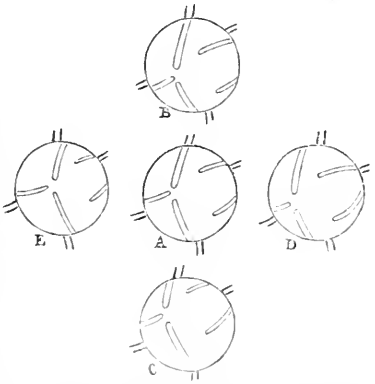

The *false* illusion,—A. lens held centrally, B. moved up, C. moved down, D. moved to the right, E. moved to the left.

Second—*of the pulse.*—In the present instance this pulsation (synchronous with that at the wrist) was sufficiently noticeable in the main arterial trunk when the patient was admitted, but soon afterwards it could not be seen (without external pressure). The artery filled each time, and, becoming straighter, lessened the curves it made in bending over the margin of the excavation: it appeared to stand forward (Plate XI, V, Y) and relapse in the intervals (Y in the central figure).

Third—*of the venous circulation.*—Slight pressure exerted on the globe with a finger increased the pulsation or produced it in the artery and very readily stopped the flow of blood in the veins of the cup (Plate XI, U), then making them empty so as to be hardly seen in it, unless their place was known. More pressure arrested also the arterial circulation.

J. F. Streatfeild.

PUBLISHED CASES.

Case XXXV.—Extraction of a portion of Coal which had been in the Eye ten years, with Recovery of perfect Sight.

By Mr. Nunneley.

As the following case illustrates a result which all who have seen much of ophthalmic surgery will admit to be rare, it seems to be not unworthy of being recorded.

When a hard substance enters and remains in the eyeball, in spite of whatever may be done, in the great majority of cases, sooner or later, the organ is lost, for if it be not destroyed by acute suppuration, commonly irritation is kept up after the more immediate active symptoms have diminished, and the ball becomes soft and ultimately shrinks and collapses, even though the foreign body be small and become embedded. This wasted condition not unfrequently occurring after the lapse of some time.

In February last, J. A., a stout middle-aged man, a Collier by trade, applied to me. He stated that ten years ago, while blasting in the pit, the shot exploded too soon, scattering the fragments of coal with great violence, that by

some of these the left eye was struck, some entering the ball. That for six or seven weeks he suffered great pain, was nearly blind, and was unable to work, but that gradually the pain and inflammation ceased, and the sight of the eye became as good as it was before the accident; but that ever since there have been two or three black specks to be seen in the eye. He has continued uninterruptedly at his work until five weeks before his application to me, when the eye and side of the face were violently struck by the fall of a large hard substance, while at his work. The eyelids were bruised and swollen, but as he was not blasting nor using the pick, and saw the size of the piece which struck him, he is quite certain no particles entered the eye, and that it was simply a hard blow. However, since then he has suffered intense pain in and about the eye, great inflammation, and an inability to open the lids or to work.

I found every indication of acute irritative ophthalmia; there was intense photophobia and lachrymation; both conjunctiva and sclerotic were greatly injected; the iris was dull and inactive; the cornea, particularly at its lower half, was rough and hazy, where also was a dense opaque white patch, with two or three conjunctival vessels going to it, and behind this spot could be indistinctly seen, in the anterior chamber, a dark substance about the size of a swan shot, but what it might be, whether a clot of blood, dark fibrin, or a piece of coal, in consequence of the opacity of the cornea, it was impossible to say. Imbedded in the cornea, towards its upper and outer part, were two small portions of coal, and in the sclerotic conjunctiva near to them two or three very minute particles. As the man was quite certain no coal had entered the eye for ten years, and equally so that during this period until the receipt of the blow five weeks ago, the sight of the eye was perfect, and it was evident that the particles in the cornea were embedded in the tissue which was clear and healthy about them, the case was treated as one of traumatic inflammation. When I saw him after a few days he was very much relieved, the vascularity was lessened, the opacity of the cornea was much diminished, and as the dark spot in the anterior chamber had disappeared, I supposed it must have been a small coagulum which had been absorbed. I did not see him for a fortnight when I found the eye as much inflamed as it was when I first saw him. He said that it had continued to improve until the three previous days, since when he had suffered greatly. He now said that

he felt certain the coal in the eye was the cause of all the symptoms, and begged me to remove it. None was to be seen except the particles in the cornea, and though from the fact of the cornea about them being clear and healthy, I felt certain they were not causing any irritation, at his importunity I tried with a needle to extract them, but found, as I supposed, that they were deeply and completely embedded in the structure, with a layer of clear healthy firm cornea passing over them, while the lower part of this was soft, I therefore declined to farther meddle with them. Again in a few days he presented himself, saying he was certain there was a portion of coal deeper in the eye which moved about, as when the pain had violently returned he had seen it by looking in the glass. I declined to accede to his urgent request that I should open the eye and search for what I could not see, but directed him at once to come to me should he again see the portion. In two days afterwards he called, bringing with him his wife, both of them declared that before leaving home they had seen the piece, though none could be then seen. They were directed to wait in town for a few hours and should it again come into sight immediately to return. After a few hours they did so, when evidently a portion of coal occupied the same place in the anterior chamber in which I had seen the dark substance on the man's first visit. I at once sent him to the Eye Infirmary for operation, where I also saw it, but on his being placed upon the couch it had again disappeared. I now made him get on and off the couch quickly and shake the head suddenly several times, which brought the particle into view. A section of the cornea was instantly made when with the aqueous fluid escaped the portion of coal.

The next day the wound in the cornea had closed, its curve was restored, the inflammation and pain were much less, and the cornea was much less hazy. On the following day he was so much better that he returned into the country. In three weeks he went to work in the pit, the eye being perfectly well, and the sight as good as ever. The small portions in the upper part of the cornea remaining quiescent, as they probably will do, they having had nothing to do with the recent symptoms.

In this case, in all probability, the coal had been fixed in the posterior chamber, exciting while lying immoveable there no mischief after the subsidence of the first irritation, but that by the concussion of the blow, received five weeks before

I saw him, it had been detached and moveable, becoming at once a cause of irritation by floating through the pupil from one chamber into another when disturbed by the motions of the body or head, and, on entering the anterior chamber and resting upon the anterior surface of the iris, a source of mischief only to be allayed by its removal from the eye. The sudden and complete restoration of the eye after so long a residence of a hard substance within its interior, and the active disease caused by it during the last ten weeks, is an interesting fact.

Case XXXVI. — Entropion, occasionally following (involuntarily) a trick of forcible Winking.

By Mr. Streatfeild.

Arthur Wire, aged 16, came to me at Moorfields on the 22nd of March, in the present year, complaining that his eyes were *watery*, and that sometimes he had to take hold of the eyelashes with his fingers to get them *right*. I found this meant that he had at such times inversion of the lower lids, and that he then, by seizing the ends of the long lashes, had learnt so to replace the lids in their normal position.

He was a sailor, and the occasional malposition seemed to have been produced by a way he had of closing the lids firmly for an instant, or, as he said, of *snapping* them, which he was in the habit of doing, probably to assist his vision for distant objects he was expected to see in his occupation. He had not generally any lachrymation or entropion.

As a cause of entropion, this would have little interest, but in connexion with the *voluntary* cases reported in the last number (X) of the Journal, at pp. 176 and 186. The patient, in the present instance, could not invert the lids at will, but he probably would have acquired the power by practising the plan he had adopted—the ciliary part of the orbicularis being exerted as in the two cases referred to, although for another purpose.

The palpebral apertures were small; the usual folds of skin above the upper lids extended over them to their margins, and the margins of the lower lids also showed large folds of skin so projecting as to be in contact with the lashes, and this must have been a chronic state of the parts, for

when one of the folds was drawn down with the finger, a furrow, which seemed to be lined with mucous membrane instead of skin, was exposed.

I excised from both of the lower lids a small strip of skin, close to the lashes, and a large portion of the subjacent ciliary division of the orbicularis muscle. The wounds cicatrized in a few days without any sutures, and the abnormal folds of skin were removed. It had succeeded in preventing any re-inversion of the lids, and until he returned to sea, and I lost sight of him, he had not found any difficulty of vision, although it is to be supposed he had not the power of compressing the eyes that he had had.

Case XXXVII.—Much Edema, with slight Conjunctivitis, recurring alternately in the two Eyes.

By Mr. Streatfeild.

Marian P., a housemaid, unmarried, aged 33, came to me first on January 19th, as an out-patient at Moorfields, complaining of a swelling of the lids of the left eye: this had been so for a week. She was very pale, and her pulse was weak and slow, but she did not appear to be otherwise out of health, nor had she any complaint of ill-health. The left eye only was affected: the lids were so edematous that she could only open them sufficiently to expose half the cornea, although the palpebral aperture, as seen in the right eye, was of fair size: the ocular conjunctiva was raised to some extent in the same way: the skin of the lids was pale and semi-transparent, not warmer or colder than usual: the swelling would take the impression of a finger indistinctly: there was no tenderness. With the chemosis there was slight redness of the conjunctiva, and some thin mucous discharge, but so very little that at first I did not observe it. With these indications, and having found no other, I gave her a mixture, combining quinine and iron, and a weak stimulating lotion for the eye, with which the edema and the conjunctivitis soon disappeared altogether.

On March 5th she came again, with all the symptoms in the right eye that she had had in the left, but in a somewhat less degree: the sub-cutaneous and sub-conjunctival edema

was then on this side only, with some slight redness of small vessels of the conjunctiva, and mucous secretion. I now made more particular inquiries into her case. I found that at different times, for four or five years, she had been subject to "bloodshot" eyes, and for some time lately had been troubled with the swelling of the lids;* never, she said, of both eyes at the same time, or of the same eye twice in succession. She *always* had leucorrhea:† menstruation had not commenced before the age of 21; it was then normal, and at these periods the swelling of the lids always disappeared, if it had been present. Two years ago she had several "blisters," the size of a fourpenny-piece, on the right leg, (the marks of some still remained—pemphigus?) her eye was then inflamed, she said, but there was no swelling. She said her general health was every way good, but that she was not very strong, perspired very much, and whenever she was at all out of health, the swelling of the lids, accompanying the conjunctivitis, was greater. When she first came to me, in January, it was because the lids were so swollen she could hardly see; before this time she had left off taking beer for some weeks because of her eyes. She had only been using warm and cold water to the eyes: the latter had seemed to benefit them. Her appetite and digestion were good. Her urine (1017) contained neither sugar nor albumen. She had not, and was not subject to, any swelling of the feet or of the face, but of the eyelids only. Except anemia, an ophthalmoscopic examination showed nothing noteworthy: her vision was good, and there was no intolerance of light. She said, that at first whichever eye was attacked magnified everything, and that all objects then looked clearer with it (extra blood supply?) The lashes were seldom agglutinated in the mornings; but, especially at the commencement of an attack, the eyes discharged a "watery matter." Yesterday, when the lids were beginning

* She had noted its recurrence for the last six months; and by the account she had kept it appeared that in September the right eye was affected, then the left, then again the right; in November the left eye, and in December the right (each time for two or three days only) was attacked: in January she came to the hospital. These occasions were much more transient and frequent, therefore, in the autumn, but the patient had not generally observed a greater liability to their recurrence at any particular season of the year.

† Some years before she had had to leave her place for giddiness and palpitations; she still had palpitation when making any extra exertion, such as running up stairs, and then she saw the objects move, with the beating in her eyes, for a minute or more.

to swell, she had headache, the eye was tender and felt "burning and heavy:" the swelling comes on rapidly and often disappears altogether in a single night. She had not observed that the swelling was greater at one time of day than another. During the six weeks since I had last seen the patient (in January) she had been in a new "place," and not able to come: both eyes, right and left in succession, had been attacked, and the lids swollen in this interval. I ordered the same mixture and lotion, some treatment for the leucorrhea, and some simple dietetic rules, including the non-omission of the beer, to which she had been accustomed. After this time she attended regularly; I continued much the same treatment, and as she became stronger in health, each after-attack of conjunctivitis was less severe and attended with less and less edema.

On March 12th she came (the right eye had recovered on the 8th instant) with *both* eyes and eyelids in a healthy state. On the 26th, she came again with slight edema, etc., of the *left* eye, which had existed since the 23rd, the tenderness and irritability of the eye having been experienced on the day before. The watery discharge and all the symptoms were less in degree than on former occasions; for instance, the chemosis existed only in that part of the sub-conjunctival tissue which is not beneath the lids when partly open, and where their support is most wanting: the edema also of the upper lid was limited to its edge, or lower border.

During all the month of April the patient attended regularly for the medicine: she had iron, without the quinine: she had been living well, taking some beer with her dinner, etc.: she felt much stronger, her pulse was improved and she had some colour: the leucorrhea, she said, was cured, and as the eyes had not been inflamed for so unusually long a time I do not expect to see her again at present.

Remarks—

I have not seen another case of edematous conjunctivitis like the preceding, in the alternation of its recurrence in the two eyes;* but a great amount of edema accompanying some slight conjunctivitis is not uncommon among very poor,

* With intervals of apparently complete recovery: in conjunctivitis, that is kept up for a length of time, the symptoms are often aggravated in one eye, the other being *comparatively* well.

weakly, anemic patients, and to an extent much greater than in the above-related case. Lately I have had two other such cases, both women, and neither of them old; but one was a pallid needlewoman and had been long suckling, and the other had the sallow complexion of a regular spirit drinker; the latter patient soon disappeared, but the former remained until she had benefited by the general treatment prescribed; she spoke of former recent attacks she had had of the same nature, and these were said to have been first of one eye and then of the other, and that at first both were so affected.

Conjunctivitis having once occurred, seems to be the more liable to return, and that it should not then choose the eye last inflamed, is perhaps a similar instance to the alternation of orchitis, etc. It is probable, also, that a predisposition to edema is acquired by its former occurrence; besides the infiltrated ocular sub-conjunctival areolar tissue, serous effusion would very probably next occupy the sub-cutaneous parts in chronic inflammation of the conjunctiva, for the same vessels supply the parts beneath the skin and the mucous membrane of the lids, and there is no areolar space immediately beneath the palpebral conjunctiva, similar to that occupied by the chemosis. In the case I have related, the low inflammatory action seems to have produced the edema from time to time; as it disappeared with the recurrent conjunctivitis, and therefore I did not treat it merely as a local weakness.* The conjunctivitis in this case produced an extraordinarily small amount of secretion from the mucous membrane, and the pemphigus and other symptoms seem to show a special tendency to serous effusions.

* I had thought of iodide of potassium and blisters; but with tonics, etc., the conjunctivitis and the edema were remedied, and the cause of the one which had produced the other was removed.

A FRAGMENT ON GLAUCOMA AND THE OPTIC PAPILLA.

By Dr. Mackenzie (*of Glasgow*).

(*Received April 25th.*—Ed.)

Former observations; new ophthalmoscopical facts; optical illusion in examining the papilla in the indirect method; normal state of the papilla; diseased states.

* * * * *

I long since† established to my own satisfaction the three following conclusions regarding glaucoma:—

1st. That the sea-green appearance behind the pupil, whence the name arose, does not depend, as was once generally supposed, on any thickened or discoloured condition of the vitreous humour, but on a diplochromatic state of the crystalline, by which it absorbs the extreme prismatic rays, and reflects the middle ones.

2nd. That the vitreous fluid in glaucoma is superseded by an unhealthy secretion, which over-distends the eye, makes it feel hard, causes severe pain by pressing on the ciliary nerves, and obliterates the sensibility of the retina; a state of matters which I found to be susceptible of relief by paracentesis of the eye, through either the sclerotica or the cornea.

3rd. That in advanced cases, the optic nerve behind the eye shows itself, on dissection, in a state of atrophy, deprived more or less of its proper nervous substance, and flattened.

Ophthalmoscopic investigations have added some new facts to our knowledge of glaucoma. One of these is the pulsation of the arteries of the retina; and another, the

† See a paper "On Glaucoma," in Glasgow Medical Journal for August, 1830, and the different editions of my "Practical Treatise on the Diseases of the Eye."

concave or excavated state of the papilla of the optic nerve. Neither of these phenomena, however, is peculiar to glaucoma; both of them being occasionally met with in other diseases of the eye. The former of them seems to indicate an increased resistence to the flow of blood in the vessels which supply the retina; the latter may be regarded as the effect of one or other, or of both, of two different causes, namely, the atrophied condition of the optic nerve, and the increased pressure on the internal parietes of the eyeball, from the superabundant secretion which occupies the place of the vitreous humour.

These phenomena can scarcely be discerned in the advanced stages of glaucoma, owing to the diplochromatic and muddy state of the crystalline. To see them, then, the student should be directed to examine a case, in which the dioptric media have as yet lost but little of their normal colour and transparency.

To discern the pulsatory movement of the vessels, requires a sharp and experienced eye, and the observer will find it of service, while directing his attention to this point, to have the patient's head supported, and the diseased eye steadied by the fingers of an assistant.

If the indirect or inverted method of ophthalmoscopic observation be selected, an optical deception is apt to bewilder a beginner, as to the condition of the entrance of the optic nerve, a nearly circular spot, though not unfrequently oval, variable in size, but measuring on an average 0·6 line in diameter, and which, although styled *papilla* or *colliculus*, is, in its normal state, nearly level with the retina, and even a little depressed in its centre. In the direct method, where the observer regards the illuminated non-inverted fundus oculi through an aperture in a concave mirror, without the aid of any extraneous lens, the great magnifying power of the cornea and humours of the patient's eye, gives to the papilla an apparent magnitude larger even than that of the pupil; but in this way, it cannot be well seen as a whole, and generally requires the eye of the observer to be brought

inconveniently near to that of the patient. Instead, then, of using the patient's eye as a powerful single microscope, in actual contact with the objects on the fundus oculi to be examined, and thus viewing them directly, it is better to obtain a smaller but more defined image, although an inverted and virtual one, of those objects, by converting the patient's eye for the time into the object-glass of a compound microscope, which we do by holding in front of it a thick convex lens. The image which we then see of the several parts of the fundus oculi is an inverted one, like that of an object examined with any ordinary compound microscope; the entrance of the optic nerve is seen towards the temple instead of the nose; the macula lutea appears to the nasal side of the optic nerve instead of the temporal, and a little below the level of the nerve instead of above it; while the principal trunks of the retinal vessels, instead of branching in the direction of the temple to embrace the macula lutea, seem to bend towards the nasal side of the eye. The apparent position, in fact, of all the objects on the fundus, viewed in this way, is the reverse of their real position.

The most important optical deception which arises from viewing the fundus in the indirect method, as well as the most puzzling to a beginner, affects the papilla. The student has probably heard, that the papilla, in the glaucomatus eye, is cupped or excavated, but to his view it appears quite the reverse, it appears rounded and prominent.

To comprehend clearly that this is an illusion, all that one requires to do, is to impress with the head of a pin, a small dimple on a bit of paper, and put this under a compound microscope, with the concave side of the impression uppermost. The same appearance will then be seen, which is presented by the papilla of the glaucomatous eye, namely, that of a rounded and protuberant surface.

This optical deception arises from the inversion which the image suffers by being viewed through the compound microscope. We judge that an object, viewed with a single eye, is convex or concave, solely by the manner in which

light is reflected from the body under examination. The light which falls obliquely on a convex surface illuminates that side which is nearer to the source of light; the side farther from it is in shade. The light which falls obliquely on a concave surface illuminates that side which is farther from the source of light; the side nearer it is in shade. Let the source of light remain in the same position, but invert the image of the object illuminated, so that the light which falls on the farther side of it may seem to fall on the near side, which is the case when we look through the compound microscope at the hollow on a bit of paper, or when we examine the optic papilla through the compound microscope formed for the occasion by the patient's eye *plus* the convex lens held in front of it; and both the dimple on the paper and the papilla, although they are actually cupped or concave, will then appear convex and prominent.

If, on the other hand, we turn the convex side of the dimple on the paper uppermost, and view it with the compound microscope, it appears concave. The inversion of its image causes the light which falls on its near side to appear as if it fell on its farther side, and thus the eye is subjected to a deception the reverse of the former, and from which it cannot free itself. If there be cases, then, in which the end of the optic nerve within the eye actually projects in a convex form, they will offer, when examined in the indirect method, the appearance of a cup or depression.

Such facts have long been familiarly known; the apparent transmutation of an intaglio into a cameo, or that of a cameo into an intaglio, under the compound microscope, being a common source of amusement, fully discussed by Sir David Brewster in his "Letters on Natural Magic, Letter V." Important as their bearing is on pathological examinations of the eye, they seem to have escaped the notice of ophthalmoscopists, till attention was directed to the subject by Dr. A. Weber, in a paper in the "Archiv für Ophthalmologie," Band II, Abtheilung I, Seite 141.

In a highly interesting communication in the same

journal (Band IV, Abtheilung II, Seite 1), Dr. H. Müller has directed attention to the normal, as well as to several diseased states, of the optic papilla.

His account of the entrance of the optic nerve into the eye, and the diagram which he gives in illustration, tally remarkably with the thirteenth figure in Mr. Bowman's "Lectures," and the corresponding explanation. From the statement and figures of these two observers, especially those of Dr. Müller, it may be gathered that the lamina cribrosa is normally somewhat concave towards the interior of the eye; that the fibres of the optic nerve, suddenly losing their white substance and dark outline, enter the eye on a level with the chorio-capillaris; that at this point the whole nerve, from the change which its fibres have just undergone, is considerably and rather suddenly reduced in thickness; that the fibres, bending more or less abruptly outwards, and spreading around, become clothed by the exterior or radially disposed layers of the retina; that the edge of the opening through which the nerve passes into the eye, as well as the fibres themselves as they traverse that edge, form a slight elevation or approach to a papilla, leaving in the situation where the trunks of the central vessels of the retina generally make their appearance, a small foveola.

Dr. Müller points out the difficulties which attend the anatomical examination of this depression, arising from the softness of the part, and its liability to change on being touched; and shows how these difficulties may best be obviated. He directs attention to the varieties which exist in different individuals; varieties in the depth of the depression, from 0·2 to 0·5 millimetre; varieties in its form and position, for it is not always symmetrical, and does not always correspond to the middle of the nerve, but is sometimes considerably nearer to the macula lutea, or has one portion of its edge more raised than the rest; varieties in the disposition of the vessels, for while the large trunks generally emerge from the middle of the foveola, one or more sometimes seek a passage for themselves close to the edge of

the chorio-capillaris, so as to make their appearance by the side of the nerve; facts, all of which should be carefully borne in mind by ophthalmoscopists.

In regard to abnormal prominence of the papilla, Dr. Müller shows, that this is likely to arise from an atrophied state of the exterior layers of the retina, a thickened condition of the primitive nervous fibres, as well as infiltration of the nerve by blood, inflammatory exudation, or new formations. He relates a case in which a concretion in the site of the lamina cribrosa caused a protuberance of the papilla. The very earliest stage of encephaloid tumour should show an abnormal prominence of the papilla.

On the other hand, intra-ocular pressure, and atrophy of the nerve, existing either singly or in combination, are the causes of abnormal excavation of the papilla. In cases of intra-ocular pressure, either simple, or combined with atrophy of the nerve, paracentesis, either corneal or sclerotical, is likely to produce a change in the depth of the excavation, sufficient to be recognized on ophthalmoscopical examination.

Morbid excavation of the papilla varies in depth, reaching in extreme cases to a millimetre beyond the level of the choroid. In such cases, the sides of the excavation are nearly perpendicular, or are even concave, and its edge, of course, impendent, so as partially, or even completely, to hide from view the course of the vessels as they pass from the bottom of the excavation and over its edge to the retina. In slight cases, the sides of the excavation are convex, and its form that of a funnel. The lamina cribrosa, under such circumstances, keeps its place, but in more advanced stages, it is pushed back, and the excavation is much extended laterally. Such extreme cases of expansion are not the result of uncombined atrophy of the nerve, but must arise from the supporting resistance of the parts being weakened by previous inflammation, whence they come to yield more readily to intra-ocular pressure.

* * * * *

ON THE DIFFERENT FORMS OF INFLAMMATION OF THE EYE CONSEQUENT ON INHERITED SYPHILIS.

(*Concluded.*)

By Mr. Jonathan Hutchinson.

(*Received April 24th.*—Ed.)

INFLAMMATORY OPACITIES IN THE VITREOUS BODY, LENS, ETC.

That in the form of inflammation of the eyeball which results from acquired syphilis the choroid is not unfrequently affected, has been placed beyond all doubt by the introduction of the ophthalmoscope. White patches of lymph may, by its aid, frequently be seen occupying various positions in the fundus of the eye, and their removal may often be effected by mercurial treatment. That these deposits are in the choroid coat is proved by the fact that the retinal vessels may usually be seen upon their surfaces. The inflammation however by no means confines itself to the choroid. A condition of general cloudiness is sometimes observed, which can be explained by no other hypothesis than that the delicate framework of the vitreous itself is the seat of inflammatory deposit. In fact, syphilitic ophthalmitis, although most frequently met with as a form of sclero-iritis, may involve any one or all of the different structures of the eyeball.* This, then, being the state of things in the acquired syphilis of adults, we might conjecture that nearly the same would be observed in the inherited disease of children;—and such is indeed the fact. Were it not that in them the choroiditis most often occurs, either with or

* To Dr. Jacob, of Dublin, much credit is due for the strenuous assertion of this doctrine many years ago.

after an attack of keratitis, I have no doubt that it would be much more frequently noticed. It is the hazy state of cornea which not seldom prevents an ophthalmoscopic inspection and also furnishes an apparent explanation of the impairment of vision. Every now and then, however, we meet with examples of choroidal disease of this type, in which either the corneæ have escaped or have cleared sufficiently to allow of examination. In such the disease may be traced through several distinct stages. The first of these is characterized by much dimness of vision, and by the presence of diffused patches of lymph, the retina being hazy and not unfrequently the vitreous also. After a while the sight improves and the patches are more defined, and in the third stage, that of cure, they are seen abruptly circumscribed and unattended by any general swelling of the adjacent tissue. The cases to follow exemplify chiefly the two latter stages of the disease. Although, as I shall have to show subsequently, the changes chiefly involve the choroid, yet I have no idea that they are always limited to it. Even if they were, it could scarcely be expected but that the overlying retina should also suffer in some degree. The degree of vision, which the subjects of most extensive choroidal disorganisation of this kind often retain, is however proof that the retina is but slightly and secondarily involved. (See Case III., Charles M.)

It must not be supposed that this form of disease is invariably of one type, for although in most instances such is the case, in a few remarkable deviations occur. The first case which I shall adduce is one in which the effusion was unusually extensive.

Case I.—Hereditary syphilis—Free effusion of lymph into the choroids of both eyes.

Frederic C. B., aged 17 months, was admitted in December, 1857. His mother stated that she had suffered from sores, followed by a rash, soon after marriage. Of her first

three infants, two had been born dead, and one had died soon after birth; the patient was her fourth, and the only one now living. At the age of three weeks he had "dreadful snuffles" and discharge from the nose, and although at first a fine baby, rapidly fell away to a miserably puny one. When three months old a rash broke out, and the mouth and nates became very sore. He was now treated by a physician for inherited syphilis, and had mercury freely given, with the result that all external symptoms passed away. When his mother brought him to the Ophthalmic Hospital, it was on account of her fear that he was going blind. She had noticed that his eyes rolled about much, and had fancied she saw "a white skin" on the left. The child now had a clear skin, but there were puckered scars at the angles of the mouth; his teeth were small, of bad colour, and very irregular, and the bridge of the nose was sunken. Even without the use of the ophthalmoscope, it was easy to see that a yellow white substance occupied the fundus of the left eye. Both irides were perfectly clear, and there was no sclerotic congestion. Light was borne well, and both pupils were fairly active. Atropine having been used, it was seen with the ophthalmoscope that an extensive layer of lymph was smoothly spread out over almost the whole of the central part of the choroid, comprising as much as could be brought into view at once. No vessels were seen on its surface, and the presumption, therefore, was that either it was upon the retina, or, more probably, that it had led to its destruction. Its smooth surface opposed the idea that it had been effused free into the cavity of the globe. In the right eye numerous white spots of lymph were seen, but the retina itself was not disorganised, and the entrance of the optic nerve was distinct and normal. The infant, as far as could be ascertained, was all but sightless. The iodide of potassium internally, and mercurial inunction were prescribed; but, owing to the mother's irregularity of attendance, the treatment was very imperfectly carried out.

On June 18th, six months after admission, the note states

that "he can see with the right better than he did, but only very imperfectly. In it the spots remain in *statu quo*, and are still plainly visible. In the left the large patch of lymph is more easily seen than it was, because it has become much whiter and more glistening. As to prominence and extent it is much as it was."

Case II.—Large cicatrices in the choroid of the left eye—Teeth and physiognomy typical of hereditary syphilis.

For permission to make use of this case, I am indebted to Mr. Dixon, under whose care the boy was. Charles H., aged 14, from Croydon. The lad was brought to the hospital on account of very defective sight in the right eye. His left eye had almost perfect sight, and he could read easily. On examination with the ophthalmoscope, numerous patches of various shades, from red and pink to white, were seen beneath the retina. One of these which was nearly circular, very much resembled the optic entrance, and excepting for the absence of vessels, might easily have been mistaken for it. By the margins of the white patches, were many small masses of pigment. The right eye diverged considerably, and he could see but very little with it. His mother stated that he was her only child, and that in infancy he had suffered severely with rash, thrush, snuffles and sores at the anus. These symptoms the medical man who attended him had said, were "due to disease derived from his father." His mother had had one miscarriage prior to his birth, but had never since conceived, although now for six years married to a second husband. The boy's aspect and teeth were most characteristic. He was of bad complexion, and had psoriasis on the face. The affection of the right eye was believed to date almost from infancy. As the choroidal changes were evidently those of long passed and now retrograde disease, Mr. Dixon did not adopt any treatment.

Case III.—Extensive cicatrices in the choroids of both eyes — Physiognomy and teeth suspicious — History suspicious.

Charles M., aged 20, a pale cachectic lad came under my care, with a written memorandum by Dr. Bader, who had previously seen him, "specific changes in both eyes; of six years' duration." The ophthalmoscope showed abruptly circumscribed patches, of a dead white colour, on various parts in the fundus of each eye. In both, the retinæ, where not involved by the patches, were very pale, and the optic entrances were irregular. The patient notwithstanding these changes, stated that he was still able to work as a shoe maker, though he could see but very imperfectly. His physiognomy was very suspicious, and his teeth, although by no means typical, were small and much worn down. There were fissures extending from the angles of the mouth. His father was dead, and was reported to have been a dissipated man, although as far as his mother knew, neither had he or she ever suffered from venereal disease. His mother had borne sixteen children, of whom he was the only one now living. An elder brother, who had died at the age of seventeen, had attended this hospital with "bad eyes," for many months.

Case IV.—Hereditary syphilis—Interstitial keratitis, with cataract, choroiditis and iritis—Complete loss of vision in one eye—Excision of the globe and subsequent examination.

Mary Ann R., single, aged 21, under the care of Mr. Poland, during 1859 and 1860. Her aspect was most characteristic of hereditary syphilis. Her teeth, both upper and lower sets, were horizontally notched and most extensively deformed, but the upper incisors (the test teeth), had been so much broken away by caries, that their vertical notches were scarcely recognizable. Her right globe had been excised by Mr. Poland, having been disorga-

nized and rendered sightless, by the results of syphilitic choroiditis, etc. It appeared from her history that she had had a cataract in this eye. At another hospital four operations had, she said, been performed for the removal of the cataract. (See Dr. Bader's Report below.) Her left cornea had opacities in its structure, and the pupil was adherent at two or three points. She could just manage to see to read, but only with difficulty. It appeared that she had had excellent sight, up to the age of 17, when an attack of inflammation occurred, in which both eyes were involved, and which rendered her blind for some weeks. She was the eldest living in her family. The first infant had died at three days' old. Two younger than herself, and aged respectively, 20 and 17, were living, and reported to have good eyesight.

The following account of the ophthalmoscopic examination and of the dissection of the globe after excision in this case, has been obligingly supplied to me by Dr. Bader. I am not aware that any other opportunity of examining after removal the exact state of the choroid, retina, etc., in this form of disease has been obtained. The report is, therefore, peculiarly valuable.

Report of the state of the eyes at the date of the excision.

Left Eye.—Portions of the cornea are slightly misty; its convexity is increased; the anterior chamber is large, the iris has the peculiar steel-blue colour; several posterior synechiæ exist but interfere only slightly with the activity of the pupil. With the ophthalmoscope the optic nerve is seen to be of a gray-pink colour, as is frequently observed in similar cases; the coats of the fundus are thinned, and staphylomatous near the optic nerve.

Portions of the choroid are sprinkled with minute black dots.

The sight of this eye, considering the state of the cornea,

pupil and fundus, is good. The eye is irritable from sympathy with its fellow.

The RIGHT EYE had no perception of light.

The iris could only be seen here and there, owing to the extensive opacity of the cornea, and, where seen, was in apposition with the latter. The greater part of the cornea was replaced by opaque tissue, portions of which were staphylomatous.

The tension of the eye was normal. It had occasionally been painful and red since vision was lost; and during the last month there had been constant pain and inflammation. The eye was excised by Mr. Poland and was immediately examined.

It was generally enlarged, but the transverse diameter exceeded the anterior one.

The anterior surface of the rotten and atrophied iris was adherent to the tissue which replaced the cornea, and was in apposition with the translucent portions of the cornea. The opaque thickened suspensory ligament was adherent to the posterior surface of the iris; the thickened, empty lens capsule adhered to the pupillary margin and to the tissue which replaced the cornea.

The vitreous space was occupied by a chocolate coloured turbid fluid, which consisted of debris of the framework of the vitreous humour, of blood-corpuscles and of a highly albuminous fluid.

The inner (vitreous) surface of the membrane, which intervenes between that part of the choroid known as the ora serrata and the vitreous space, was sprinkled with smaller and larger gray opaque patches of fibrous tissue. The choroid surrounding those patches and the neighbouring ciliary processes were œdematous.

The retina was in apposition with the choroid, it was slightly hazy, but admitted of a good view of the choroid. Minute grayish-white and yellowish opaque dots were seen in its substance, especially round the optic nerve. The optic nerve itself and the yellow spot appeared healthy.

The choroid appeared much thinned, and was of a pale brown colour. Its retinal surface was sprinkled with minute, black, roundish spots; these were most numerous on the portion situated between the equator of the eye and the ora serrata. Some of these spots projected from the choroid, but without affecting the surface of the retina. Portions of the latter remained adherent to the choroid when pealed off; this occurred chiefly to those portions of retina which were situated over or near the black spots.

Microscopic examination of the diseased Tissues.

a.—The choroid and the hexagonal cells.

The stellate pigment of the choroid and the large choroidal vessels offered no peculiarities.

Numerous clusters of cells were deposited round the capillaries and round those of the larger choroidal vessels, which are near the elastic lamina; these clusters had a roundish shape. The cells were of crown-glass colour and strongly translucent, being in size somewhat larger than blood corpuscles. Some of the blood vessels were entirely surrounded by cells, others only on the side nearest the elastic lamina. The latter had in many places disappeared, and the cells had passed through the gaps and occupied the place of the adjoining rods; these latter were in other places distorted, bent, etc., by similar clusters of cells.

In no instance had these cells passed beyond that part of the retinal framework.

The cells were in immediate apposition with each other, and separated from the surrounding parts by a thin layer of obscurely fibrillated tissue; the fibrillæ are lost sight of in the surrounding pigment of the choroid; in the retina they mingled with the rods.

The margins of the apertures in the elastic lamina of the choroid were thickened by a tissue similar in appearance and transparency to that of the lamina.

The hexagonal cells appeared normal, except those over portions of choroid which were occupied by clustered cells, and except those which immediately surrounded the apertures in the elastic lamina.

The former had lost their hexagonal shape; they were rounded off, and their pigment granules, instead of being of a pale brown colour as the remainder, appeared, some deep brown, others black; which, seen with the naked eye, gave the choroid the appearance of being sprinkled with black dots. The latter were heaped up round the apertures in the elastic lamina; they were round, and their pigment granules were black; at many places these cells had been displaced among the rods.

The clusters of cells were most numerous in the portion of choroid at the equator of the eye; the choroid round the optic nerve and yellow spot appeared healthy.

b.—The retina.

The framework of the retina, the rods excepted, appeared not changed, the latter were, as above mentioned, displaced, distorted, etc., by the morbid products emanating from the choroid. Many of the loculi, formed by what are called the radial fibres, were empty, others were occupied by healthy looking cells, others were filled with what appeared to be oil globules.

The greyish white and yellowish opaque dots, seen in the retina with the naked eye, were due to these accumulations of oil (?) globules in the loculi of the retinal framework.

The place of the delicate cell-layer, immediately beneath the optic nerve fibres, was occupied by an amorphous molecular greyish deposit.

The walls of the retinal blood vessels were thickened.

The layer of true optic nerve fibres which overlays the retina appeared healthy.

Case V.—Entire loss of vision in both eyes in a boy, the undoubted subject of hereditary syphilis—Ophthalmoscopic examination wanting.

Edward W., aged 10, of fairly healthy aspect, but pale. Bridge of nose rather broad, and some psoriasis about the skin of face. The incisor teeth were not notched, but of very peculiar form, being so much narrowed laterally, that they almost resembled canines. Their form was such that, despite the boy's healthy aspect, and the absence of notches, I at once suspected the true nature of the case.

The history was, that in infancy he had had purulent ophthalmia, after recovery from which, however, he enjoyed perfect sight, and retained it until a year ago. The left eye began to fail first, and subsequently the other; and after a few months he became, as he was when these notes were taken, totally blind. On inspection, the left pupil was seen to be much larger than the other, and both were very sluggish. There was not the least congestion about any part. His tonsils showed cicatrices, and were atrophied. His mother stated that she had had syphilis soon after her marriage, and had suffered severely from it.

I have unfortunately mislaid my notes of the ophthalmoscopic examination in this interesting case, and, not knowing the boy's address, am unable to complete the account. It may be conjectured that both eyes were in the condition illustrated by the left in Case I.

Case VI.—Numerous cicatrices in the choroid—Syphilitic physiognomy and teeth—History of infantile symptoms.

Charles D., aged 9, the second of three living children (a fourth having died), attended under Mr. Bowman's care during 1859. His mother denied all history of syphilis, but she did not appear to speak openly, and against her denial were the following facts. In infancy he had

suffered from bad and prolonged snuffles, attended with a rash in the body, for the cure of which the late Mr. Gossett ordered a small pill night and morning for many months (probably mercury). His mother stated that he took the pills almost continuously for nearly two years. His aspect was characteristic; nose very much sunken indeed: head large: teeth separate, narrowed, and slightly notched (quite typical).

In both eyes the ophthalmoscope showed numerous round patches in different tracts of the retina, of various sizes, quite white and glistening. Around many of them was seen a minute crescent of iron-black pigment. The patches were totally destitute of vessels. The retina on other parts was paler than normal, and as if thinned. In many large, ill-defined patches, slender networks of vessels, were seen coursing over surfaces destitute of pigment, and looking as if on paper. In each eye the cornea, lens, and vitreous body were perfectly transparent, and allowed of the deeper structures being very clearly seen.

The boy had great difficulty in directing his eyes, and there was a slight squint, but he could see sufficiently to have learnt his letters. He always looked sideways at anything he wished to see—never straight.

The history of his eyes was that in infancy he always had a peculiar rolling motion of the globes, and did not appear to see well. On account of this symptom many surgeons were consulted. No external inflammation of the eyes ever occurred. It thus appeared probable that the choroiditis dated back from early infancy, about the age when iritis usually occurs. Very possibly the boy may, in the sequel, suffer from keratitis.

Case VII.—History of hereditary syphilis—Numerous cicatrices in the choroid of the right eye.

Samuel B., aged about 12, of fair complexion, and characteristic aspect. His four upper front teeth were all

out; the canines and lower set presented as marked features as are ever seen in those teeth, being remarkably peg-shaped and notched. His mother had borne six children, of whom three had died, Samuel B. being the second of those living. When an infant, he attended the hospital on account of inflamed eyes; the attack, according to his mother's description, not having been one of purulent ophthalmia. He had at that time bad snuffles and a troublesome rash on the body, as well as a very sore mouth. His mother stated that she had contracted syphilis from her husband subsequent to the birth of her second child; and that, although treated by mercury, she had suffered afterwards from ulcerated sore throat and rash. All her children born since had had specific symptoms in infancy, excepting the last. The sight of the boy's right eye was all but lost. The ophthalmoscope showed many circular white patches, not a few of which had black dots in their centres. The patches were of glistening white and the choroid and retina appeared to be wholly disorganised and absorbed at these parts. My note, as to their condition, was taken July 8, 1859, unfortunately it is very incomplete, and I have no mention of the state of the other eye.

Case VIII.—Hereditary syphilis in a severe form—Keratitis in both eyes at the age of two years—Entire loss of sight in the left from choroidal disease at the age of twenty.

Emily H——, aged 23, bearing the physiognomy of hereditary syphilis most unmistakeably, came under my care in January, 1859. She had often been a patient at the hospital previously—indeed, almost the whole of her life. The bridge of her nose was sunken and broad, there were large cicatrices at the angles of the mouth, and many pits in the skin of the face and forehead, the skin itself being thick, oily, and of bad tint. Her teeth were small, peggy, of bad colour, and the upper incisors notched. Her tonsils were wasted, and she was somewhat hoarse. Her mother told me that she

was separated from her husband on account of his having several times given her venereal diseases, from which he had himself suffered very severely. Emily H. was the only one now living, and the eldest born. Two born subsequently had died (the first of hydrocephalus, under the care of Dr. Conquest; the second "of consumption," much wasted, at the age of nine months). In infancy she had purulent ophthalmia, and bad snuffles, a rash over the body, and a very sore mouth. She was treated for hereditary syphilis; and subsequently, when two years old, she was for three months under Mr. Scott's care at the Ophthalmic Hospital, for what, from the history would appear to have been keratitis. She recovered so far from this as to be able to learn to read, but her sight was ever afterwards much impaired. About eighteen months ago her left eye began to get rapidly worse. She had severe, long-continued, and deep-seated pain in the globe, and after the lapse of a few weeks was so blind that she could but just perceive the window. At the date of my note she could not detect the shadow of a hand passing before the eye. The cornea was bulged and hazy: the pupil dilated and fixed. She had been accustomed to see black muscæ floating before it, whilst she retained sufficient power of vision to perceive them.

Case IX.—Strabismus, Cataract and partially adherent pupil after an attack of Kerato-Iritis—Typical teeth.

Elizabeth G., aged 20, the youngest but one of a family of five. This patient was admitted on June 30th. With her right eye she could see to distinguish large objects, and could even read large print. Its iris was of steel-grey tint, concave and partially adherent at its pupillary margin, but fairly mobile. There was a semi-lunar portion of opaque membrane visible just within the area of the pupil in its lowest part. Her left eye was slightly divergent and prominent. Its pupil was wholly excluded by adhesions

and immobile, its area being occupied by greyish white glistening material, evidently the remains of disorganized lens.

The history given was, that she had enjoyed perfect sight up to the age of nine years, when during an acute attack of inflammation (keratitis?) she was blind for six months. This slowly passed off and left her sight much impaired. Her corneæ had now so far cleared that only a few interstitial films were visible. Her teeth, both upper and lower sets, were narrow, peg-shaped, and quite typical of hereditary syphilis. I had no opportunity of obtaining any history of her infancy, but my notes state that both Mr. Dixon and Dr. Bader fully agreed with me in considering that the diagnosis of hereditary syphilis was established.

Case X.—Cataract, with disease of the vitreous body and deposits in the retina—Physiognomy and teeth typical as regards hereditary syphilis.

Caroline G., aged 13, was admitted as an out-patient on October 14th, 1858. I saw her for the first time on March 10th, 1859. Her hospital letter had the following note on it, written by Dr. Bader, at the date of her first admission: "Vision failing for a year past. In the right eye numerous black patches on the retina and some around the entrance of the optic nerve. Some opacity of the lens. Cataract in the left eye." Fully recognising her diathesis, Dr. Bader had prescribed the bichloride of Mercury, in doses of one-twentieth of a grain three times a day.

On March 10th, 1859, her condition was much as when first described by Dr. Bader. There was a well-formed homogeneous, bluish cataract in the left eye, which according to her statement, had been present for several years. She was quite positive that it had formed within her recollection, and had not existed in infancy. The sight of the right eye was so defective that she could not see to read; she

expressed herself as quite certain that three years ago she could read easily, On ophthalmoscopic inspection of the right eye, black striæ were seen in the lens and in the vitreous humour. On the retina were many black spots of deposit.

This girl's teeth and physiognomy were most typical. Her face was covered with patches of psoriasis, and presented small pits. She had had small pox when nine years old.

Case XI.—Hereditary syphilis—Supervention of a cataract in the eye at three years of age—Iritic adhesions—Full history of syphilis, treated by mercury in the parents.

Sarah Ann C., aged 3.—This child was brought for the first time on September, 3rd, 1858. In her right eye was a well-formed blueish-white cataract. The pupil was fairly mobile. The other eye appeared perfectly healthy, and there was not the slightest congestion in either. Although well-grown and stout, the sunken bridge of her nose and some fissures at the angles of the mouth, at once attracted my attention. There was also a patch of psoriasis on one cheek, and all her central upper teeth were affected by that peculiar form of black caries, which I had previously noticed in one or two syphilitic cases. The lower teeth were, with one or two slight exceptions, free from caries. Her mother who brought her, was a woman of pale earthy complexion. On enquiry, I ascertained respecting the child, that in infancy she had suffered long and severely from snuffles, had had a very sore mouth, and sores at the anus, which lasted a long time, with also an eruption on the body. Her eyesight had been good in both eyes, until within a few months. She had several times had gumboils, and once her tongue had been very sore.

The mother told me that her husband was dead, that this was her only child, and that she had miscarried twice since its birth. Her own health, she said, had never been

good since marriage, and on my asking the direct question, she at once confessed to having had venereal disease from her husband prior to her confinement. The medical man who treated her, gave mercury to salivation, and subsequently a copious eruption appeared. The disease was contracted only about two months before her confinement. The infant was not subjected to any special treatment, and beyond the symptoms above mentioned, was not considered ailing. It was at the breast the whole time that her mother took the mercurial course. The mother still suffers from periosteal pains in the head, etc.

Atropine dilated the pupil very imperfectly, and it was then apparent that there were rather extensive adhesions of the inner border of the iris. Spots of uvea were seen on the surface of the lens, and in its structure were several masses of yellow chalk.

Case XII.—Cataract with iritic adhesions in the left eye of a girl known to be the subject of inherited syphilis.

Miss H., aged 14, came under notice in consequence of her elder brother being under my care for well-marked interstitial keratitis. Her father had lost one eye by syphilitic iritis before his marriage, and his eldest son had suffered severely from infantile symptoms, and presented the various indications of the diathesis;—notched teeth, etc., in a very well-characterized form. I requested to see his younger sister and she was brought at the next visit. She was three years younger than her brother, and the account was that in infancy she was fairly healthy. Her teeth showed horizontal notches, but no vertical ones, and there was little or nothing in her physiognomy to have excited suspicion. She could see but very little with her left eye. On inspection I found the lens in a condition of bluish-white haze. It was not densely opaque in any part, but sufficiently so to prevent the transmission of light. The pupil was fairly mobile, but there

were numerous small tags of adhesion between it and the capsule of the lens; the other eye was quite unaffected. I did not obtain any clear history of the attack of inflammation during which the changes described had taken place, but her mother said that in early childhood she was quite sure that both eyes had perfect sight. She believes that the changes in the left had occurred within the last few years.

Case XIII.—Extensive inflammatory changes in both choroids—Aspect and teeth of hereditary syphilis.

In April, 1860, Dr. Bader brought under my notice the following case, which he considered to be an instance of choroidal disease dependant upon hereditary syphilis. William N., aged 13, a boy of very dark complexion, and of markedly syphilitic physiognomy. His mother stated that he was her only living child, but she was herself so deaf that it was impossible to obtain any history of his infancy. His eyesight had been failing for many years, but he had never had any attack of external inflammation; his corneæ were both perfectly clear; his upper incisor teeth were characteristically notched; his vision was so far impaired that he could only read large print with great difficulty; his left eye was the worse of the two, and both were somewhat improved by the use of concave glasses. On ophthalmoscopic examination the optic entrances in both eyes were seen to be ill-defined; the vessels of the retina were small, and in the choroids were numerous small white patches, interspersed with deposits of pigment; the choroidal patches were not abruptly defined, but merged off gradually into the more healthy structure; the morbid conditions were most advanced in the left eye.

Case XIV.—Physiognomy of hereditary syphilis characteristically marked—History of a bygone attack of double interstitial keratitis—Choroidal changes in both eyes.

The notes of the following case are from those kindly

supplied to me by Dr. Bader. In it the choroidal changes were well marked. It is from the left eye of this patient that the drawing was taken. See plate X., fig. V.

Emily D., aged 18. She was a delicate girl up to the age of ten years; she has suffered much from headaches; at the age of 16 she had an attack of rheumatic fever. It was stated that her sight began to fail twelve years ago, and that seven years ago both eyes were inflamed, but as far as can be ascertained, by the patient's account, without implication of the retina. There was then, it was stated, merely the power of perceiving light, and this continued for some months, after which the inflammation subsided, and the sight gradually improved, the eyes being left in the condition described below. August, 1859, the patient bears the typical marks of hereditary syphilis; the teeth are stumpy, the corneæ hazy, the tonsils swollen, and the general aspect clearly indicative of the diathesis. It may be remarked that her sister presents similar characteristics. The corneæ of both eyes are slightly hazy and irregularly oval; the pupils are active but irregular; the irides have the characteristic steel-blue colour; with the *right* eye she can read the smallest type, and can tell the time on a distant clock; with the *left*, which was always the weaker and smaller, she can see, but cannot read, large type—she can see the face of the clock but cannot tell the time. It appears, by this examination, that she can see better with some of the lateral portions of the retina. In both eyes, with the ophthalmoscope, the lens and the vitreous humour are transparent. When the examination is not assisted by the lens numerous black muscæ appear to be floating in the vitreous space (this appearance is due to the oscillation of the eye bringing to view different pigment patches on the fundus). The optic nerves are small and slightly oval, greyish pink, hazy, indistinct, not well defined, and shade off into a whitish ring which separates the rest of the optic nerve entrance from the fundus. Passing through the left, a few retinal vessels only are dimly seen, but in the right they are more numerous.

The fundus round the optic nerve and at the yellow spot is hazy, red, and is sprinkled with irregular white and brown patches, and with minute pigment granules. On the lateral parts the large choroidal vessels are well seen, and here also the fundus is sprinkled with numerous large well-defined black patches.

General Comments.

In addition to the above fourteen cases I might quote several others, in which, in conjunction with keratitis, the choroid was undoubtedly affected. I omit these, however, because the opacities in the cornea were such as to prevent any satisfactory examination of the state of the deep structures. In the cases which I have adduced we have examples of choroiditis in ten; of deposit in the retina in two (Cases I and X); of inflammatory opacity of the vitreous body in one (Case X), and of opacity of the lens in five (Cases IV, IX, X, XI, XII). The patients varied in age from seventeen months to twenty years, and it would appear probable that the period of life most liable to attacks of heredito-syphilitic choroiditis, and its cognate affections, is the same as that in which interstitial keratitis is most frequent (See page 94). In six instances out of the ten in which the notes advert to this point, the patient was the eldest living in the family. Iritic adhesions were present in four or five of the cases. The patients were all members of different families and represented an aggregate of twenty-one living individuals out of forty births, giving an average to each family of five births and only two living. In these features the group corresponds with what was proved to be the fact as regards the subjects of interstitial keratitis.

Having given the cases in considerable detail, I need not here say anything further in the attempt to substantiate the diagnosis as to hereditary syphilis. As it is often impossible to obtain clear histories, we are not unfrequently in these cases obliged to trust to the physiognomy, and especially to

the teeth of the patient for data upon which to ground an opinion.

In several of the cases adduced, the reader's estimate of the diagnosis will depend to a considerable extent upon his opinion as to the trustworthiness or otherwise of these signs. I rely, however, chiefly on the fact that these instances of choroidal disease in young persons are almost never met with excepting in conjunction with notched upper incisors and syphilitic physiognomy, for support to my opinion as to their true etiology. The cases constitute so marked a group and so closely resemble each other, that if a clear history could be established in but half, there would be fair grounds for suspecting like antecedents in the others also.

Concerning Cases IX, X, XI, and XII, which afford examples of the occurrence of cataract in young persons with syphilitic history I may direct attention to the following facts:—in none was the cataract congenital; in all there were evidences of inflammatory changes in other tissues of the eye; in three of the cases the cataract was unilateral only, and in the one in which the disease was double the opacity had reached very different stages in the two eyes. These facts seem to point to the inference that the opacity of the lens was in all of a more or less inflammatory character. Its occurrence in one eye only, might be explained by supposing that the changes in the lens had been brought about by acute inflammation of the adjacent structures, and had therefore taken place only in the eye most severely affected. Were the lens liable to become inflamed in syphilitic children, without the intervention of any other morbid condition of the adjacent parts, and simply as the result of blood poisoning, the disease ought to be—as keratitis and choroiditis of this form are—symmetrical. It is much more probable, however, that the lens has very little tendency to take on inflammation, and that it almost never does so excepting secondarily. I have never yet seen an instance of cataracts in the eyes of a supposed subject of inherited taint whose eyes were otherwise sound.

ON THE SO-CALLED AQUO-CAPSULITIS.

One of the propositions with which this paper was commenced, was that a majority of the affections hitherto classed as "Aquo-capsulitis," were due to hereditary syphilis. Although all will admit that it is time that this term—alike barbarous in its terminology and erroneous in the anatomical theory which it suggests—fell into disuse; yet a short space may suitably be here granted to affections which have been so designated. It has been applied much too widely by many writers. If we were to allow it to include all cases in which the posterior layer of the cornea and the surface of the iris were simultaneously inflamed, a large class would be formed, and respecting a majority, indeed almost all, there would be little difficulty in proving a syphilitic history, either hereditary or acquired. In many cases of interstitial keratitis when the cornea has regained its transparency sufficiently to allow of inspection of the iris, the latter is seen to have partially lost its lustre, looking thin and of steel-gray aspect, and not unfrequently to have contracted a few slender adhesions. Although the severity of the disease has fallen on the cornea it is clear that the iris has also suffered. During the attack, however, the iris has been shut off from view, and the disease consequently designated as keratitis. In the cases of acute iritis in syphilitic infants, the cornea, as I have shewn, is but rarely implicated. The only cases to which the term "aquo-capsulitis" ought ever to have been applied, are those in which with finely-dotted deposit on the posterior layer of the cornea the structure of that tissue remains transparent and allows of a tumid and inflamed iris being freely inspected. Cases in which this conjunction of phenomena exists, do occur, but as far as my observation has gone they are very rare. I am speaking, of course, of cases in which the iritic affection and the inflammation of the posterior layer of the cornea are nearly equal in degree. In almost all cases of iritis from acquired syphilis, the sprinkled sand-like dottings behind

the cornea are present; but in these the stress of the morbid process is so evidently upon the iris that we never hesitate as to the designation. Now and then, however, after acquired syphilis the affection which supervenes in the eyes might fairly be called "aquo-capsulitis," the iris being affected but very slightly. Limiting the term under consideration as above proposed, I have seen but very few examples of the disease. About seven years ago I had under care for some weeks a girl of about 12, of Jewish family, in whom one eye was affected by slight iritis with punctate deposits behind the cornea. The corneal tissue never became opaque, and there was never any free effusion of lymph in the iris; the condition proved very intractable, but the opposite eye was never affected. There was no reason for suspecting hereditary syphilis. The following three cases comprise all that I have had under care at the Ophthalmic Hospital, and in one of these I did not see the patient during the attack, but only formed my opinion as to its nature by the permanent condition which had been left. In only one of the three was there the slightest reason to suspect hereditary syphilis, and I am therefore inclined to the opinion that cases of this type are for the most part not dependant upon that affection; further evidence is, however, needed on this point.

Case I.—Dotted deposit on the posterior layer of one cornea, with slight iritis—No suspicion of hereditary taint.

Alice G., single, aged 20, of clear complexion, rather pretty, and not presenting any trace of the physiognomy of hereditary syphilis, was admitted on June 9th, 1859. She had a perfectly regular set of teeth, of good form, and although pallid, considered herself in excellent health. Menstruation had always been regular. She was the sixth of her family, and all her brothers and sisters were reported to be in good health. The affection for which she applied consisted in a group of dotted deposits on the posterior surface of the right cornea. The largest were near the centre, and

but few extended higher than the equator of the eye, whilst downwards they occurred almost as low as the margin of the cornea. The pupil acted very sluggishly but was of normal size. Several tags of adhesion between the pupillary margin and the capsule of the lens were visible, but the iris itself was of good colour, and did not look as if it had ever been acutely inflamed.

From the history given it appeared probable that these deposits had been present for about two months. Six months ago the eye had been inflamed but the sight did not at that time suffer. The other eye had never been in the least affected.

The remedies prescribed were blisters and mercury, the latter in grain doses of calomel every night. Under these, in the course of three weeks, great improvement resulted, and the deposits were so far absorbed as to allow of her reading the smallest print. Still, however, although much diminished in thickness, the individual dots of deposit were, at the time of the girl's last visit very easily discernible.

Case II.—Iritis (slight) with punctate deposits in the posterior layers of the cornea in a healthy girl—Suspended menstruation—Improvement under the iodide of potassium.

Emily B., aged 16, was admitted on March 3rd, 1859. In both eyes exactly similar conditions existed, the posterior layers of the corneæ presenting numerous punctate deposits, and the irides being slightly discoloured, more especially near their free margins. The deposits in the corneæ were more numerous in their lower halves than their upper ones, and occupied nearly the same position as those in Case I, being, however, much less extensive. The attack had commenced two weeks before admission. The eyes were irritable, but there was no great intolerance of light. She had not menstruated for three months. With regard to her diathesis, my notes state "she is tall, well grown, florid, and fairly healthy looking; teeth good in every respect."

The treatment adopted consisted of the exhibition of the iodide of potassium in five-grain doses three times a-day. Under this she improved very decidedly. Menstruation occurred about a fortnight after her admission, and on March 24th the notes state that the corneal opacities had almost disappeared.

Case III.—Dotted deposits (permanent and earthy) on posterior layers of both corneæ—Evidences of past iritis—Hereditary syphilis probable.

Edwin R., aged 14, came under my care in June, 1859. On the posterior layer of both corneæ were numerous isolated dots of white deposit, which looked as if they consisted, in part at least, of chalk (Mr. Dixon quite agreed with me in this opinion). These had resulted from an inflammation which had occurred four years ago. There were also some slender tags of adhesion between the pupillary margin and the capsule of the lens. He had fair vision, and what of imperfection existed, was fully accounted for by the state of the corneæ. The condition of the latter was so peculiar and illustrated so well the disease under consideration that I had a sketch taken (see Plate X, Fig. 2). The boy was very decidedly of syphilitic physiognomy as was also his elder brother who came with him. Unfortunately I had no opportunity of obtaining any history of his infancy. As the changes were undoubtedly permanent no treatment was adopted.

TINEA TARSI—FALLING OF THE LASHES AND MUCO-PURULENT OPHTHALMIA, AS CONNECTED WITH HEREDITARY SYPHILIS.

The wish to notice in this paper all the affections of the eye and its appendages, which I have hitherto observed in connexion with inherited syphilis, induces me to group together the above-named. They are all alike in this, that they are by no means peculiar to the subjects of hereditary

taint. Of iritis, choroiditis, kerato-iritis, and interstitial keratitis, as met with in infants and young persons, I venture the assertion that in a vast majority of instances, they are directly due to that cause. With tinea tarsi, etc., however, it is wholly different, they are very commonly simple affections, and very rarely syphilitic. To take first—

Tinea tarsi.—When this disease is of syphilitic origin, whether inherited or acquired, it may usually be distinguished by the circumstance that small abruptly-margined patches of excoriation extend away from the lashes into the cutaneous surface of the lids. These patches are irregular in shape, and are most commonly observed near the angles. They give to the lids an appearance of great irritation and soreness. Again, syphilitic tinea tarsi is apt to be very obstinate in treatment, unless constitutional specifics are employed. It is interesting to remark, that when tinea tarsi, in a severe form is not syphilitic, it is still usually a secondary phenomenon to some specific disease. Measles is undoubtedly a most frequent cause; scarlet fever and small-pox are so more rarely: it is by no means rare, and often complicates the form of keratitis about to be described. The following may be cited as a good example:—

Case of obstinate tinea tarsi following a syphilitic rash in a young infant.

A pallid but fairly stout boy, aged 2, was brought to me at the Metropolitan Free Hospital in June, 1858, on account of what looked like catarrhal ophthalmia with severe tinea tarsi. The tinea had existed for eighteen months, the mucous discharge and conjunctival congestion for only a fortnight. Had the disease followed the measles, I asked, "No," was the reply, "but he had a bad rash out on his body before the eyes came sore." There was that in the way the mother spoke of the rash which made me think that she wished the term to convey something of particular and

mysterious importance, and having observed also that the boy's nose was sunken, and that the little excoriated patches on the edges of the lids were present, I at once asked as to syphilis. A full history of the disease both in the mother and infant was at once freely given, and the requisite remedies were accordingly prescribed.

Falling of the lashes.—I need say no more of this symptom than that it occasionally happens in syphilitic infants. It has, no doubt, the same relation to the original disease as the alopecia which is not unfrequently observed in adults as a secondary symptom.

Muco-purulent Ophthalmia.—The reason why purulent ophthalmia is so common in syphilitic infants is, no doubt, to be found in the fact that the mothers of such usually suffer from syphilitic leucorrhœa. The contagion is usually conveyed to the infant's eyes during birth, and the disease is to be regarded as a local one. I have, however, seen so many instances of muco-purulent ophthalmia beginning in infants at intervals of a month or two after birth, and in association with other symptoms of inherited syphilis that I cannot but think that this form is often of constitutional origin. The conjunctivitis is probably of the same character as the inflammation of the Schneiderian membrane of the nose, to which the snuffles, nasal discharge, etc., is due. It is rarely so acute as the true purulent ophthalmia.

PARALYTIC AFFECTIONS OF THE MUSCLES OF THE EYE.

(*continued*)

By Dr. John S. Wells.

(*Received April 5th.*—Ed.)

PARALYSIS OF THE OBLIQUUS SUPERIOR.

This, the last paralysis of the muscles moving the eyeball of which we have to treat, illustrates, perhaps better than any other, the correctness of the rules by which we are guided, and the value of thoroughly understanding the actions of the muscles of the eye in order to unravel the complication of symptoms, objective as well as subjective, called up by the paralysis of these muscles.

The deviation of the optic axis in paralysis of the *trochlearis* is so slight, that although the diagnosis may be made from the objective symptoms alone by one well conversant with this subject, many errors would undoubtedly arise if we had not fortunately in the subjective phenomena (the *diplopia*) so true and controllable a guide that we cannot very easily fail in our diagnosis. Although such eminent observers as Sezokalsky, Ruete, Bowman, Donders, etc., had made many interesting researches in connection with this subject, it was reserved for von Graefe to make the formal diagnosis of the paralysis of the superior oblique, and to base it upon clear and uncontrovertible symptoms.*

Let us now turn to the paralysis of the superior oblique of the left eye, and follow in our examination, the course which we have before defined, viz., an examination, first of the objective symptoms, and then of the *diplopia* presented

* *Vide* his admirable paper upon "The Physiology and Pathology of the oblique muscles of the Eye." Archiv für Ophthalmologie, vol. i, part 1.

by such a patient. He generally comes to us with the complaint that things in the lower half of his field of vision,—the floor, steps, etc.,—appear vacillating and double. At the first glance, perhaps, we do not notice any deviation in the optic axes. We direct the patient to look at an object held at a few feet distance, and find that as long as we move it in any direction *above* the horizontal median line both eyes follow it accurately, and are adjusted upon it; if we hold it in the median line, a very slight deviation of the affected eye (in our case the left), in an upward and inward direction, becomes manifest, and shows itself more and more distinctly the further the object is carried into the lower half of the field of vision, more particularly if we move it at the same time towards the right side of the patient. Upon closing the right eye the left makes an excursion downwards and outwards, to bring its optic axis to bear upon the object; the right eye making a greater associated movement downwards and inwards (to the left). There will also be an erroneous projection of the field of vision towards the side of the affected eye, or rather downwards and outwards; for if we tell the patient to strike quickly at the object with his hand, whilst his right eye is closed, he will aim too low, and too much to the left of the object, and thus miss it.

The difference in the height of the *corneæ* of the two eyes beneath the horizontal median line becomes more evident as the object is moved towards the right, the lateral distances here decrease; both the difference in the height of the *corneæ* and their lateral deviation decreases when the object is moved to the left side; but when it is carried vertically downwards the lateral deviation (convergent squint) increases.

These phenomena are easily explained when we call to mind the action of the Superior Oblique muscle. As its action is not called into play in order to bring about any of the movements of the eyeball *above* the horizontal median line, its default (from paralysis) will not be evident as long as the object is kept in the upper half of the field of vision, and consequently both optic axes will be accurately adjusted

upon it. Different will it be however, when we move the object into the lower half of the field of vision, for as the action of the *trochlearis* consists in moving the *corneæ* downwards and outwards, the eye will, when this muscle is paralyzed, lag behind in an upward and inward direction, giving rise to a convergent squint.

In conjunction with the *R. inferior*, the *trochlearis* moves the eye *vertically* downwards, if the latter muscle is paralyzed, the *R. inferior* will move the eyeball downwards, but, at the same time, inwards; thus causing a convergent squint, which increases in proportion as the eye is moved downwards.

The parallelism of the vertical meridians of the two eyes will be destroyed, and that of the left eye will be inclined outwards in consequence of the unopposed action of the *R. inferior*.

Upon closing the healthy right eye, and testing the mobility of the left, we, at the first glance, might deem it almost undisturbed; for it can be moved in the horizontal median line to the right and to the left, above this line vertically upwards or into the diagonal positions: if we now carry the examination into the lower half of the field of vision, and ask ourselves in what position of the eye will the inefficiency of the paralyzed *trochlearis* become most unmistakeably apparent, we must answer, in the diagonal position, downwards and inwards (to the right in our case). In this direction we shall find the mobility positively lessened, as the action of the *trochlearis* is essentially necessary for this position, for we know that the *R. inferior* forfeits more and more of its action in lowering the *cornea* in proportion as the eye is moved inwards. The effect of the superior oblique upon the height of the *cornea*, on the other hand, decreases as the eye is turned outwards, in this direction it exercises most influence upon the V. M., but the difference in the parallelism of the V. M M. of the two eyes does not obtrude itself upon our perception so much as the difference in the height of the *corneæ*.

As the differences in the movements of the two eyes are but small in slight cases of paralysis (*paresis*) of the *trochlearis*, we gladly avail ourselves of the *diplopia* to assist our diagnosis, for by its aid we can appreciate differences in the position of the optic axes which might easily escape our objective examination.

As the squint is convergent, the *diplopia* will be homonymous, and as there is a difference in the height of the *corneæ*, the double images will show a difference in altitude. As the optic axes are fixed upon the object in the upper portion of the field of vision, the *diplopia* will be absent here, but it becomes apparent generally already in the horizontal median line, and the double images increase in proportion as the object is moved downwards. Owing to the convergence of the left eye, the rays from the object fall upon a portion of the *retina* internal to the *macula lutea*, and the image is consequently projected outwards (to the left), giving rise to homonymous *diplopia;* but as the left eye stands higher than the right, there will likewise be a difference in the height of the double images, for the rays from the object fall in the left eye upon a portion of the retina *above* the *macula lutea*, and the *pseudo*-image is therefore projected *beneath* that of the healthy right eye. As the convergence becomes greater (owing to the uncontrolled action of the *R. inferior*), the more the eye is moved downwards, the lateral differences in the double images will increase in this direction, but diminish when the eye is moved to the right or left side. In conformity with the fact that the Superior Oblique exercises most influence upon the height of the *cornea* when the eye is moved inwards, the double images will, in paralysis of this muscle, increase in height in this direction, but decrease as the object is moved over to the left of the patient.

We next turn our attention to the *inclination* of the double images, gaining through this also a valuable aid for our diagnosis. When the *trochlearis* is paralyzed, the *R. inferior* can, in all the movements of the eye below the horizontal median line, exercise uncontrolled sway over the

V.M., and incline it outwards; the parallelism of the V.MM. of the two eyes is in this way destroyed, and they *diverge* at the top, the double images appearing to the patient to *converge*, as in Fig. I.

Fig. I.

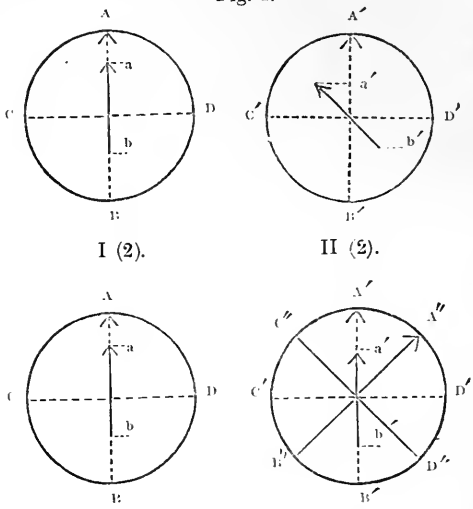

I (2). II (2). I (1). II (1).

I (1.) The healthy right eye, whose V. M. (A B), is vertical.

II (1.) The left eye, affected with Paralysis of the Superior Oblique, in consequence of which the *R. inferior* exercises uncontrolled influence over the V.M. and inclines it outwards (A″ B″). The parallelism of the V. MM. of the two eyes is consequently destroyed, for the V.M. of the left eye (A′ B′ II (1)) instead of being vertical is inclined outwards (A″ B′), so that the V.MM. of the two eyes *diverge* at the top (A B I (1) and A″ B″ II (1)).

The image (a b) of a vertical object falls in the right eye in the V.M. (I (1) a b).

In the left eye, however, the V.M. is inclined outwards (A″ B″), therefore the image (a′ b′) will not in this eye fall in the V.M., but in the *upper and inner* (A″ C″) *and lower and outer* (B″ D″) quadrants of the *retina*, the *pseudo*-image appears therefore to the patient to be inclined to the right and to converge at the top towards the image of the right eye. (a b I (2) and a′ b′ II (2)).

As the *trochlearis* exerts most influence upon the position of the V.M. when the eye is moved downwards and outwards,

the difference in the inclination of the double images which arises from paralysis of this muscle must become more and more evident as the object is moved over from the right to the left side of the patient, the differences in height of the images at the same time decreasing, the reverse will be the case when the eyes are moved from the left to the right.

The lateral differences in the double images are greatest when the object is moved vertically downwards and diminish towards either side.

A curious phenomenon may show itself when the object is carried far down in the lower half of the field of vision, viz., that although the *cornea* of the affected eye still remains *higher* than that of the healthy eye, the *pseudo*-image, instead of being *beneath* that of the right eye, may now appear *above* it. I have before mentioned, when speaking of the paralysis of the *R. internus,* that this apparent anomaly is brought about by an excessive inclination of the V.M., and a consequent dislocation of the quadrants of the *retina;* if we remember this, we have no difficulty in understanding this phenomenon.

On account of the paralysis of the *trochlearis,* the left eye, when the patient looks downwards, lags behind in an upward and inward direction, as has been before pointed out; the rays from the object fall, therefore, in the upper and inner quadrant of the *retina,* and are projected outwards and downwards.

Fig. II will perhaps better explain what next takes place when the look is carried still further downwards.

Let I represent the *retina* of the healthy right eye. The vertical meridian (A B) and the horizontal meridian (equator) (C D) divide it into quadrants.

Fig. II.

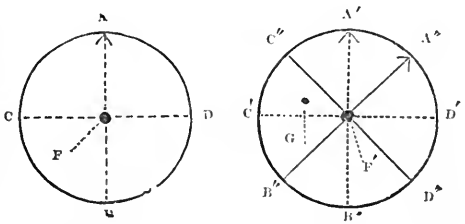

I. II.

Let II represent

the *retina* of the left eye, which is affected with a paralysis of the Superior Oblique. A′ B′ is the vertical, C′ D′ the horizontal meridian. If the object be held slightly in the lower half of the field of vision its image will fall in I upon the *macula lutea* F, for the V. and H.MM. retain their normal positions in this eye; in the left eye it will, however, be different, for on account of the paralysis of the *trochlearis*, this eye stands higher and more inwards than the right eye, and the image (G) of the object falls, therefore, not in the *macula lutea* (F′ II), but to the inner side of the yellow spot and above it, viz., in the upper and inner quadrant of the *retina* (II A′ C′ G), and the *pseudo*-image is, therefore, projected to the left and *beneath* that of the healthy eye. These relations will be, however, completely changed when we carry the object far down, for the left eye will, in the attempt to follow it, be moved downwards by the unaided action of the *R. inferior*, which must at the same time bring about a great inclination of the V.M. (over which the *R. inferior* now exercises uncontrolled sway), and the V.M. is inclined outwards (A″ B″ II), and the H.M. lies in C″ B″, but the image (G) lies now, in conformity with these changes in the meridians, no longer in the upper and inner quadrants of the *retina* (A′ C′ II) but in B″ C″, the *lower* and inner quadrants; and the *pseudo*-image will, therefore, be projected to the left and *above* that of the right eye.

Another exceedingly interesting phenomenon is met with in paralysis of the Superior Oblique, viz., the *pseudo*-image appears to the patient to be nearer to him than that of the healthy eye. My friend Dr. Michaelis first noticed this, and von Graefe (Archiv f. Ophth., vol. ii, part 2, p. 321), supposes it to be owing to a dislocation backward of the turning point of the eye, which is caused by the retrahent action of the *recti* muscles, which, being freed from the antagonistic opposition of the Superior Oblique, can pull the eyeball more into the orbit. The following facts appeared to favour this supposition:—The affected eye appeared sometimes to lie deeper in the orbit than the healthy eye, when pressure was

made upon the healthy eye its image receded more and more *towards* the patient, and, at last came into the same line with the *pseudo*-image (which, as we have stated, appears to lie *nearer* the patient); the lateral distances, as well as those in the height and inclination of the double images, remained unaltered as long as the pressure was uniform. If the pressure was exercised upon the affected eye, its image could be made to approach still nearer to the patient. Von Graefe thinks now however, that this symptom is not sufficiently explained by the retrogression of the turning point of the eye; for were this the case, we should find in cases of paralysis of the *oculomotorius* (where the dislocation forward of the turning point of the eye evidently exists), that the image of the affected eye would lie further from the patient than the other; this is, however, not the case. At present, therefore, we must abandon the attempt of explaining this phenomenon.

The line which divides the field of single vision from that of the *diplopia* does not run horizontally, but obliquely downwards from the right to the left. The reason of this is evident. The Superior Oblique acts most upon the height of the *cornea* when the eye is moved inwards, consequently the deviation of this eye, and its accompanying *diplopia*, must show itself sooner when the patient looks inwards than when he looks straight forward or outwards. The line which divides the field of single vision from that of the *diplopia* must, therefore, rise towards the right eye, above the horizontal line, but descend towards the left side, as in Fig. III.

Fig. III.

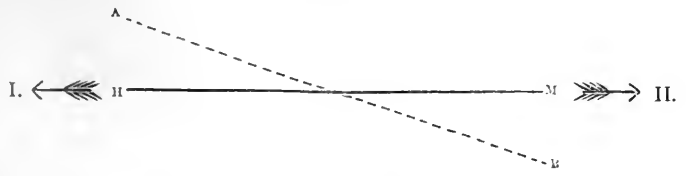

I. The field of vision of the right eye.

II. That of the left eye affected with paralysis of the *trochlearis*.

H.M. The horizontal median line.

A.B. The oblique line which divides the field of single vision (above) from that of the *diplopia* (below).

The carriage of the patient's head is peculiar. As the *diplopia* arises when the eyes are turned downwards, the patient bends his head forwards, thus bringing the object as much as possible into the upper half of his field of vision, and so he manages to lessen the territory of the *diplopia;* but he also inclines his head sideways to the right, and thus succeeds in bringing the object more into the left half of his field of vision, which must be of manifest advantage to him, as we have seen that the *diplopia* arises sooner in the right half of the field of vision.

As we have already explained the action and mode of application of prismatic glasses, and the difference which exists in their employment according as our intention is merely to free the patient from the annoyance of the *diplopia,* or to cure the paralysis by the gradual exercise of the affected muscle, we can go over at once to the consideration as to, how we are to apply prisms in our case?

As the left eye deviates upwards and inwards, the retinal image of the object will fall upon a portion of the *retina* above, and to the inner side of the *macula lutea;* if we, therefore, apply a prism with its base diagonally downwards and outwards, the rays will be refracted proportionably to the strength of the prism, downwards and outwards, and thus correct the deviation upwards and inwards. As the difference in the height of the double images is greater than their lateral distances, the base of the prism must be inclined more downwards than outwards.

As it is not always easy to establish the diagnosis of the paralysis of the *trochlearis* when the deviation is slight, and the patient obtuse, and but little susceptible of the accurate appreciation of the differences in the double images, it is important that we should consider whether we could easily

confound the paralysis of this muscle with that of any other.

It was seen that when the patient looked at an object held in the horizontal median line, or in the lower half of his field of vision, his left eye lagged behind in an upward and inward direction.

This could only be brought about by the paralysis of a muscle whose action is to pull the *cornea* downwards and outwards, or by the contraction of a muscle whose office consists in moving the eye upwards and inwards.

Could we confound it with a paralysis of the *Rectus inferior?*

This muscle certainly moves the eye downwards, but at the same time inwards, and therefore if paralyzed the eye would deviate from the object in an *upward* and *outward* direction, giving rise to a *divergent* squint with *crossed* double images; but this does not at all coincide with the symptoms laid down as showing themselves in paralysis of the *trochlearis,* for in our case the eye deviates *upwards* and *inwards,* the squint is convergent, and the *diplopia* homonymous.

We have however in the double images, and particularly in the differences in the direction in which their height and inclination increase, another important guide for our differential diagnosis.

When treating of the paralysis of the *R. inferior* we found that the differences in the height of the double images became greater as the eyes were moved outwards (to the left), their inclination decreasing in this direction and *vice versâ,* now just the reverse of this happens in paralysis of the superior oblique.

We cannot very well mistake it for a contraction of the *R. superior,* for, apart from the differences in the double images, the deviation of the optic axis would not show itself just in those movements in which the *R. superior* is relaxed (below the horizontal median line), and be wanting in the movements of the eyes in the upper half of the field of vision,

in those movements in fact in which the *R. superior* is more or less called into play.

After a paralysis of the superior oblique muscle has existed for a longer or shorter space of time, it frequently happens that a secondary contraction of the inferior oblique is brought about. This event not only complicates the diagnosis and somewhat changes the symptoms of the paralysis, but also clouds the prognosis very materially, for even although we should succeed in curing the paralysis, the changes in the muscular structure of the inferior oblique will not undergo a restitution *ad integrum*.

In these cases an operation is often called for in order to free the patient from the very annoying and confusing *diplopia* which now pervades, more or less, the whole of his field of vision.

If a secondary contraction of the inferior oblique is superadded to a paralysis of the *trochlearis*, the patient would present the following symptons:—

The *cornea* of the affected (left) eye stands higher than that of the right eye throughout the whole of the field of vision. Below the horizontal median line there is a convergent squint, owing to the paralysis of the *trochlearis* (whose action is to move the *cornea* downwards and outwards); above the horizontal median line the squint becomes divergent, for in consequence of the contraction of the inferior oblique, the eye is pulled more upwards and outwards.

If, while the object be held slightly in the lower half of the field of vision, the right eye is closed, the left will make an excursion *downwards and outwards*, in order to bring its optic axis to bear upon the object, but when the latter is carried into the upper half of the field of vision and the experiment repeated, the eye will move *downwards and inwards*.

Below the horizontal median line the *diplopia* was shown to be homonymous, the image of the left eye being also *below* that of the right; above the horizontal line the double images become *crossed*, as the squint is here divergent, the

pseudo-image appears however still *beneath* that of the healthy eye.

In accordance with the action of the inferior oblique the differences in the height of the double images will increase when the eyes are moved towards the right side of the patient, the inclination of the images decreasing in this direction, towards the left side these differences will be just reversed. Owing to the hyper-action of the inferior oblique the V.M. is turned outwards, the parallelism of the V.MM. is therefore destroyed, and they diverge at the top; the images being crossed appear to the patient also to diverge at the top, so that the *pseudo*-image seems to be inclined towards his right side.

We are guided in the operative treatment of these cases by the same rules as are applicable to those in which we perform tenotomy for the purpose of freeing a patient wholly or partially of *diplopia*. As I shall have to treat fully of this in my next paper, I will defer till then the consideration of this part of our subject.

In order to prepare some of my readers for every contingency which may arise with regard to *diplopia*, I must be allowed to call their attention to a state of the *retina* which we meet with in some cases of squinting, and an ignorance of which might lead them either to doubt the assertions of the patients, or perhaps even the validity of the rules which we have laid down with respect to the different forms of *diplopia*.

The abnormality to which I would call their attention is *incongruence of the retinæ*. We find in these cases a very peculiar state of the double images, for instance, in a *strabismus convergens* the *diplopia* should be homonymous (the reasons for this have been already stated), and the distance between the double images should correspond to the degree of deviation of the optic axis; we find these conditions, however, completely changed in an incongruent state of the *retinæ*. Even if the double images are homonymous in a convergent squint, the distance between them is not at all commensurate with the size of the squint; or, on the other hand, we may have a *convergent* squint with *crossed* double images, or a *divergent* squint with *homonymous diplopia*. We must not, however, when we meet with such anomalies in the *diplopia*, at once attribute them to an *incongruence* of the *retinæ*, but must examine whether the patient has not perhaps, an abnormal curvature (facets, etc.) of the *cornea*, irregularities of the refracting media, luxation of the lens, etc.; for these might act as a prism, and cause refraction of the rays of light.

We must also distinguish cases of real incongruence of the *retinæ* from

those in which, owing to long continued *strabismus*, the most sensitive portion of the *retina* has become transposed to a portion of the *retina* (internal or external) to the *macula lutea*.

According to Von Graefe, the cases of incongruence of the *retinæ* may be divided into two categories.*

I. The healthy eye *fixes* the object with its centre, upon closing this the affected eye does not adjust its *macula lutea* upon the object, but a point of the *retina* lying internal (or external) to the *macula lutea*: this point acts, in fact, as a substitute for the centre of the *retina*, prevailing over it in the energy of perception, but being also *identical* in relation with the *macula lutea* of the healthy eye.

II. Each eye, when tried separately, *fixes* the object with the *macula lutea*; but these two points are not identical, for when both eyes are opened *diplopia* arises.

Let us first suppose this in relation to convergent squint.

When both eyes are open, a point lying internal to the *macula lutea* will be identical with the *macula lutea* of the healthy eye, and the vertical line which divides the *retina* into a right and left half does not (as in the normal eye) fall in the centre of the *retina*, dividing it into two equal halves, but is situated to the inner side of the centre, so that when rays from an object fall upon the *macula lutea*, or even portions of the *retina*, lying more or less internal to it, these points will act as if portions of the *retina* external to the *macula lutea* had been stimulated by the rays, for the image is projected *inwards* across that of the healthy eye, and thus it comes to pass that although the squint is convergent the double images are crossed.

The case will be reversed when the vertical line lies to the *outer* side of the centre, for then the *macula lutea* and certain parts of the *retina* lying to the outer side of it will act as if they laid excentrically to the inner side of the yellow spot, and will consequently project images *outwards*, so that in this case we may have a *divergent* squint with *homonymous diplopia*.

That the vicarious point of identity in the affected eye is not that which enjoys the best vision, is sufficiently proved by the fact that when the healthy eye is closed, the affected eye adjusts its centre upon the object and does not deviate to the right or left side of the object, as would be the case if a lateral excentric portion of the *retina* enjoyed a higher amount of vision than the *macula lutea*.

It very frequently happens that after a *strabismus convergens* or *divergens* has existed for some time, the faculty of *mutual vision* with the other eye (Gemeinschaftliches Sehen) is extinguished in the squinting eye in a portion of the *retina* lying horizontally inwards or outwards of the *macula lutea* (according as the squint is convergent or divergent); if we then apply a prism with its base, in the first case inwards, in the second outwards, we fail to arouse *diplopia*.

We have however in these cases only to apply the prism with its base

* Archiv, vol. i. part 1, page 82; part 2, page 294. Also two cases in Alfred Graefe's Motilitäts störungen des Auges, p. 228.

vertically upwards or downwards. If it be a convergent squint with incongruence of the *retinæ* the double images will now show not only a difference in height, but be crossed, or even if the double images are homonymous, their lateral distances will be quite disproportionate to the amount of the squint.

We find a convergent squint with the point of identity with the *macula lutea* of the healthy eye lying *internal* to the yellow spot, of far more frequent occurrence, than that this point lies external to the yellow spot, giving rise to divergent squint and homonymous *diplopia.*

At present no satisfactory explanation has been given of incongruence of the *retinæ;* Von Graefe has not found it so rare an occurrence as he at one time supposed it to be. If I mistake not, he has met with it in about *one-third* of the cases of *congenital strabismus concomitans.*

By trying prisms of various strength we may sometimes succeed in ascertaining whereabouts in the affected eye the abnormal point lies which corresponds in identity with the *macula lutea* of the healthy eye: for instance, in convergent squint with crossed double images we apply a prism with its base inwards before the squinting eye, and increase the strength of the prism until the distances between the double images become less and less, and they are at last melted into one image. Frequently, however, the position of this abnormal point of identity is not to be established (it is *ideal*), for we may, with the aid of prisms, succeed in bringing the crossed double images somewhat nearer to each other, but we cannot unite them or change them into homonymous images.

It is evidently of the greatest importance to ascertain before the operation of tenotomy whether or not incongruence of the *retina* exists, for its presence will most likely cause us to modify, or perhaps even abstain altogether from, the operation.

Are we ever to operate in cases of incongruence of the *retinæ?*

Before we decide upon this question and upon the method or purpose of the operation, we must very carefully examine whether or not the patient possesses the faculty of uniting the double images (this, of course, we discover by the aid of prisms). This experiment is the more necessary as we often find that together with incongruence of the *retinæ* there often exists very great antipathy to single vision. The degree of capability of uniting the double images will guide us of course in operating.

We operate generally for one of two reasons.

I. For cosmetic reasons.

In this case we must be particularly careful not to call up *crossed* double images, for these would be exceedingly confusing and annoying to the patient. Let us, for instance, suppose that a patient suffers from a convergent squint of $1\frac{1}{2}$–2 lines upon the left eye, and that an incongruence of the *retina* exists in this eye, shown by the *crossed* double images which arise when a prism is applied with its base vertically upwards or downwards.

On applying the base inwards no *diplopia* is caused, owing to the extinction of *mutual vision* in the inner horizontal portion of the *retina.* If we

however, apply a prism of very slight strength (2°–3°), with its base outwards *crossed diplopia* is at once called up. Were we in this case to operate in order to free the patient of the deformity of squinting, we should subject him to the annoyance of crossed double images, the suppression of which would be exceedingly doubtful and improbable, for we find that it is far more difficult to suppress crossed than homonymous double images. In fact, it would be very likely that in order to render the double image less confusing by driving them further from each other, the left eye would make an excursion outwards, giving rise to divergent squint, which would certainly be more unsightly than a convergent one; or, perhaps, in order to unite the images the *R. internus* would be contracted and a convergent squint again arise. In this case, therefore, particularly if the squint be but slight, it is better to abstain from an operation, different however would it be if the *diplopia* was homonymous, and the double images would be placed further from each other by the operation.

II. We may operate for the purpose of bringing the rays from the object upon that excentric lateral point of the *retina*, which is identical with the *macula lutea* of the healthy eye. This point of identity is generally however placed so very far to the inner or outer side of the *macula lutea* (in some cases it may even be *ideal*) that we would have to bring about a very great *strabismus convergens* or *divergens* in order to bring the rays upon identical portions of the *retina*.

As the cases of incongruence of the *retinæ* differ very greatly, we can only lay down general rules with regard to the treatment, leaving it to the operator to modify them in accordance with the exigencies of the case.

If there is a very *great difference* between the distances of the double images and the deviation of the optic axis, we must generally despair of the patient's uniting them even when the images are brought accurately over one another.

It is best, therefore, to operate for the squint and place the optic axis straight, for this will be an improvement in a cosmetic point of view, and will also be advantageous for the act of vision, and the double images will on account of their great distance (and more particularly if they are homonymous) not annoy the patient at all.

We need be still less tied by the consideration of the *diplopia* if this only shows itself when a coloured glass is placed before the patient's eye. Let us suppose, for instance, that a patient comes to us with an insufficiency of the *R. internus* of the left eye, he may perhaps be able to fix both optic axes upon the object, by dint of a little exertion; but when the left eye is covered, or the patient is looking thoughtlessly before him, a divergent squint arises; *diplopia* does not show itself except with a coloured glass held before the eye, and therefore would not incommode the patient. We should in this case certainly divide the *R. externus* of the left eye so as to allow the eye to adjust itself without any trouble upon the object, and should ignore the consideration of the *diplopia*.

If we do not discover the incongruence of the *retinæ* until after the opera-

tion, and the patient is much annoyed by the *diplopia*, we may unite the double images by prismatic glasses, It is often preferable to divide the prisms between the two eyes; for instance, if a prism of 12° is required to unite the double images, we may apply a prism of 6° to each eye, as this is for various reasons often more agreeable to the patient than having a strong prism before one eye.

Paralysis of the Orbicularis Palpebrarum.

We meet with this affection in all stages and degrees, from the slight *paresis* which is hardly perceived, and affords little or no annoyance from a flow of tears, to that which gives rise to *lagophthalmos paralyticus*, and all its accompanying evils.

The symptoms must therefore of course vary according to the degree of the paralysis, the individuality of the patient, and the amount of injuries from external irritants to which he may be exposed. We find that the eyelids cannot be completely closed, owing to the inefficient elevation of the lower lid, so that a chink of varying size exists between them. By an impulse of the will, the patient may succeed (more easily when the other eye is closed), in almost shutting the lids by the relaxation of the *levator palpebrarum;* if the latter is, however, also paralyzed, the upper lid hangs immoveably down, so that the patient is obliged to have recourse to his fingers in order to lift it.

The *lagophthalmos paralyticus* caused by paralysis of the *Orbicularis*, is present even during sleep, and continues generally in spite of reflex irritants applied to the *conjunctiva*.

In a case mentioned by Romberg however, the reflex action still existed while all voluntary motion was lost, so that when the patient's eye was subjected to a strong light, or touched with the hand, or when she sneezed, the eyelids closed completely. During sleep the eyelids were also completely shut.

Although so many different theories have been advanced to explain the manner in which the tears are absorbed, there remains now no doubt that the action of the *Orbicularis* muscle forms a *conditio sine quâ non* for their absorption

and in conformity with this view we find, that when this muscle is paralyzed, one of the earliest results is generally, that the tears flow in greater or less quantity over the lower eyelid and cheek. (I say *generally*, because we meet with so many people in whom the secretion is so very slight, that evaporation suffices for their removal, and in them the lacrymation shows itself only after some time as a result of external irritants.) The lower lid becomes somewhat everted, and stands off slightly from the eyeball, thus forming a furrow in which the tears gather. Soon the external air, and the constant irritation of particles of dust, etc., call up a hypersecretion of tears, and even perhaps a slight conjunctival catarrh; at the same time the conjunctival secretions, epithelial scales, etc., are not efficiently washed away, and bring about *xerophthalmos*, and even *keratitis pannosa*. In old people, whose muscular structures have lost much of their elasticity, these consecutive evils show themselves at an earlier period than in the youthful; and apart from any paralysis we sometimes meet with in them, a certain insufficiency of the *orbicularis*, which is the cause of a slight eversion of the lids, and consequent catarrh of the conjunctiva, and an increased flow of tears.

We have to seek the cause of this affection (Paralysis of the *Orbicularis*) in the paralysis of the branches of the facial nerve which supply the muscle. And according to the situation at which the facial nerve is affected, the paralysis will be confined to the *Orbicularis* alone, or to several, or even all the muscles supplied by the *portio dura*. It is a very important fact, which may be of great diagnostic value, that *lagophthalmos* is generally present in the isolated paralysis of the facial nerve, but is almost always wanting in cerebral *hemiplegia*. If I remember rightly, von Graefe has only *once* seen *lagophthalmos* in connection with apoplexy (and this happened to be a case of *lagophthalmos totalis*). Generally the *Orbicularis* remains unaffected. Hasse mentions, however, a case in which there was a very complete peripheral paralysis of the facial, caused by an inflammatory

parotidean swelling, in which, besides all the muscles of the face, those of the forehead and eyebrows were paralyzed, and yet the lids could be closed to a certain degree.

The causes of the paralysis of the facial nerve may be divided according to their situation into two classes,—the peripheral and the central.

Amongst the first, rheumatism furnishes a large contingent of cases, and may bring about a paralytic affection of this nerve within the course of a very few hours.

Tumours, exudative processes, abscesses, cancroid tumours of the parotid gland, or situated along any part of the nerve, may paralyze it by direct pressure.

Injuries, wounds, whether traumatic or operative, which divide one or more of its branches, may bring it about.

Todd also mentions excessive exertion, and the consequent impoverishment of the blood, and debility of the nervous system as a cause.

Amongst the cerebral causes, I need only mention the pressure of congested vessels, tumours, syphilitic exudations, apoplectic productions, etc., and processes situated at the base of the brain.

Our prognosis is of course dependent upon the cause. Can the latter be removed or relieved, it may be favourable; is it dependent upon some very grave cerebral lesion, it must be unfavourable, or at best very doubtful. The peripheral, and particularly the rheumatic paralysis warrants the best prognosis.

Our treatment must also be regulated and guided by the cause. In rheumatic affections we generally bring about a cure in the course of a few weeks by the aid of antiphlogistics, diaphoretics, blisters behind the ears, etc.; and particularly in these cases do we find great good arising from electricity; at first it should be applied at intervals of a day or two, but may afterwards be more frequently used; although it often effects a cure very speedily, we must not throw it up too soon in despair, as its beneficial effect may be retarded, and not show itself till it has been continued for some length of time.

For the *xerophthalmos,* numberless remedies have been recommended, and experiments made, in order to imitate as much as possible the composition of the lacrymal secretion: von Graefe has found frequent washing of the eye with milk the best topical application.

In cases where syphilitic deposits are suspected we give iodide of potassium; in cachectic or scrofulous subjects, cod liver oil and tonics may prove advantageous. If there is much *hyperemia* or congestion, leeches to the mastoid process and derivatives are indicated.

Should, however, the *lagophthalmos* and *ectropium* of the lower lid produce much irritation and inflammation, we must have recourse to the operation of *tarsoraphia;* we may operate upon the *ectropium* separately, but it will generally be preferable to combine the two operations. *Tarsoraphia* was first practised by Wallter, and has since his time been much employed with varied success. An important modification of this operation has been introduced by von Graefe, who has succeeded in obviating the evils which were too often attendant upon the old form of operation.*

Abnormalities in the movements of the Iris.

The movements of the *iris* ensue upon the application of certain stimuli, which may be reflected from the brain, or *medulla oblongata* upon the *N. oculomotorius,* or which may be imparted to the *iris* by direct irritation of the third pair. Budge has found that irritating the sympathetic nerve as low as the inferior cervical ganglion had the effect of dilating the pupil. When light falls into the eye the pupil contracts, and this is not owing to direct irritation of the ciliary nerves distributed to the *iris,* but to reflex action from the optic nerve; for the *retina* being stimulated by the light this irritation is propagated to the *encephalon,* and is thence reflected to the branches of the third going to the *sphincter*

* *Vide* von Graefe's paper upon *Tarsoraphia,* in his Archiv, vol. iv. part 2, page 201.

pupillæ. That this is caused by reflex action we can prove by the fact that if we cover one eye with our hand and allow light to fall into the other, the pupil of the latter eye contracts, but so also will that of the covered eye (although perhaps in a somewhat slighter degree); if we, however, let the light fall into an amaurotic eye, its pupil will not contract, but the contraction will ensue also in this eye when we allow the light to fall into the healthy eye; and this fact proves also that the immobility of the *iris*, when the light entered the blind eye, was not due to a paralysis of the third pair.

The movements of the *iris* are also intimately connected with the accommodation of the eye. The pupil dilates when the object is carried far away from the eye, and contracts when the object is approached closely; most likely the contraction of the pupil which takes place upon the contraction of the *R. internus* is more or less connected with this. Irritation of the sensitive branches of the fifth pair (and particularly those of the ophthalmic branch) causes contraction of the pupil; for instance, we see this in certain *ophthalmiæ*, in cases where foreign bodies irritate the *cornea*, *conjunctiva*, etc.

The *mydriasis* caused by belladonna appears to be due to a twofold effect, viz., paralysis of the branch of the third nerve, which supplies the *sphincter pupillæ*, and the irritation of the sympathetic branch which goes to the *dilatator*. The loss of accommodative power which takes place during the atropine-*mydriasis* is most likely chiefly due to the simultaneous paralysis of the *tensor choroideæ*.

The pupils also contract during sleep (even in the completely amaurotic), and Ruete supposes this to be due to a decrease in the sensibility of the nerves of sensation, for when the *N. trigeminus* is cut through (or according to Budge even only pressed), the pupil becomes narrower.

The movements of the *iris* have long been considered as affording a great aid in detecting cases of simulated blindness.

If a person, for instance, denies having even perception of light in one eye, and it is yet found (the other eye of course being closed) that its pupil contracts upon the entrance of light, we are in almost all cases justified in pronouncing this a case of simulation. In very rare instances, indeed, this reflex action of the pupil upon a stimulus applied to the optic nerve may exist, and yet the patient may be completely deprived of any perception of light; we should find this in cases where some impediment (tumour, etc.) is situated between the *corpora quadrigemina* and *sensorium commune*, which would annul the connection between the reflecting portion of the brain, and the *sensorium*.*

Although these cases are of exceedingly rare occurrence we should be always upon our guard not to rely too implicitly upon the mobility of the *iris* as a sure means of detecting fraud. Von Graefe mentions a case of this kind where a boy had, through a fall upon the forehead and consecutive *periostitis* and *caries orbitæ*, become completely blinded upon both eyes. The left pupil was without any reaction when this eye alone was illuminated, but the pupil of the right contracted most distinctly when even a moderate amount of light fell into this eye. And yet the patient had not the slightest perception of light.

As it is a question of great importance how best to detect cases of simulation, I may be permitted perhaps to call attention to a very simple method proposed by von Graefe, viz., the application of prismatic glasses.†

If a person complains of having lost the sight of one eye, we hold a prism with its base turned upwards or downwards before the healthy eye. If *diplopia* arises and the double images stand one above the other and correspond to the different positions of the prism, we can at once declare this to be a case of deception. The fact that we put the prism before the healthy eye puts the patient off his guard, for he does not of course suppose that this proceeding can have any reference to his affected eye.

Mydriasis.

The pupil is very much dilated and the mobility of the *iris* is almost completely destroyed. Vision also is generally more or less affected, owing chiefly to the confusion caused by the dispersed rays and by the dazzling.

This, however, varies greatly; some patients are but very little (if at all) dazzled, and others have great power of suppressing dispersed rays. If we hold a piece of cardboard with a small hole in it before the dilated pupil the dispersed

* Contractions of the pupil have been noticed in persons blind of both eyes, when the eyes were moved in different directions.

† V. Graefe's Archiv, vol. ii, part 1, p. 266.

rays will be annulled, and the patient will generally be able to see well.

We divide *Mydriasis* into two classes:—

I. The *mydriasis paralytica* which is owing to a paralysis of the branch of the third, which goes to the *sphincter pupillæ* and causes its contraction.

II. *Mydriasis spastica* brought about by the increased action of the ciliary branches of the sympathetic, which are distributed to the radiating fibres of the *iris*.

We have already called attention to one form of *mydriasis paralytica* in a former paper, viz., that connected with paralysis of the *oculomotorius*. In these cases the pupil is not dilated *ad maximum*, but only to about the same degree as in a dark room, its diameter measuring about 2-2½ lines. No change takes place in its size during accommodation, or during the different movements of the eyeball. Neither does the entrance of light into the affected or into the healthy eye, bring about a contraction of the pupil. But upon application of atropine the pupil dilates *ad maximum*.

We meet with another example of paralytic *mydriasis* in those cases in which the intra-ocular pressure is greatly increased (*glaucoma* for instance). The pupil is then dilated and sluggish, and this is not due as might be supposed to the impairment of vision, but to the pressure upon the ciliary nerves going to the *sphincter pupillæ*, for were the former the case the pupil would contract upon accommodative changes, and upon the entrance of light into the healthy eye, which is however not the case. The dilation is generally irregular, and at first not great, but at a later stage of the disease the pupil may become excessively dilated, owing to a progressive atrophy of the texture of the *iris*.

We see *mydriasis* occurring with *ptosis* after draughts of cold air, etc., and in connection with rheumatism. Mackenzie has observed *mydriasis* after blows on the eye or on the head, and wounds of the brow or temple without any affection of the optic nerve.

Mydriasis may also accompany some diseases of the

brain, as for instance *hydrocephalus,* apoplexy, paralytic affections of the cerebral nerves, etc. Contraction of the radiating fibres and consequent *mydriasis* is seen in cases of irritation of the sympathetic in certain gastric disorders. Von Graefe has also made the important observation that *mydriasis* (particularly one-sided) is sometimes a precursor of mental diseases.

The treatment must vary according to the cause. In rheumatic cases we may try blisters behind the ear and colchicum. Where it occurs in weakly constitutions we must prescribe tonics, and the bitter ones are particularly likely to be serviceable.

The *Secale cornutum* has been strongly recommended by some, and appears to have answered in some cases, but in others to have had not the slightest effect. Neuhausen has spoken highly of the *Euphorbia cyparissias.*

The spontaneous form of *mydriasis* which is accompanied by indistinctness of vision, paralysis of the accommodation, and *hyperopia* is best remedied by the methodical use of convex glasses. We may also sometimes succeed in relieving *mydriasis* by making a therapeutic use of the impulses which physiologically cause a contraction of the pupil. Von Graefe, after trying in vain many so-called specifics, has had recourse to this method, and has found it frequently successful.* We cannot make much use of the entrance of light into the eye, because generally the affected eye undergoes no contraction of the pupil under this impulse, and the effect of the concentrated light might be injurious to the *retina.* We may order the patients to practise their accommodation by reading, through a convex glass, small print held near the eye, and if the pupil contracts in these cases we may hope to derive some benefit.

Von Graefe has however seen better results from a forced and methodically repeated closure of the eyelids and has suc-

* *Vide* v. Graefe's Notice on the treatment of *Mydriasis,* Archiv, part 1, page 315.

ceeded by such means in improving old cases of *mydriasis* which had withstood all other remedies. It is a well known fact that the irritation of the branches of the fifth pair which are distributed to the eyeball and nose, is followed by a contraction of the pupil. Upon this fact are based the many irritant methods which have frequently been lauded for their virtues in curing *mydriasis*. It has been recommended by Serre to apply caustic (for about a second) to the *cornea* near the junction of the sclerotic, but this may frequently give rise to very great irritation. It may perhaps be applied to the sclerotic *conjunctiva* near the edge of the *cornea* with beneficial effect. Von Graefe has found the dropping in of tincture of opium effective in some cases, but these means are very unreliable at the best.

Myosis.

This is sometimes so excessive, that the pupil is smaller than a pin's head. We frequently meet with it in persons who are by business obliged to regard for a long time minute objects, such as watchmakers, lithographers, etc. They are only annoyed by the lessening of the intensity of the light, so that they cannot work when it is getting dark. It does not, however, as is frequently supposed, produce a narrowing of the field of vision, for we cannot compare it to the state which is caused by looking through a very minute opening in a piece of cardboard, for here the aperture is a certain distance from the eye, and must arrest many of the lateral rays of light. But in *Myosis*, the narrow orifice is situated in the eye itself, and the lateral rays would be only hindered from entering, if the substance of the *iris* had become thickened.

Myosis may be caused by irritation of the third pair, as in cases of *typhus*, inflammation of the brain, etc.; Himly says it also occurs in *hydrophobia*. In *hyperæsthesia* of the *retina*, it is caused by reflex action

Decreased or impeded action of the sympathetic has been

observed to be followed by *Myosis*. Under this head comes the interesting case reported by Dr. von Willebrand,* in which swollen cervical glands caused pressure upon the cervical portion of the sympathetic, and consequent *Myosis*. Gairdner also mentions a case of aneurism of the subclavian artery, accompanied by it. Enlarged tonsils may also cause it.

Myosis has been found accompanying diseases of the *medulla oblongata, tabes dorsalis* (Romberg), and is frequently a precursor of spinal *amaurosis;* in the latter case, Arlt has sometimes seen the pupil so contracted, that it appeared about half a line in diameter.

The treatment of *Myosis* must depend completely upon the cause. If it is produced by tumours, etc., these may perhaps be removed. Willebrand prescribed in the aforesaid case iodide of potassium internally, and an ointment of mercury, and iodide of potassium externally: under this treatment the hypertrophied lymphatic glands decreased in size, and the *iris* regained its mobility. In that form which we meet with in watchmakers, etc., we can only urge frequent rest of the eyes. In the *Myosis* which accompanies *hyperæsthesia* of the *retina,* we must generally avoid all depressing remedies, but give tonics, a good diet, allow the patient plenty of fresh air and exercise; we moderate the light but must beware of rushing into the other extreme of allowing the patients to keep hidden in total darkness, for the sensitiveness of the *retina* is thus very much increased. The best treatment is to give them a pair of cobalt blue spectacles, and to accustom them gradually to a stronger and stronger light, and thus we frequently succeed in curing patients in a few weeks who have sat for months and months wrapped up in shawls and shrouded from even the slightest ray of light.

The local treatment of *Myosis* is generally of no avail.

* Graefe's Archiv i, p. 319.

Hippus.

When there is a continual rapidly changing dilatation and contraction of the pupil, quite independent of the entrance of light, it is called *Hippus*. It is a state of the *iris* analagous to *nystagmus*. It must not be confounded with *iridodonesis*, that tremulous state of the iris which ensues after cataract operations, dislocation of the lens, or *synchisis* of the vitreous humour; the movements of the *iris* are in this case of a wavy fluctuating character quite different from those of *Hippus*.

We often find *Hippus* complicated with *hyperæsthesia retinæ*, *nystagmus*, etc., and it is said often to mark that period in *hydrocephalus* in which the irritation of the membranes of the brain passes over into effusion or exudation.

The treatment must, according to the cause, be antispasmodic, antiphlogistic, tonic, etc.

(*to be concluded*).

First Memoir

on

CORELYSIS.

DITACHMENT OF IRITIC AND OTHER ADHESIONS OF THE PUPIL TO THE LENS OR CORNEA, OR TO A "FALSE MEMBRANE," (Reinstated Pupil), *WITH A FEW REMARKS ON THE EXTRACTION OF CATARACT WITH PUPILLARY ADHESIONS.*

By Mr. Streatfeild.

In the first number of this Journal (October, 1857), I have quoted the first case in which I operated upon false membranes in the pupil, according to my new ideas of remedying this state as a consequence of iritis. I also mentioned a novel method I had adopted of detaching the iris from the lens when only in some parts adherent. These cases have

been altogether successful—the patient who had the false membranes I saw a few weeks ago, he had had no more iritis, the pupil of the right eye was, as I have explained in the former account, imperfectly cleared, and so it was left; but the other was quite unobstructed, and remained as it was after the operation, to the same extent answerable to light, nearly regular in shape, and its area quite free: (he is now a stock-keeper in the warehouse in which he had been engaged as packer), he could read any type or an inscription in rather small letters on a distant wall. Further experience encourages me to pursue my original plans of freeing the iris whenever it is adherent at its pupillary margin, whether to the lens or cornea, or to a false membrane in the pupil itself. Of course, I have already learnt some desirable modifications of my early system of treating these cases, and yet, perhaps, I should have waited till my experience is greater, but I have been anxious to bring forward this matter in some form, that it may be advanced or corrected by the scientific knowledge of more practised operators.

I propose, for brevity's sake, for comprehensiveness and common understanding, to call any surgical operations, such as those to which I here devote myself for the detachment of the pupil from whatever adhesions it may have, *Corelysis*.*

In almost all cases I have been in the habit, when the pupil only has been involved in any adhesion, of operating to free it, and lately I have learnt better which are suitable for the operation. The usual practice has been, I believe, to do nothing for partial adhesions of the iris or indeed in any of these cases† surgically, unless vision was *very much* impaired at the time; but this forbearance is, I think, a mistake, and corelysis should be done in very many cases of

* Corēlysis = Pupil freeing, from Κόρη and λύσις.

† Mackenzie says, "In *synechia anterior* of limited extent, the adhesion may sometimes be separated by means of a needle introduced through the cornea, or the adherent part may be cut across." He only thus briefly, however, alludes to this. Middlemore also mentions this as a preliminary to "artificial pupil" with *anterior* adhesions. I find no allusion to the separa-

the various kinds I have above mentioned; the risk of wounding the lens or producing another inflammation by operating, being much less than has been supposed. Besides that all iris-adhesions should be, if possible, detached and not left, I wish to inculcate that a pupil should be, and often can be, made in the former situation of the natural pupil ("reinstated pupil"), and not only as near to it as possible, as is usually proposed, and that when the pupil is entirely blocked up (occlusion), and no part or space left free, the lens behind it is generally transparent, and the lens capsule often may be cleared by removal or opening out of the occluding membrane. Diseases of the eye as a consequence of syphilis, directly or indirectly, are exceedingly common, and the result of iritis, much more frequently than the iritis itself, is the complaint for which we are consulted; but I have no doubt that the complete adhesion of the pupil to the lens (exclusion), its occlusion, white patches in the choroid, and other ill events of iritis could be prevented if the patients applied early and attended regularly, if belladonna was always used and mercury given sufficiently.

My paper will throughout appear to have a double bearing as it refers to the two cases in which either the pupil is bound to the lens or cornea, or to a false membrane in its area, but they are alike and are here always considered together in that, for either of them it is required to *free the pupil*.

1. As to the *prevention* of pupillary adhesions I have no other suggestion but that the old belief in belladonna and mercury should be cherished, that the former should never be neglected at any time in the treatment of iritis, and the latter should be generally administered in very frequent small doses continued for some time after the disappearance

tion of *posterior* adhesions or the removal of membranes in the pupil excepting to facilitate the extraction of cataract, as the plan was even in the last century. Lawrence (who has given so much attention to the subject of syphilitic iritis and its results) says of *synechia anterior* and *posterior* that they "cannot be remedied by operation."

of inflammation, with good food and perhaps some iron or other tonic, as well as the specific medicine. At the conclusion of the treatment of a case of iritis the absence of any adhesion should be ascertained, if the iris is not perfectly active, it may be because of a single band between it and the lens; and if at this time the atropine will not cause its separation, it is certainly, in my opinion, to be divided.

2. Until I commenced freeing the pupil in so many of the cases in which it is bound, I believe adhesions were disregarded, as far as any surgical or other remedial attempt is concerned, in any less serious cases than those of virtual blindness, that is to say, that unless there was very extensive posterior adhesion, the pupil was closed, or so in effect, the adhesions were allowed as of course. If belladonna was applied it was for the purpose of discovering an interval of the adhesions for the contemplated artificial pupil, whereby the iris was to be torn, cut, or excised, the adhesions themselves being left, and a confessedly ill-placed pupil made by one of the old methods. Belladonna will in fact seldom effect the severance of pupil-adhesions, when a patient applies because of them, and not for the efficient inflammation, then no longer existing; it may do so, it should be tried, and the discovery of an interval of non-adhesion of the pupil is to me of as great importance for the operation on the membrane which obstructs the pupil as it is for making an artificial pupil, in these cases the most urgently requiring an operation, or in any case for corelysis. The new method can, therefore, be only compared with Corectenia, Corotomia, Corectomia, and some others, all of which are really operations on the iris, not like Corelysis on that which confines the pupil, or occupies its place. These adhesions then have been permitted, but if all useful vision is lost in any case, the iris has been cut through or a part of it removed* and an

* I am not alluding to iridectomy but to the old cases in which artificial pupil has been made in a "sound eye." There is hardly any connexion between iridectomy and corelysis: excision of a portion of iris is a much more urgent and frequent requirement than the detachment of the pupil from

artificial pupil, necessarily out of the axis of vision, has been formed; these pupils are certainly not the best that could be imagined, and the operations on the iris, supposing them unnecessary in these cases, are also, it now seems to me, too severe, but for those of them in which the lens capsule certainly cannot be cleared in the area of the pupil. If, for the sake of conservative surgery, the iris should not even always be operated on for occlusion of the pupil, there has been introduced an heroic operation, which I believe to be quite unjustifiable, for the deliberate extraction of the transparent lens in these cases;* if, by corelysis, a cataract is discovered, it can be removed by way of the restored pupil, but I believe the lens is seldom opaque in cases of occlusion, and I know that although adhesions may exist between the false membrane occluding the pupil, and the lens-capsule, with which it is in apposition, they are probably only partial and much weaker than the capsule itself, at any rate in the cases presenting the external appearances to which I shall allude.

3. When corelysis, instead of doing nothing operative or making an artificial pupil, seems to be the alternative, it is because the ordinary medicinal agents used to prevent the adhesions or for their detachment, have been ineffectual; mercury has been tried, and no ciliary redness or other signs of latent inflammation exist, still the tentative use of belladonna may be made in any case; although it has probably been tried, and that when the adhesions, more recently

posterior adhesions,—iridectomy is for total posterior synechia, exclusion of he pupil, whereas only less extensive adhesions seem to be successfully detached from the lens by corelysis; iridectomy is also for occlusion of the pupil, but corelysis is only possible for those less common cases of this kind in which the membrane filling the pupil is not closely connected with the lens-capsule; iridectomy is a remedy for various morbid processes, but corelysis is only for the recovery of the healthy state of the pupil when no other morbid condition is known to exist.

* Before this was done, and quite lately, the operation of solution by drilling or otherwise has been selected and commonly used, although the lens is transparent; if it is not so, or if the membrane in the pupil is closely bound to the lens, the case is quite unlike those to which, as it may concern *my* operation, I have been alluding.

established, would be much more likely to give way. I do not know for certain how recent must be the adhesions, which, by the use of belladonna, will give way, which will be thus separated, or on what other conditions of treatment, or the state of the patient's health, this will depend; old bands will be extended by its use, if they are narrow and isolated, and recent adhesions, *only, as far as I know,* may entirely disappear. (It is a common mistake to suppose that of course adhesions found to exist with iritis, have resulted from the present inflammation of the iris). When the adhesions are to a false membrane in the area of the pupil, I believe, this membrane, however slight it may be, can only be dispersed by corelysis; no medicinal agent will remove it if it exists after the inflammation has ended.

4. Atropine, or, applied to the skin, belladonna rubbed down with glycerine, should be used without delay in the cases, whether recent or determined, in which the pupil may be or has been involved; if employed when the pupil can dilate fully the iris is so removed from the lens that it can hardly become bound to it by the opposite effect of the iritis, and then lymph having been effused between them, the mydriatic effect will, perhaps, be enough to cause their separation, and if not, the patient's vision is thereby probably improved for a time, and it is altogether essential to the surgeon for an exact knowledge of the state of the case. It is most important that the agent should be repeatedly employed; a solution of a quarter of a grain of sulphate of atropia to an ounce of water, will produce full dilatation in a healthy eye (but, in iritis, past or present, the effect is varied in the different cases), a strong atropine solution cannot cause more dilatation than this, but by it the effect is brought about more rapidly, it also probably lasts longer, and, when the iris is inflamed, perhaps it is the best to be employed (a shade worn by the patient may promote the dilatation or its continuance); and if these means have been ineffectual they should be persevered in, whilst inflammation exists, because the treatment otherwise adopted may give an opportunity of

dilatation in time, but if there is no inflammation they may be hopelessly discontinued. That posterior adhesions not unfrequently become detached is proved by the ophthalmoscopic examinations, in which, with a pupil properly dilated, their remains are seen often as a circle of irregular pigmented dots, or one or two opposite the margin of the pupil when it has been contracted, these, and, after corelysis, the like dots are compatible with very good vision.

5. The basis of the new method of operating is expressed in the title first applied to it of "reinstating the pupil," it is founded on the wish to restore the normal state of the parts, to imitate it better than by artificial pupil, or to improve the vision of those patients with bands of adhesion after iritis, in whose cases they have been left, if not with impaired vision, with probability of a recurrence of the inflammation which had caused them. For this purpose the pupil must be freed, and, if it was practicable, could be only found by the attempt in the different cases in which it is bound. Could the bands of adhesion confining the pupil be broken through by operation without injury of any of the parts concerned, and could the pupil be released from any of the membranes, which after iritis have blocked it up, by their being dispersed by operation; and the natural aperture of the pupil be thus made free again to dilate and contract in any degree? This position I have practically endeavoured to take affirmatively, and now I hold it so. That *synechiæ* are very prejudicial to the future integrity of the eye is my own conviction, but this can add little to the testimony of those who have so much experienced authority; of posterior adhesion, Von Graefe has said "*that the principal cause of the recurrence of iritis is the existence of synechiæ, especially when broad and inextensible.*"* Adhesions not only may

* *Vide* v. Graefe on Iridectomy in Iritis, etc., (translated), New Sydenham Society, Vol. V. In the same article later he has said, that the formation of an artificial pupil prevents the injurious action of the remaining adhesions; but when corelysis will destroy *adhesions* and then their *injurious action*, an *artificial pupil* certainly need not be made. Of my vagrant out-

induce a second iritis, but when the iris is first inflamed they may protract the recovery indefinitely: a single point of adhesion may do this, as in a case of mine in May, 1859, in which, with mild mercurials a syphilitic iritis had ended in resolution, with no ill result but a single point of adhesion to the lens, all redness of the globe had therefore disappeared, but opposite this one band it remained exactly there, and there only for a long time afterwards.

6. Of the advantages of corelysis, whenever we may consider its possibility instead of making an artificial pupil, I believe the most important to be the optical superiority of a central active pupil, the appearance is also an advantage dependent, in fact, on much the same qualities as those for vision; these better optical qualities which almost alone need be considered being the natural position of the reinstated pupil, and the better recovery of its normal adjustment in size; this power of dilating and contracting being often perfect in cases in which the bands of adhesion have been few and narrow. Of the operation, I must say, in anticipation of the objections of those who believe the lens-capsule is so very easily torn, that in about fifty cases cataract has only once followed, when I have known for certain beforehand that the lens was clear;* this case was one of the earliest on which I have operated, and the first spatula-hook I had had made and then used, was not perfectly rounded or well polished; of other ill results of the operation I say nothing, for I believe, if the cases promise well for the operation and all care is taken in its performance, there will be none or that none have resulted that do not more frequently occur when the iris is operated on for an artificial pupil: of this I shall speak again. When I call the operation trifling I do not mean that it is so to the operator, for him, I believe, it

patients none are so constantly at the hospital with various irregular complaints as the cases of pupillary adhesions; the eye is irritable, with or without ciliary redness, and vision defective, as to focus, and in other ways.

* My corelysis operations are yet most numerous, though my colleagues have made some trial of it.

requires much consideration beforehand to determine upon its adoption, an examination by daylight and with atropine and the ophthalmoscope, the latter to decide if any space seeming clear is really unobstructed, or if occlusion seeming complete, really has no space left for the instrument to be admitted. Besides this perfect knowledge of the state of the parts, and so of what can be done, it requires the closest attention on the part of the surgeon, during the operation, to the exact place of the lens, and above all things that the end of the instrument introduced through the membrane or beneath the bands of adhesion should be then at once carried away from the lens and kept always forward. Lastly, of the advantages of corelysis, I must remark, that when other apertures of the body are obstructed by disease, we do not think of making a false passage or a counter-opening if it can be avoided; and if corelysis is impracticable or unsuccessful, still as before, we can make an *artificial* pupil.

7. Corelysis should certainly not be attempted until the ciliary redness and other signs of inflammation are past; I do not propose it as a cure for iritis, though it may divert its return. The inquiry should be always first made before operating, if the lens is transparent or not; this, in the case of an occluded pupil, can only be learnt by the probabilities connected with the amount of vision left, but, of course, if the pupil is only limited by bands of adhesion, atropine and the ophthalmoscope will go to prove an uncertain case.* If the depth of the eye can be examined, it is well for a favourable conclusion of the case to know also that there is no cognizable vitreous disease or white patches in the choroid, etc. If, with adhesions of the pupil to the lens, cornea, or a false

* I remember one case with a clear lens, however, in which some slight filmy bands confining the pupil to it were made apparent by atropine, but with the light of the ophthalmoscope they could no longer be seen, as they were thus illuminated behind as well as before, and were not opaque as usual: these adhesions by daylight seemed pale and flattened: I did not consider them as remains of the pupillary membrane in this case, for besides other reasons, their attachment to the iris was at its pupillary margin.

membrane, I have known the lens to be opaque (corelysis, *for its own sake,* is out of the question), I have proceeded to operate for the cataract, then always using atropine; if by *extraction,* the corneal section is made very readily, and without need of the chief ordinary precautions, then, and especially at its completion, necessary: a membrane filling the pupil may be opened out with one or two needles to make a way for the lens, as the common practice has been; or if separate points of adhesion of the pupillary margin exist, I have preferred my spatula-hook for their detachment (see the footnote to paragraph 12). If it is to be done by *solution:* in the case of a false membrane, I have used the fine needle or needles to open out the membrane (without enlarging the pupil), and then to the cataract itself; or in the case of bands partially confining the pupil, I have introduced the needle where they can be most conveniently reached, and with it broken them through as a preliminary step: two needles may in such a case be well used if bands of adhesion at opposite sides of the pupil are to be reached. The needle operation for the cataract with iris-adhesions, and subsequent *linear-extraction,* may be well adopted if, as is often the case, the patient is young, and the inflammation has not been allowed to proceed to more serious injury than the limiting of the pupil. The patients are not so old as most of those who require an operation for cataract, so that "division" of the lens will have this advantage, and linear-extraction afterwards, if the pupil is large enough to allow of it, will curtail the task that by the sound eye may be better performed. This "extraction through a closed pupil" by a small or large section, however, is hardly connected with the subject of corelysis but as a supplement to the latter operation when it has revealed a cataract not before known or believed to exist; indeed it is especially applicable to some cases in which corelysis, *for itself,* as I have mentioned, should not be attempted, those in which a cataract is known to exist, or the occluding membrane is quite opaque and far back in the contracted pupil, etc.; and corelysis, as I wish it understood,

is for those cases in which the disease of the pupil is the only serious morbid affection that exists.

8. I have operated for the freeing of the pupil in so many and various cases that I anticipate the question, why corelysis should be so often performed, by a few remarks. In the first place, my unsuccessful cases, those in which the pupil always remained bound or occluded, were placed in no worse position than before for excision of a piece of iris, and this I have afterwards done in these cases with success: I have said that cataracts have not resulted, or seldom any worse results than re-adhesions. Next, although I have hitherto been operating in very different cases, wanting experience, many of the patients have been fitted for any occupation; and again, if adhesions did not predispose to a recurrence of iritis, the inflammation is undoubtedly often recurrent, and if a single band is left, the iris, when afterwards attacked, cannot retreat from the lens, and so probably becomes altogether bound to it. For these and other reasons before-mentioned, I always wish to free the pupil from any one iritic band when no inflammation is in existence; and this also I have done, and in so doing I have felt justified, because although when a single adhesion exists, or there are few and narrow bands, the present injury is every way so much less, and the prospect of a return of the inflammation is equally lessened, so that it may be thought both should be ignored in so trifling a derangement of the pupil; none of the unsatisfactory results connected with corelysis I have related have ever occurred in these cases, and these minor adhesions are at once and most easily detached.

9. It cannot yet be certainly defined in what cases the pupil may be reinstated, or in what others it cannot be done, or an artificial pupil must be made, but a close discrimination will show some cases that corelysis certainly will not remedy, besides those in which an eccentric pupil is desirable. The first kind to be observed are those cases in which the false membrane, which completely or nearly fills the pupil, is very opaque, and so deep and intimately con-

nected with the lens-capsule that the iris, evidently bound by it to the lens, would not probably detach the membrane, with it, from the lens-capsule, which would be removed or the membrane be left there instead, and perhaps the iris would be torn and bleed, and the pupil again become closed. Another kind of cases are those in which not only the pupillary margin but some greater part of the iris in its width is bound, as it often is, to a leucomatous speck of the cornea for instance. Atropine will give the diagnosis of these cases, and of those in which the false membrane is closely united to the lens-capsule. Adhesions generally which involve more than the margin of the pupil are not the cases for corelysis, therefore adhesions to the cornea often cannot be detached in this way, besides that in these cases the part of the cornea exposed is probably opaque: the spatula-hook will certainly separate the parts even when a great width of the iris is bound, but only from the margin of the part adherent by laceration of its tissue, causing bleeding and other ill results, with a very irregular pupil, even if it is not closed altogether. Still if an operation in such a case must be done it may be thought best, as the bleeding and other ill results are as likely to follow any old operation for artificial pupil, to separate the iris at the part adherent:* in the case of broad adhesions to opacities of the cornea, I have been able to do this at once by cutting them through with a broad needle, such as is used for corelysis. Lastly, I doubt if the detachment of adhesions to the lens-capsule, *not to a false membrane,* if they involve nearly the whole circumference of the pupil, is generally successful, insomuch as it *frequently* becomes renewed, and although vision may be improved the pupil is not free. If when I have separated these *very extensive* adhesions the pupil, by the use of atropine, has been able to retreat from the lens, it has been sufficient for the cure; but I have done iridectomy if it seemed unlikely that the pupil would dilate

* This is not corelysis; which implies freeing the *pupil,* the pupillary margin.

when it was freed by corelysis. Von Graefe particularly recommends iridectomy when the *whole* pupillary margin is adherent to the lens, a condition called exclusion of the pupil in contradistinction to its occlusion by a false membrane—the latter being cases in some of which I have found my own plan very successful.

10. The details of corelysis vary very much in the different cases in which it is necessary to free the pupil. The adhesions between the pupil and the lens or cornea, or the false membrane in the pupil, may appear to be slight when they are really very strong, or very elastic with the instrument when they have not seemed so at all under the influence of the belladonna used beforehand. Some bands will appear to offer more resistance* than others of greater extent in the same case, and some wide adhesions that are quite confirmed appear to offer no resistance to the instrument. I am afraid that all these differences are uncertain before the operation, and, in order to retain the aqueous humour when it is done, it must be completed without hesitation.

11. The instruments necessary for corelysis are, besides the spring-speculum and forceps with which to hold the eye, a broad needle, my spatula-hook, and perhaps cannula scissors and forceps. The broad needle should be a small one, only to make an opening large enough, without cutting, to admit the other instruments (this may be proved beforehand with the aperture made by it in a piece of leather), so as to retain the aqueous humour as much as possible. The spatula-hook is figured and described at page 8 of the first volume of this journal: the thickness of the spatula part, "the terminal quarter of an inch," should be equal, and not much reduced so that it may be very blunt (the instrument, especially at its extremity, and the hook, should be highly polished); the only difference I have

* *More in appearance:* that is to say, the resistance in any case of corelysis is hardly enough to be considered, as it is felt with the instrument that is being used.

made from the instrument figured is that the one I now use is rather less altogether in its width* and every way; the spatula part should, moreover, be wider than the diameter of the round part of the instrument (made so next the handle for facility of turning it "in the corneal wound upwards or downwards"), that when it is in the anterior chamber, the aqueous humour may be better retained. The cannula instruments should be the smallest, and well polished: the scissors should have blunt ends, and the *outer* side of the blade used should be kept next the lens during the operation.

12. Corelysis for bands of adhesion is difficult when they exist at various parts of the circumference of the pupil without any wide interval (see Fig. 2, *M.m.*): if such an interval exists the opening into the anterior chamber should be made at that part of the corneal margin, and the spatula-hook there introduced to detach the bands (*N.n.*); but if there is no large space the bands on the side of the pupil at which the cornea is punctured cannot be satisfactorily reached (as at *a.* and *b.* *M.m.*) without making afterwards another puncture on the opposite side of the cornea, and separating those that could not be severed at first: this, on account of the escape of the aqueous humour, can only be accomplished at once, if it is very quickly done. Sometimes, I have, with the hook of the spatula, secured bands on the side at which the instrument was introduced by pulling them towards the greater circumference of the iris, at the aperture of the corneal margin, as the spatula-hook is removed from the eye; but this manifestly cannot be done if the bands on this side are firm, because the pupillary margin would rather become torn by the force which would be exerted on one part of its circumference, so that, unless the adhesions in any such case are found to give way very readily, I have not attempted the detachment of those on the side of the corneal puncture by any such extension of the pupil, as its safety then would be made to depend on its degree of extensibility. The ope-

* About $\frac{1}{24}$th of an inch.

ration is also difficult, or rather embarrassing, when the bands to be detached are old and very firm, or long and very elastic; in the former instance, the iris itself is seen to stretch so much that its separation from the ciliary processes seems probable, but instead of this the adhesions will always, in my experience, rather give way: in the latter case, the band will also break through, however elastic it is, though, to effect this, it may be necessary to stretch it with the spatula hook from the pupillary margin almost across the anterior chamber; no other misfortune occurring, in either case, than perhaps a little bleeding from some ruptured vessel of the iris. I used to wonder why adhesions of considerable length did not more frequently hang bowed when the pupil was contracted; but now I believe that, as a rule, their great length, when the pupil is dilated, proves their being very elastic, and when detached at either end, they do not generally hang down loosely, but retire at once, more or less, to their attachments. The narrow bands of adhesion are, in my experience, generally old and elastic. (I have seen one instance in which a long band of posterior adhesion became bent at an angle in the contracted pupil). Corelysis has many more difficulties when the pupil is to be freed from a false membrane; if no aperture exists in it, one must be made: this is described with the account of the operation; and, as in freeing the pupil from bands between it and the lens, the question is always how to reach that part which is on the same side as the corneal puncture.*

* *With a large section of the cornea* (*lower*) for the extraction of cataract (see paragraph 7) Richter found this difficulty in the separation of adhesions of the iris; he says, "How is it possible to separate the whole surface of the lens from the iris with an instrument which is quite straight? It may be possible to make it pass between them in the upper part of the eye, but it will be found impracticable in the under; and what is there to be done if the adhesion be chiefly at the inferior part? The instrument I generally make use of is a flat probe, pretty much bent at one end. This I introduce between the lens and iris, and endeavour to move it gradually around its axis, sometimes gently pressing on the cataract in order to push it a little back, and promote the separation."—From "A Treatise on the Extraction of the Cataract." (Translation). London, 1791.

13. Of the dangers of corelysis in anticipation of the operation, especially of causing cataract, I have already spoken, in comparing the reinstated pupil with iris-operations. I do not know how severe an injury of the lens-capsule is necessary to produce a cataract, but I am sure with instruments well made for the purpose I frequently touch it without any ill result; but, as I have said, I always keep the end of the instrument rather forward; that is to say, against the posterior surface of the iris or pupillary exudation, in detaching bands or a false membrane, that I may touch the lens as lightly as possible. I should not be so careful in this matter but for the difficulty of perceiving the minute distance between the iris and the lens, and of appreciating the slight changes of place which would bring the instrument upon the lens; so that, during corelysis, I constantly bear in mind to keep the end of my instrument away from the lens. I have, at the present time, a case at Moorfields in which the lens would, according to the common notion, have been expected to be changed from its transparency.

John Bryson, aged 52, a smith, had grains of gunpowder in different parts of the skin of the face, and a great many in the conjunctiva, and at different depths in the cornea. When twelve years old he was using an old gun, which burst, and his face was quite blackened with the powder, but twenty-three years afterwards he had small-pox, and the black marks in the skin were nearly all removed: some of those left in the conjunctiva and cornea were as large as a mustard seed. For seventeen days after the explosion he could see nothing (? edema), he had nothing done, his vision was for a year or more confused, he had double vision with the right eye when the left was closed, but afterwards he knew he could see well again, because he could in his work, with either eye, "look along a *straight edge*," as he was in the habit of doing. He had had no pain in either eye, and this was so until three years ago, when he had ague, and the right eye became impaired, but he did not know it was so dim until he got one day a "fire" (a drop of dross from the surface of welding-hot iron) in the left eye (which was sound); he put his hand to it, and found he could only see light with the other eye. There was an almost complete "arcus" in both eyes, and there were in both several large and small black bodies, some just beneath the conjunctiva, some deeply imbedded in the sclerotic and cornea, besides many cicatricial specks in the latter; all of these were in greatest number in the right eye, with it he could only see large light objects, but with the left eye he could, with his

spectacles, read the smallest type. Atropine and the ophthalmoscope showed, in the right eye, many specks of opacity in the cornea, two of them with black centres, irregular striæ, chiefly in the centre of the lens and at its lower part, and large brown flakes moving occasionally in the vitreous space with the movements of the globe: the retina and choroid, as well as they could be seen, were normal: in the left eye there were the same specks in the cornea, but none with black centres: there was no other morbid appearance in any part of this eye; but in the anterior surface of the lens, near the upper and inner margin of the pupil, there was a dark body seen sticking into it, and partly covered by a greyish opaque speck, projecting a little: it exactly resembled the other powder grains, but was half hidden by lymph (?): no radiating or other opacity around it, or in any part of the lens, existed: the depth of this eye also was clear and normal. I extracted the lens of the right eye, and with as good a result as could be expected, considering the state of the cornea and vitreous humour, before the operation; with it he could afterwards distinguish large type.

Any other danger in corelysis that I know of, is much greater in the operations for artificial pupil; for instance, bleeding almost necessarily follows when the iris is cut or torn for these operations; but in freeing the pupil it is not common, although, even in detaching bands, I have known it occur from the part detached, or, when they are very tough and stretched, from the surface of the iris: it is very much to be avoided; and, when it occurs, the blood, if it is much, should be evacuated with the scoop: it is best, at any rate, to attempt this, for if a clot has no other ill result and is rapidly absorbed it will interfere with the *immediate* advantage to be expected by successful corelysis, and perhaps its consequence is greater in the result, even if it is not a failure, than may be supposed. Sometimes, I have found, when the pupil has been freed, and it has filled with blood, the operation has resulted in its closure, as I have thought, perhaps with the organized remains of the clot in the pupil, or by a membrane so discoloured by it, or pigmented, that at first sight, without the ophthalmoscope, the pupil seems to be clear. I have suggested one rule in corelysis which will rather encourage bleeding from the iris, unless it is well considered: when the pupil is freed from posterior bands confining it, the spatula-hook introduced between the iris

and the lens is to be carried forwards, *but not very much,* as it is brought up to the adhesion, or it may be torn through in the iris at the pupillary margin, or at that part of it, instead of near the lens, where it will be unlikely to cause bleeding: again, when the pupil is to be freed from a membrane, not only the lens, but the iris must, as I have said, be discriminated and avoided in opening the membrane with the broad needle, so that, although this instrument in the pupil must be kept carefully forwards, *as much as possible,* it should not be so much so as to endanger the iris, which it is very important not to injure. In no case of corelysis should the pupil be extended with the spatula-hook, or other instrument, in any direction more than is absolutely necessary, because, by the stretching, some of the small vessels of the iris, which has been (perhaps recently) inflamed, are likely to give way and bleed, the more so as the aqueous humour has escaped, and later ill-results may follow this forcible dilatation of the pupil. The cold water, and perhaps the atropine, used after corelysis will check the bleeding: they should be applied at once.

14. My method of operating is the following: atropine has been applied to the eye: the patient is recumbent, and I stand behind him: I have chosen a broad needle which is suitable to the spatula-hook, that is, as I have explained, a little wider than it: the patient has probably taken chloroform. I secure with toothed forceps, in the right or left hand, as it may be most convenient, a fold of the conjunctiva close to the corneal margin on the side opposite to that at which the puncture is to be made, thus I draw the eye sufficiently in the desired direction and steady it. (It is best to secure a considerable fold of the conjunctiva close to the cornea, and to have a deep hold of it that it shall not give way: sometimes it is convenient not only to draw the eye with the forceps in an opposite direction to the proposed corneal puncture, but at the same time to rotate the globe somewhat on its antero-posterior axis: this may be done either way by having the conjunctival fold a little to one or

other side of the direction in which the globe is to be drawn.) It is impossible, in the variety of cases in which corelysis is applicable, to say generally which way the globe is to be held, because, for instance, if an adhesion of the pupil is most conveniently to be reached from above it may be detached without any rotation of the globe, if it is so prominent that the brow will not interfere; or in another case the reflection from the cornea of the light of the window opposite the patient may make some rotation of the globe, when it is held with the forceps, more convenient than a change of place on the part of the operator. It is also impossible to say where the puncture should be made in the cornea, even at what distance it should be from the margin: this is, in each case, very important, for, when made, the corneal opening is a fixed point from which alone the operation has to be carried on to its completion. I have not generally made it very near to the margin (perhaps at a line from it), but my rule will be found by considering first, that a (posterior) adhesion should be always detached as close to the lens as possible; second and third (in this special instance), is the band corresponding to the position of the pupil when contracted or dilated? and so at what part is it of the convexity of the lens? of which the natural curve is to be

Fig. 1.

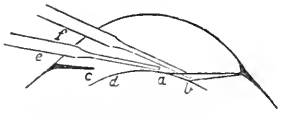

a. A posterior adhesion of the *contracted* pupil.

b. The same, of the pupil when it has been less contracted.

c. The normal iris.

d. The lens.

e. The spatula-hook introduced through the cornea in the best position to detach an adhesion at *a*.

f. The same, to detach an adhesion at *b*.

The figure is intended to show that to detach adhesion *b*, the spatula hook must not be introduced so near to the margin of the cornea (seen in section) as at *e*, or the adhesion cannot be reached, *at the point of its attachment, without pressing upon the lens.*

considered (Fig. 1), as it should not be pressed upon by the instrument as it passes over it to reach the band at its point

of attachment, the severance of which alone is to be attained; on the other hand, it can never be required to make the puncture far from the corneal margin, or the end of the straight instrument might come upon the lens, which it would be much more likely to injure than the flat side of the spatula would.

15. The easiest case of pupil-adhesion to be detached is when a single band connects the pupil with the lens, then the corneal puncture may be made most conveniently, perhaps (as in Fig. 2, *M. n.*) not exactly on the opposite side to that at which it is, or at a quarter of the circumference of the cornea, but between the two, that the spatula-hook may be advantageously used as a spatula or as a hook; as a spatula, that is to say, for its blunt edge, the instrument is most generally useful, and perhaps most safely or easily used, as the stretching of the iris that may occur, is thus more distributed than by collecting some part of the width of the iris, to which the band is adherent, in the hook to be severed at once. With the instrument entered in the direction I have described, the band, if it does not detach before the blunt edge, will pass downwards with the sloping direction of the instrument, and be arrested by the hook, with which it can be then broken through. If two such bands exist at opposite points of the pupil (of an hour-glass shape as in the old case referred to at page 9, of Vol. I.) the spatula-hook will be most conveniently used when entered from a part of the cornea, towards its margin, midway between them (see Fig. 2, *N. m.*), and then, if the hook of the spatula is required for their detachment, the instrument must be semi-rotated when the first one is separated, before the instrument is applied to the second band. When the instrument is thus rotated in the anterior chamber (the aqueous humour should not have escaped and) the end of it should be brought forward towards the central part of the cornea, that as the blunt edge instead of the flat side of the instrument passes the lens, it may only touch it lightly, if at all. If many

Fig. 2.

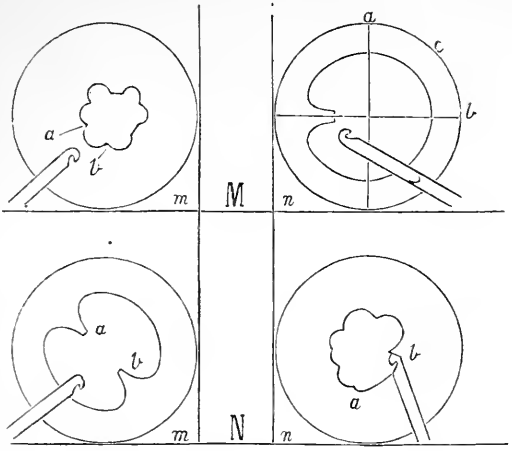

Fig. 2. The four diagrams show (magnified) various posterior adhesions of the pupils, all under the influence of atropine.

M. m. The six points of attachment, nearly equidistant, are so much the more difficult: the two, *a* and *b*, cannot be easily detached with the spatula-hook introduced through the corneal margin thus most conveniently for the others.

M. n. The instrument, to reach the point of adhesion, is best entered where it is (or at *c*) and not at *a* or at *b*.

N. m. The spatula-hook should be brought up to the two opposite adhesions (*a* and *b*) from a point midway between them.

N. n. With such various adhesions the instrument is used to most advantage at the widest interval (between *a* and *b*) and can be passed (as it is shown at *b*) even behind those on the same side as the corneal opening.

bands exist the instrument is introduced to most advantage from the side at which there is the greatest interval for its admission (see Fig. 2, *N. n.*), the division of pupil attachments being always attainable excepting on the side at which the instrument is being used (see Fig. 2, *M. m.*). The broad needle to make the opening in the cornea, is directed towards the pupil, and is introduced with a thrust, without cutting, as far as the widest part of its blade, to which its size in relation to the spatula-hook has been calculated beforehand; it is then quickly withdrawn, and the spatula-hook as quickly passed in by the opening that is made, the hook being on the upper or lower edge as may be required, the end of the instrument is brought up to the adhesion and passed under the margin of the pupil (as at *b*, in Fig. 2, *N. n.*)

close to it and far enough beneath the iris, the end of the spatula being at the same time kept in apposition with it, the instrument is then brought towards the pupil, up to the adhesion, not pressing the iris forwards or the lens backwards, but just between them, that the attachment may be released, as it generally will be very readily at its place, without tearing the iris or compressing the lens; in all this it must be remembered that the lens is not felt in its position, the direction of the spatula-hook is a matter of calculation throughout, the course it is to take has been determined and is well known; and the iris or its pupillary adhesions will offer no appreciable resistance. If all the cautions, respecting the lens, I have given appear contrary to what I have said of the unnecessary fear commonly entertained of its being wounded, I can only say, that by taking such care I have had the success which induces me so confidently to ask attention to the new proceeding, and I do not know that cataract would have resulted from less caretaking. The withdrawal of the spatula-hook should be, of course, with the flat part in the direction of the length of the corneal puncture, and it is effected without any chance of the hook being caught in the cornea, if the edge of the spatula, *without the hook*, is kept lightly pressed into the corresponding extremity of the linear wound.

16. The most important cases for corelysis remain to be considered: I have known vision more impaired with bands confining the pupil to the lens, than with a false membrane, leaving to all appearance in the pupil no free space whatever; the case of simple bands of posterior adhesion with very imperfect vision, may be possibly explained by various complications of the iritis, which has caused the adhesions limiting, but not blocking up the pupil; and the other case in which a complete false membrane filling the pupil exists with fair vision, by its being only a very fine network, thinnest at its centre, in the pupillary area: these false membranes generally have been recognized as surgical (artificial pupil) cases, but only to be operated on when

serious loss of vision is the patient's complaint. The occluded pupils which I am about to consider, in an operative relation, are also most important, inasmuch as they are most difficult, and as they are certainly irremediable but by operation. Here I will premise that it seems to depend very much on the diagnosis of the false membrane, if corelysis can effect a cure when the pupil is filled: the cases suitable for the operation, are not those in which a perfectly opaque patch in the pupil is seen with an iris, more or less standing forwards around it, the membrane is not of a dead white, but gray by daylight (Plate XI, M.), or half illuminated by the transmitted light of the ophthalmoscope, and it is little behind the iris, which does not fall back towards it, or is not bulged around it, and is not discoloured: the condition I allude to, in which the iris is in its natural place, and the membrane filling the pupil is about on a level with it (which with its partial transparency are, I believe, the indications for corelysis, in cases of occlusion), is probably to be explained by two circumstances in which it differs from the opaque membranes with prominent iris, the closed communication between the anterior and posterior chambers not being altogether impervious to the aqueous humour, and the membrane not being firmly attached behind to the lens-capsule, so that there, as it is not closely adherent, some fluid transition is allowed. Indications favourable to the operation, are the evident contraction of the fibres of the iris when the eye is exposed to a strong light, a large anterior chamber and the (occluded) pupil not very small, improvement of vision, so as to read large type, by the use of atropine,* etc. My best results have been, I think, in cases of young persons who have been judiciously treated for a first attack of syphilitic iritis, and to whom some mercury

* In any case, for corelysis, I should expect the patient to have a ready appreciation of light-reflecting objects, unless there is a cataract behind the membrane, which may be distinguished from the opaque white membrane filling the pupil, which it is impracticable to corelyse, by the opacity in the latter case being more distinctly seen as it is more in front.

has been already given. If the false membrane seems altogether to occupy the pupil, it must be examined with atropine and the ophthalmoscope, for the discovery of any possible gap in it, by which the spatula-hook may be introduced, a chink even smaller than the end of the instrument may be made to admit it, and the membrane is torn through with the hook of the spatula, or divided with the cannula scissors. If the hook of the spatula is to be used, the instrument must be introduced through the cornea, on the *opposite* side to that at which the opening is in the membrane, and in this way I have generally concluded the operation at once: the cannula-scissors can only be used when introduced from the *same* side of the cornea as the opening in the membrane, and probably, only with safety after the spatula has been passed between the membrane and the lens; this method, therefore, I have not followed since the case of Sharp, I have referred to.* When no space at all is left in the occluding membrane, the plan I have adopted is to introduce the broad needle through the cornea, in any direction which may appear to be lengthwise of the membrane, then to advance the needle across the pupil to the opposite side of the membrane, and transfix it just within the pupil close to the iris, but carefully not to cause bleeding from it, raising the membrane from the lens with the needle as soon as the point has pierced it, and advancing the needle a little to make the opening larger, whereby there is no greater fear of wounding any part, as the needle has been passed *across* the pupil, and the convexity of the lens, and beneath the iris. Because of the spherical prominence of the lens which is close behind the pupil, it is clearly impossible with safety to pierce the membrane with the needle on the same side as that

* At the commencement of this paper: in his case I introduced the cannula-scissors, by a previous puncture of the cornea with the broad-needle (see Vol. i, p. 6); but now cannula-scissors are made to be passed in without this preliminary, thus better retaining the aqueous humour; and if one point only was made sharp for this purpose, the other one might be used for corelysis safely, being kept next to the lens.

by which it is passed through the cornea, but I not know whether it would be safe in any case, and the pupil could be cleared by passing the cannula scissors at once through the cornea, and the blunt point through the crevice, *when there is one,* in an occluding membrane, without previously using the spatula to lift the membrane and separate it from the lens, by all which the aqueous humour is so much let escape, that as in Sharp's case, the scissors could only be adopted at a subsequent operation, which, of course, it is very desirable to avoid: I passed the spatula-hook once through the membrane and close behind it, to separate any filaments that might connect it with the lens, but I did not venture, at that time, to use the scissors, because of the diminution of the anterior chamber which had then resulted. I am inclined to the adoption of my early plan, of passing the spatula *between* the lens and the membrane, *before* the latter is operated on, in every case.

17. As to the after-treatment of a case in which the pupil has been freed, I have no special knowledge; I have had atropine applied after the operation night and morning,* the eyelids closed, to insure rest to the eye, perhaps with a bandage and cold water at first, with a folded rag constantly until any ciliary redness has faded, or it is no longer agreeable to the patient. I have never known any more extensive inflammation than of the iris itself, follow corelysis: in several cases, by this consequent iritis, the pupil has again become occluded or bound to the lens by adhesions, and then no benefit has resulted: in two or three, the pupil has been more obstructed than it was before the operation; and if it is not, at once, subject to treatment, this traumatic iritis is fatal to the operation and altogether hopeless: leeches and other antiphlogistic treatment are the means I have employed for its reduction. A rather common accident when the pupil has had many posterior adhesions, is their immediate reformation, even when well detached, this has occurred, I think,

* And for some weeks after the operation it is probably advisable to continue the mydriatic treatment.

in the cases in which the iris has by their extent and duration, or by change in its tissue, been long inactive, and the atropine (which seems to have little effect when applied to an eye reddened by a recent operation)* has not withdrawn it from its apposition with the lens; after this, I have sometimes repeated the operation with success, or I have performed iridectomy. Corneal adhesions are, in any case otherwise suitable for corelysis, so far anterior to the plane of the iris that they are very unlikely to reunite, because *all* the aqueous humour seldom escapes in the operation, and if it has, in any case, and the iris and cornea after detachment, can be in apposition, it is very soon resecreted and retained.

18. Of the results of corelysis, I can say generally, that the more the pupil recovers its activity the better it is in every way: sometimes the iris seems to be so condensed by the original inflammation that, after detachment of bands or more probably of a membrane, although well effected, the pupil must always have a uniform shape and little variation in size: vision may nevertheless be much improved, and even if it is not, the result of freeing the pupil cannot be said to be negative, as we know the relation of iris-adhesions and recurrent iritis. I have sometimes thought of dividing the pupillary margin, with cannula-scissors in these cases, in which the pupil is freed, but seems to be so very small an aperture, of one size, contracted by the infiltration of old inflammatory exudation;† this operation would enlarge the pupil if it were desirable, but if it acted again, it could only

* Sometimes, therefore, I have applied belladonna rubbed down with glycerine around the eye.

† Are there not some cases of old myosis in watchmakers and others, who can see very well with the most brilliant illumination, and less and less well in diminishing light, who would be benefited by simple division of the pupillary margin of their irides with cannula-scissors, as sphincters guarding other apertures of the body that may be abnormally contracted are incised occasionally? A central circular pupil is best optically and cosmetically, but the artificial coloboma iridis should not be extensive, and only made when myotic eyes are not otherwise diseased, than as the iris is affected; many cases of congenital coloboma, even in the (common) downward direction, co-exist with good vision.

be by dilatation at one part of its circumference. As to the shape of the pupil after it has been freed from an adhesion, the part at which it was connected frequently remains immoveable, but as a whole, that is to say, it is moved freely but it has a point of its own (out of the centre of the pupil, nearer to the pupillary margin, and always equidistant from it), to which so many of the iris-fibres are directed, and which is only made to change its place by the dilatation and contraction of the remainder of the pupil, whilst it contributes nothing to the change of size in the pupil itself (see Fig. 3, A. *b*.); the outline of the circle is generally there somewhat flattened (see Fig. 3, B. *b*.), and the band, especially if it has been in connexion with an old leucomatous speck of the cornea, remains as a slight projection: if, in any of my cases, there has occurred any loss of substance of the pupillary margin, as a circumferential indentation, it seems to be less satisfactory. When, soon after corelysis, the remains of an old adhesion project from the margin of the pupil, backwards or forwards, in the place it had before it was detached, it may appear at first sight, as if the operation had not succeeded, but the projection of either end of a band which has been severed, soon diminishes, and shrinks more and more until the deformity is hardly perceivable (see Fig. 3. A. *a*.).*

I will now conclude this vague rudimentary memoir with a few cases, in which neither the best nor the worst results of my various efforts to free the pupil are shown: they are instructive, encouraging to me, and by-and-bye, I hope to know the precise limits for corelysis operation; and then, with more experience, to write again on this subject.

James Mussel, aged 25, stableman, February 16th, 1860, came to me at Moorfields, and I entered his case as "Occluded pupils; slight corneal nebulæ." Three years ago last November he had a chancre, for which he had no medical treatment, and then sore throat and an eruption, for which he took mercury, so as to make his gums rather tender: two or three weeks later his

* *Vide* more "results,"—Ophthalmic Hospital Reports, Vol. i., pp. 42, 93. 142, 204.

eyes inflamed, the left one two or three days before the right: he had only a "thick brown mixture," took no mercury, and for four months they were "bad." When he first came to me the state of the eyes was very symmetrical, both pupils small, irregular, lozenge-shaped, and longest laterally, were quite filled with pearly membranes. There was no ciliary redness, and his eyes were otherwise healthy-looking: he had occasional slight pain in the brows: with either eye he could read well No. 10 (Jaeger's) or a much smaller type with difficulty. The irides would readily dilate and contract a little with light, but atropine showed no part of their margins to be quite free, nor was vision improved by it. With the ophthalmoscope only a faint red light could be seen through the pupils in some ways of the reflection, where the gray membranes were thinnest at their centres: at their margins they were much more dense and opaque with some dark (uveal) streaks near the pupillary margins (see Plate XI. M.). On the 5th of March, I operated alike on both the occluding membranes, with the broad needle introduced at the *outer* margin of the cornea, and its point through the membrane, on the opposite side of the pupil, at the *inner* margin close to the iris; then, the point being a little raised, it was advanced so as to make, with the broader part of the needle, a rather larger opening: next, with the hook of the spatula, passed through the gap in the membrane thus made, the *upper* margin was seized, and torn through by a slight movement, as if to withdraw the instrument: the spatula-hook, being turned the opposite way, was again passed through the opening in the membrane, and at its *lower* part it was by a similar proceeding again torn through, separated from the pupillary margin as I wished, and lifted away from the lens. At this time the membranes were retired to the outer sides of the pupillary apertures, and left there hanging loose towards the lenses: the aqueous humour having all escaped, I could do no more in either eye. The membrane in the left eye had seemed to me the strongest: in the right a minute drop of blood escaped from the iris. I ordered rest, cold water, and a bandage over both eyes. On the 8th, there was very slight redness of either eye: the pupil of the right (in which had been the bleeding from the iris) was again closed with the membrane filling it, and it looked much as before the operation: the left pupil looked quite clear, but, as after the operation, the rolled-back whitish membrane was adherent to the outer side of the pupillary margin, it responded fairly to light, was tolerably round, and still showed indication, being longest horizontally, of its former shape: with it he could read Jaeger's smallest type (No. 1.) without much difficulty, and the patient said with it everything looked as clear as before the first iritis. The ophthalmoscope confirmed this as the true state of the parts. I spoke of removing, with the cannula-forceps, the retracted membrane, and so (surgically) completing the case; but the patient said his sight was perfect, and would not hear of anything more being done to this eye; and so, as the pupil was unconfined, I was not sorry to think no more of it, and thus it was left permanently, and so it remained (Plate XI, N.). On the 12th, a narrow vertical chink being visible on the inner side of the membrane refilling the pupil of the right eye, I by it reintroduced, from the outer side, the

spatula-hook, and separated it upwards and downwards, but the pupil never became clear or quite free of the old membrane: he saw better however with it than before the operation: the left eye was still good for the very small type. He returned to his employment.

This was a promising case for corelysis, and perhaps no other operation would have been attempted. The result, in the left eye, was very satisfactory. I believe that I operated again upon the right eye too soon after my first attempt, and that the bleeding from the iris prohibited a good result. He has not returned to the Hospital.

Frederick Marsh, aged 55, came to me on January 19th, 1860, complaining of floating black spots and impaired vision: with the right or left eye he could only read Jaeger's largest type (No. 20): both pupils were bound to the lens at many different parts of their circumference, they were rather small, irregular, and acted very little, if at all. Sixteen years previously he had had "rheumatic fever" and "inflamed eyes," he was "subject to rheumatism;" but, not until he had an attack four months before this time, were his eyes more affected than they had been since the fever: his sight had become much worse, but he saw less of the muscæ than before. The iritic bands were adherent so nearly to the centres of the lenses that with atropine and the ophthalmoscope, I could ascertain no more than that the lenses, in the axis of vision, were not cataractous, the bands connecting the pupil and the lens were dark coloured; but a broad, irregular, gray band extended across each pupil as an incomplete occluding membrane. I operated at once: in either eye introducing a small broad needle at that side of the corneal margin at which the iris was least drawn towards the centre of the lens, as there I thought the adhesions must be weakest, if not deficient: all the bands, pupillary or pupillo-lenticular, in either eye, were readily detached with the spatula hook which passed around the pupillary margins and by slight extension of the pupils on the side at which I had entered the instrument, where the adhesions seemed to be slight, as I had anticipated, I believe both were perfectly freed. The bands in the right eye offered no appreciable resistance, in the left they were strongest. I ordered atropine drops repeatedly, and cold water constantly to the eyes. On February 6th, the patient, who lived in the country, was recalled to his home, and he was quite satisfied with the improvement effected. Both pupils acted to some extent: both were readherent (to the lens) at some parts, but dilated *fully* in other directions. To ascertain this, I had applied the atropine drops; but, before doing so, I found he could read with the right eye No. 16, and *with the left No.* 2, (of Jaeger's types).

If this patient could have stayed in town I should have operated again to free the pupil of the remaining adhesions; but, left as it was, the case was rather unsatisfactory, although

I believe numerous pupillo-lenticular bands, approaching to "exclusion of the pupil," are the least inviting cases for corelysis, much less than those of simple pupillary (occluding) membranes. This patient, as in many such cases, was so much surprised with the improvement of vision after the operation, that he would not consider any proposal to effect greater good subsequently; and the surgical objection to the result, that the pupils were not freed, seemed to him therefore of no importance.

James Harrington, August 22nd, 1859, came to me at Moorfields for impairment of vision. He had some corneal opacities of the left eye, of which the palpebral conjunctiva was granular (this I treated advantageously with sulphate of copper), but vision was most defective in the right eye, which six years before had been many months inflamed. He complained that everything appeared misty; still he could read with it ordinary type, or tell the time by the clock on the wall of the out-patients' room: the cornea of this eye was not nebulous as the other, or the conjunctiva roughened; but there was, near the centre of the cornea, the scar of an ulcer to which the pupil was adherent by a single band (Fig. 3. A, *a*, x,): there was also, near the centre, a number of minute brown dots on the back of the cornea (? self-detached adhesions). The existing band, which was on the inner side, opposite to the best portion of cornea, I detached with the spatula-hook at once (Fig. 3, A. *a*. x.); and on September 5th, having previously discontinued the atropine, I found

Fig. 3.

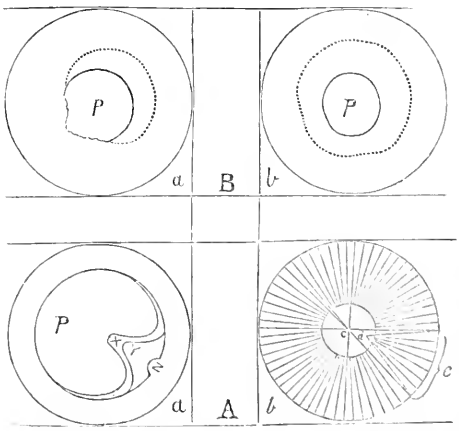

B. *a*. and *b*. diagrams of Sarah Brown's case.

a. before corelysis. } *p*. *p*. the pupil, which, with atropine, dilated to the extent of the dotted lines.

b. after the operation. }

A. *a*. and *b*. diagrams of James Harrington's case.

a. (*p*. the pupil, under atropine). x. the adhesion to the cornea, which, as soon as it was detached, retired to y. and, *after some time*, to z.

b.-*c*. the centre of the pupil, to or from which, normally, *dilated or contracted*, all the iris-fibres seem to tend. *d*. the abnormal, eccentric point to which the fibres *e*. are directed, and which, *after the operation*, moves with them.

the pupil act well, altogether free from adhesion and circular, with a prominence at its margin, indicating the retracted band (Fig. 3, A. *a*. z.). His vision was clearer, and he read the smallest type with the eye operated on.

I suppose this case, considering the obstruction of the dots on the back of the cornea, was as good a restoration as could be. The band was behind the clearest part of the cornea, and dragged the iris forwards on that side, so as to make the pupil oblique, and limit it to the more obscured part of the cornea.

Sarah Brown, aged 30, needlewoman, had had iritis, probably syphilitic. In the right eye she had intermitting dead pain when attending closely to her work or in a strong light: one-third of the pupil at its lower and outer part was bound to the lens (Fig. 3, B, *a*), the remainder dilated well when shaded or with atropine applied: she had no complaint of her vision. On September 29th, 1859, I detached the adherent part of the pupillary margin with the spatula-hook introduced at the opposite side of the cornea and once passed quickly round under the iris and between it and the lens-capsule. On October 10th, the pupil was all free; its circumference was somewhat flattened at the part which had been adherent; but it was now almost circular and dilated and contracted well, almost equally well, at all parts (Fig. 3, B. *b*). When she first came she could see well with the eye impaired, but only at short distances, *e. g.*, she could only tell the time by a watch held within ten inches of the eye, but, after corelysis, she could tell it at twenty inches distance. As to one of the chief reasons for which I had operated, the pain, I found she had none of the occasional attacks which had so much hindered her work: she had slight conjunctivitis for some weeks after the operation but when she shaded her eyes from direct light as I recommended, she could go on, as it was necessary in her employment, continuously: she continued to attend for the conjunctivitis, which was followed by obstruction of some of the Meibomian follicles, and when this was remedied and her general health improved, she came no more to the hospital.

This patient could never well describe her symptoms, and the inflamed state of the conjunctiva, and especially of the inner surface of the lids, caused pain *after the operation*, which I thought might be due, in some degree, to the diseased state of that part of the iris I had freed from the lens and therefore I had contemplated excision of so much of it, but hesitated, because her vision was so good, and it would have made so large an aperture in a very unfavour-

able direction downwards: the pupil was perfectly free, there was no ciliary redness or abnormal tension of the globe, and until my care was directed more especially to the lids inflamed with accumulations in their follicles, I had tried to explain the pain remaining, by the imperfect contraction of the pupil (which, though free from adhesion, was lymph-bound) in attention to her work: the pupil, in this case, having become adherent when half dilated, not quite contracted, as in most instances.

Martha Lane, aged 14, December 5th, 1859, "Leucoma, with anterior synechia of both eyes:" this had been so since infancy: the corneal opacities were small and placed a little to the lower and outer side of the axis of vision of either eye: there was also a symmetrical adhesion to them of the pupils, which, when they were contracted, were thus brought forwards close behind the specks, and so she saw very little: the left corneal patch was the largest but least opaque, and with this eye her vision was most defective, hardly enabling her to tell the time. The adhesions were minute points at which the irides could not retire from the cornea. I detached both, they were very elastic and would hardly give way in the hook of the spatula but with a slight rotation of the instrument in the anterior chamber: the pupils were perfectly freed as the after-operation proved, but the appearance was very deceptive, as the pupillary tags floated up and projected forwards at their places as the iris there had done for so many years. Vision was much improved, for instance, with the worst (left) eye she could read small print under favourable circumstances. On February 6th, 1860, she came again to the hospital: the eyes were in the state I had left them: there was no iritis or any adhesions but the old corneal opacities interfered with vision when the pupils were contracted, and she hoped her sight might be yet more benefited. I did iriddesis alike in each eye downwards and a little inwards: that is, most in the downward direction, away from the opaque parts of the cornea. On March 12th, I found her (elongated) pupils were equal in size, symmetrical, and unobstructed: her vision was again improved, but the left least so, now because two minute hazy specks are made visible in the cornea, to the lower and inner part of it, before the pupil made by the iriddesis-operation.

This case shows how corelysis may precede operations for other diseases, besides cataract. In the case last but one quoted, I contemplated iridectomy after corelysis and in this, iriddesis, in so favourable a direction, could not have been done, if I had not first detached the pupillary adhesions.

Charlotte Davis, aged 22, came to the Hospital October 13th, 1859. When two years old she ran a scissor-blade into her right eye: her mother

did not know what she could see after this accident, and the vision she had of this eye had been of little or no use to her as long as she can remember. The eye was of normal tension, etc., but the pupil was a small narrow chink of an horizontally-placed hour-glass shape, so confined by two points of adhesion, one at the upper margin of the pupil to a minute speck near the centre of the cornea, and the other at the pupillary lower margin to the centre of the lens-capsule; thus the bistorted pupil was confined and dragged very much forwards above to a prominent cornea, and at the lower part very much backwards to a capsule which had retreated, the lens itself having been removed by solution-operation of the accident-time.

(1. The *front view* of the iris and pupil.

2. The *side-view* of the same.

3. The same *seen from below.*)

Fig. 4.

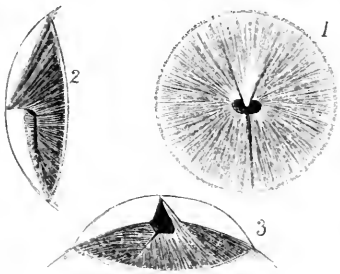

The remains of the lens and lens-capsule were little opaque; the pupil was of course larger the more it was viewed from below; and, with this eye, she could see large objects, but only then, as might be expected, their shapes in a good light, and when held very much downwards, whereby she could look under the anterior synechia, which was the upper one, and over the posterior synechia, which was at the lower part of the pupil. I, with all the operative preliminaries, passed the spatula-hook through the pupil, around the posterior adhesion at its outer side to detach it, but it was so elastic and the remains of lens-capsule, to which it was attached, was so moveable *with* it, that, not having done it, before the aqueous humour had all escaped, I desisted. On the 20th, I again entered the broad needle at the corneal margin, and, with it, divided the anterior adhesion: some bright blood immediately flowed down over the iris and became lodged at the bottom of the anterior chamber, and as, in consequence of this, I could not very well see the pupil, I again desisted. On the 24th, I did that by which I had meant to complete the last operation. The blood had been absorbed, a speck remained on the back of the cornea where the adhesion had been, and the pupil I found, free as to the upper part, exposing, with an irregular margin, remains of lens-capsule, etc.; but no part quite clear that was not so before the anterior adhesion was divided, so that she still had vision only of large objects with this eye, but it was not necessary that they should be, as before, below its level. I passed in the cannula-scissors and one blade behind and below the (posterior) adhesion, which was all at one point, and so was easily severed at once: the lower part of the pupil which had been retracted to the shrunken lens then came forward to the level of the upper part, which, having been let go, by the former operation, from its adhesion anteriorly, had gone backward into its place. On the 31st, the eye had been painful, the pupil was occupied by iritic effusion; and the patient would leave the hospital. I never knew if the

pupil eventually cleared, or if vision was improved finally, for she did not come again to the hospital.

I have quoted this case because of its singularity, although it is so incomplete, and because some facts may be learnt from it: how difficult, for instance, it is to free the pupil from a posterior adhesion at the place of its attachment when the convex surface of the lens is lost, because it is unsupported,* and has receded, etc. I think it would be best in any case of adhesion to the cornea and to the lens, both for corelysis, that the latter should be first done, as the former would tend to remove the pupil from the lens to which, soon after detachment, there is so much predisposition to a re-adhesion.

P.S.—With another case, I will append a few remarks on extraction of cataract with adhesions of the pupil, especially to note a step preliminary to the removal of shrunken lens-capsule, with some remains of lens, in case of a long-precedent wound of the lens. I have alluded to cases of extraction through a closed pupil or one at some parts adherent to the cataract, cases in which the lens is simply opaque besides having pupil-adhesions, in which the operation is altogether clearly indicated and rather easily done, but the treatment of old traumatic cataracts is, at least in my opinion, much more difficult to be determined upon and pursued without some results which appear very dangerous or fatal: in the case I am supposing, the anterior and posterior parts of the lens-capsule, probably enclosing some opaque lens-matter, are in apposition or approximated with possibly at some part adhesion of the pupil: as in the last case I have given, this pupil-adhesion is not, like others, a simple attachment, but the pupil is there involved in the scar of the wound, and so, for one reason, the broad needle that is used, should be made to cut through it at its distal extremity instead of deferring it to the spatula-hook.

* This has much to do with many iris-operations, as in the case of iriddesis, at page 152, of the present volume.

Ellen Maclellan dressmaker, aged 18. On February 29th, in the present year, I operated on her right eye. When three years old, she was cutting card, her hand slipped, and the point of the small knife she was using ran into the eye: the remainder of the history given by her mother, was only that the eye was bloodshot for about a week and then it got well, but that she could not see and something grew over it: the doctor used lotions and other remedies but no operation had ever been done. She could tell light from dark with this eye but no shapes of objects: her mother said she was not to be depended on in placing things about the room, she put everything askew, that, for instance, she would put down her tea-cup just on the edge of the table and think it was right and safe. The appearance of the eye before the operation, the shrunken lens-capsule, and white remains of lens, to which at one part (probably that of the knife-wound) the iris was retracted and bound down, is best given by the sketch I made as it then was, after applying to it atropine, I entered a small broad needle, as it had a cutting edge, at the outer and lower side of the corneal margin, passed it across the pupil and carefully divided the synechia as close as possible to the cataract, no bleeding occurred, and with the same needle I loosened the shrunken lens-capsule, etc., according to a plan I had determined on,—I passed the needle's point outside the margin of the lens-capsule at some one place and carried it inwards thence, detaching it insomuch from its marginal connexions with the ciliary processes (diagram *a*, Fig. 6,) again and again I did this with the instrument at different parts of the definite circumference of the flattened lens, thus progressively bringing it towards the centre of the pupillary space; then I withdrew the needle, enlarging at the same time the corneal opening a little for the extraction of the shrunken lens, which I did next with cannula-forceps and without any difficulty or any injury, immediate or remote, as it was released from its old connexions. On April 17th all ciliary redness had disappeared, the pupil was clear and free, the iris acted well excepting at the part where it had been confined: *without a lens*, she could tell the time by a small watch, when held close to her: the eye looked natural, as the pupil was bright, although it was still lengthened horizontally: her mother said she used to have occasionally a *cast*, but, at this time, the eyes certainly moved together; and she also said her daughter no longer miscalculated distances and the position of objects: the patient herself remarked that she used to hold her work very much to her left side, but, since the operation, she could see it well straight before her.

Fig. 5.

In operations generally on old remains of lens-capsule, etc., in the pupillary area either long after operation for

cataract or wound of the lens, I have learnt to fear especially two consequences that are not uncommon or inconsiderable; either the protrusion of the vitreous humour into the pupil, through the opening made, or chronic inflammation in the ciliary region, perhaps consequent upon or coexistant with the former, or, as I have thought, by dragging upon the suspensory ligament: both of these ill-results may occur; the former on account of the transparency of the vitreous humour is often not known to have happened, and the latter is only manifested some time after the operation: once lately I discovered that the former had taken place by the bleeding which occurred from (?) the ciliary processes: the blood filled the empty aqueous chamber except in the centre, where the vitreous had come forward and was pressed against the back of the cornea (I had torn open, with two needles, some remains of capsule, left in the pupillary area, after extraction of cataract), the blood surrounded the vitreous as a red ring before the iris, and through the centre of the cornea, the clear vitreous humour and the pupil "opened out," the patient saw at that time very well. To obviate this projection of the vitreous humour into the aqueous chamber, which some have thought to be actually advantageous, when a false membrane (lens-capsule, etc.) is rent, as in the case I have just mentioned, the needles should not be passed farther than is just necessary through the membrane, or it should be divided with cannula-scissors: it should not be lacerated very extensively, or repeatedly, and in the cases also of old traumatic cataract (remains of lens and lens-capsule) once operated on, it is best to be satisfied with a fair result for vision although some portions remain in the pupil which might be removed; because these portions of lens-capsule, etc., after extraction or wound of the lens are *held in the ciliary region, by means of the* (*suspensory*) *ligament*, which has been perhaps confirmed and toughened by the former operations, and in their removal the vitreous humour is always likely to come forward, and perhaps also irritation of the ciliary body is induced. Considering this to be so,

and the ill-results there have been, I devised the method of tearing through the ligament *in detail, before* attempting the removal of the obstructing lens-capsule, etc., it is obvious that if it is seized at once by the forceps, as it has been usual to do in these cases, the instrument has one-half, more

Fig. 6.

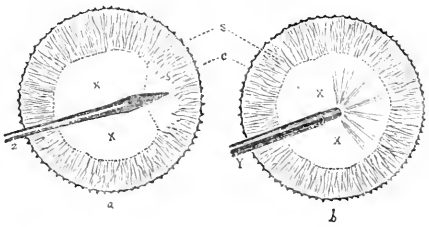

Fig. 6. *c*, ciliary processes; *s*, suspensory ligament; *x x*, *x x*, shrunken lens-capsule, remains of lens, etc.

a, shows the manner of separating with the needle (*z*) the lens-capsule at its margin, in detail.

b., shows how advantageously the cannula-forceps (*y*), are *opposed* by the retaining influence of the suspensory ligament, in such a case as the foregoing.

or less, of the suspensory ligament opposed at once to its traction and acting very favourably *against* the removal (diagram, *b*, Fig. 6,) thus in fact, it is well adapted to support the healthy lens, and as I have said, it is, in an abnormal state, probably strengthened; however, with force applied at some one part of the ligament it is easily there torn through and the needle-point will effect this at various parts, and so entirely separate the lens-capsule, etc., and leave it to be removed with the cannula-forceps, with little disturbance of the vitreous humour and without irritation of the ciliary body. In other surgical operations the *gradual* separation of parts to be removed is the rule whenever it is applicable, and in ophthalmic surgery it is often to be followed: the iris itself must not be dragged upon to a great extent at once; and so, in corelysis, as I have said, I have always avoided its ciliary separation (iridodialysis), or any laceration of its substance in detaching the strongest adhesions of the pupil, *by taking them in detail.* See paragraph 15.

REPORT

ON CASES OF CATARACT TREATED BY "LINEAR EXTRACTION," AT THE ROYAL LONDON OPHTHALMIC HOSPITAL, FROM APRIL 1857, TO MAY 1860.

By Dr. Bader, *Curator and Registrar.*

The term linear-extraction has been substituted for that used by Mr. Gibson of "extraction of cataract through a small puncture in the cornea" (see page 103, of his "Practical Observations on the formation of an Artificial Pupil," etc., London, 1811).

The numerous cases (112), to facilitate the Report, have been subdivided into cases of—

congenital cataract, (32 cases);
cataract of *various* origins, (19 cases);
cataract in secondary and hereditary *syphilitic* persons, (16 cases);
traumatic cataract, (45 cases).

The Report is confined to the operation and its complications, and only gives in outline its results as to vision, etc.

The technical part of the operation (which in several points differs from that performed by Mr. Gibson), has repeatedly been described; it will, therefore, be sufficient to enlarge upon the accidents which have happened, during and after the operation, and to mention the remarks respectively made by the operators at the time.

The youngest of the 32 *cases of congenital cataract* was 3 months, the oldest 30 years of age: the form of cataract exactly coincided in both these cases, in both the central portion of the thickness of the lens was opaque. The opacity had a conical shape, its apex apparently (O.S.) resting on the inner anterior and its base on the inner posterior surface of the lens-capsule. This opacity had in the younger case a pale grey opaque, in the older a chalky white opaque appearance, and in the latter case there were a few peripheral striæ. The cataract was confined to one (L) eye in one case, in it the central portion of the lens was faintly grey and opaque.

An equally grey-white, round flat opacity on the anterior central surface of the lens was observed in 12 cases, a similar one on the posterior surface of the lens (in the hyaloid fossa?)

in 2 cases. Numerous small dots of white-grey opaque colour sprinkled in the anterior surface of the lens existed in 6 cases.

A central grey-opaque dot, at some distance from the transparent surface of the lens in one case, and a flat, equally grey opaque lens in 5 cases, was noticed.

Both eyes were operated on in two-thirds of the cases, and simultaneously in most: one eye only was operated upon when the vision of the fellow-eye appeared still to be satisfactory.

Vision of the eye operated on was restored in from two to six months after the operation. The escape of vitreous, posterior or anterior synechiæ, repeated linear-extractions of remnant lens-portions protracted the recovery of the cases. Chloroform was given in most cases: the straining accompanying it was, in 2 cases, followed by escape of vitreous, in one by bleeding into the anterior chamber: the blood was at once removed, so as to prevent its clotting.

Repeated operations with the small needle in a few cases, preceded the linear-extraction. Iritis followed the operation in one case, without any final ill-result. Suppuration of one of the eyes operated on (at 9 and 4 years), followed in two cases, in both the opacity appeared to be far behind the pupil, in the posterior surface of the lens: both eyes had been operated upon as usual, the right eye in the one, and the left in the other case: the vitreous advanced into the anterior chamber, and many fragments of the opaque lens surrounded by vitreous, and receding before the scoop were left behind (an accident which sometimes has happened): pus appeared on the iris, in the pupil, and in the anterior chamber on the third day, and suppuration of the lower half of the cornea, with escape of pus from the vitreous space ensued on the sixth day: both eyes shrunk subsequently: the fellow-eyes recovered good vision. An eye with a similar deep-seated opacity (then called congenital cataract) had been dissected some time previously to the above two suppurations: it was found that the deep-seated opacity was due to an expansion of an opaque fibrous string, which, from the optic nerve and yellow spot, advanced through the vitreous space to the hyaloid fossa, where it expanded: it enclosed numerous small bloodvessels, and its presence appeared due to an arrest of development of the vitreous space, etc.: the retina readily became displaced from the choroid on dragging the anterior expansion of the string: the greater part of this eye is preserved in the Museum of the Hospital. We add the

following case, to give an idea of some of the troubles accompanying the operation—one eye only was operated upon, the small grey-white dots on the anterior surface of the lens were easily detached (as usual), with their corresponding portions of capsule, when touched with the needle, and the remainder of the anterior surface of the lens was broken up: linear-extraction was performed a week afterwards, and in another week the patient was dismissed with an active pupil and with a small quantity of grey lens-substance behind its area. One month later there existed extensive posterior synechiæ: these were broken through with the small needle: numerous grey opaque flocculi of lens-substance were observed a fortnight later in the pupillary area and in the anterior chamber. A second linear-extraction was performed. The following was the state of the eye after another week: a large anterior chamber, the iris pushed backwards, the pupil glued to the capsule, its area contracted and fixed but clear. A month later the adhesions of the iris were broken through with two needles, after which the iris resumed its normal position, though it remained tremulous. Small bits of lens-capsule, enclosing opaque particles of lens-substance, remained attached to the pupillary margin, without materially impairing its movements.

An active, clear pupil, a normal anterior chamber and good vision were the final results of the case.

19 *Cases of Cataract of various origin* in middle-aged persons.—No cause could be traced in 13 of these cases: in 12 of them it was confined to one eye. In 2 cases it appeared during a voyage in the tropics: of these it was, in one, accompanied by flashes of light, hemorrhage into the vitreous space and partial displacement of the retina. In one case it appeared (in one eye) after continued work at gold, pearls, etc., and in another it was ascribed to numerous attacks of ophthalmia, which for fourteen years returned twice at regular intervals in both eyes, and which in one eye became complicated with cataract: the patient, a girl of 19, stated that the attacks of ophthalmia began after vaccination, when 5 years old. One case of cataract which followed repeated attacks of bronchitis, was complicated with results of choroiditis (synechiæ, yellow fluid in the aqueous chamber, etc.): it was first broken up with the needle and then removed with the scoop: the operation was followed by an attack of iritis, and vision finally was slightly improved.

The lens had a uniform light-grey opaque (soft) appear-

ance in 12 cases: the tension of the eye, and the size of the anterior chamber offered no peculiarities. In 5 cases the lens was swollen, and the iris bulging forwards: in these the lens had a greyish translucent appearance, and was overlaid by silvery-white opaque peripheral striæ.

A grey opaque lens nucleus, with peripheral grey opaque striæ, the intermediate lens-substance being transparent (left eye), was observed in a woman (aged 44), whose sight began to fail some time after she had left off suckling: there was sugar in the urine at the time. The opaque nucleus, on breaking up the surface of the lens with a needle, advanced into the pupil: it did not create irritation, and was, with the remainder of the opaque flocculent lens-substance, removed three days later by linear-extraction: the eye recovered well from the operation.

All the greyish translucent lenses escaped readily: the average time of recovery of sight was from 4 to 6 weeks. Repeated operations were required to remove the grey opaque more glutinous lenses: the average time of recovery of sight was from 6 to 10 weeks.

The girl, in whom the cataract formed a complication of the attacks of ophthalmia (following vaccination), recovered useful vision after a good deal of trouble: the first operation (linear-extraction), was followed by a severe attack of ophthalmia: leeches were applied three times within a fortnight: the vitreous advanced into the anterior chamber after a second linear-extraction (14 days after the first): it receded spontaneously, leaving the pupil clear and (after 8 weeks) moveable, without posterior synechiæ: tenderness on pressure on the ciliary region, continued for two months, when vision was already becoming useful.

Cataract in Syphilitic Patients.—11 of the 16 syphilitic cases had the typical marks of *hereditary* syphilis: the patients were between the ages of 8 and 17: the remaining five cases were suffering from *secondary* syphilis during which the cataract began: in 4 in both, and 1 in one eye: in four cases the lens had a uniform grey opaque colour: in the fifth case a tripartite grey opacity was at first observed on the middle of the anterior surface of the lens, this opacity after the third visit of the patient had extended over the anterior surface of the lens, and was in appearance similar to that of the other 4 cases.

In the hereditary syphilitic cases, small superficial portions

of the lens appeared chiefly altered, the bulk of the lens being either transparent or very faintly-grayish opaque (admitting of a fair illumination of the vitreous space); but the portion of the lens nearest the anterior capsule being sprinkled with one or more minute, chalky-white, or silvery-white, or gray-opaque, very small round well-defined dots. Remnants of specific keratitis were observed in 8 of the above cases.

One of the cases (in a patient aged 17) was complicated with elongation of the eye backwards (the fellow eye being myopic); the lens was opaque, shrivelled up into a roundish irregular-edged silvery-white opaque substance: the greater part of it was removed with the cannula-forceps: the few gray opaque flocculi which appeared some days after the operation were left: the eye finally recovered useful vision. The nucleus of the lens of one of the secondary syphilitic cases fell into the anterior chamber: it caused no irritation: it was removed 2 months later. Closure of the pupil followed in two other cases: it was opened out with 2 needles. Vision was restored in these syphilitic cases in from 1 to 3 months.

In all the hereditary syphilitic cases, 2 excepted, both eyes were affected, but only those were operated upon in which the opacities in the lens materially interfered with vision. The small opaque dots above mentioned, easily detached with their corresponding portions of capsule from the surface of the lens. Those eyes, of which the bulk of the lens was only slightly opaque, made the quickest progress (*i.e.* the separation of the lens from its capsule ensued completely) of these, 3 had recovered vision 14 days after the operation. The cases in which the bulk of the lens was transparent were very troublesome: in one the operation was followed by an attack of specific keratitis, and in 3 by an attack of iritis with lymph in the iris and pupil (3 days after the operation). Softening of the vitreous, with signs of atrophy of the eye (with an attack of iritis in the fellow eye) appeared 10 months after the commencement of the iritis in the eye operated on.

Of the 45 *cases of Traumatic cataract* 16 were of long standing, *i.e.* the eyes had been injured a considerable time ago (old cases of traumatic cataract: injury at from 6 months to 25 years ago), 32 were fresh cases, the patients applying within a period of from several days to 2 months after the injury: the latter may be again divided into those in which the traumatic cataract was the only visible defect of the eye

(simple cases of traumatic cataract), and those complicated with diminution or abolition of the anterior chamber, with or without perforations of the cornea, wounds of the iris, displacement of the opaque lens, etc. Of this latter group there were 11 cases (complicated cases of traumatic cataract).

Simple cases of traumatic cataract.

The average duration of recovery of these cases was from 2 weeks to 2 months: one of the cases was 60 years of age. Iritis (serous) followed the operation in one case (recovery after 1 month); and a severe attack of ophthalmia with chemosis in 2 other cases (recovery after 5 weeks).

In one case an attempt was made to make the lens particles escape from the anterior chamber by injecting tepid water through the corneal wound: the water regurgitated without reaching the particles (recovery 1 month later).

Complicated cases of traumatic cataract.

Vision of the injured eye was lost after the operation in 2 cases (subsequent shrinking without any active inflammatory symptoms): the others recovered within 2—4 months.

The lens had been dislocated in one case: its lower margin projected into the pupil. The preliminary needle operation was followed by sickness, vomiting, and pain in the eye: these symptoms at once subsided after linear-extraction.

No anterior chamber existed in 8 cases: in 4 of these the cornea had been perforated by foreign substances: the swollen lens appeared in the other cases to account for the loss of the anterior chamber: the chamber was in all cases restored within a week after linear-extraction: in 7 it was filled by aqueous, in one by vitreous humour (the pupil being black, irregular, well-defined, hardly moveable, and the iris pushed backwards).

Escape of vitreous, before the lens had entirely been removed, occurred in one case (recovery).

Old cases of traumatic cataract.

In most of these cases the lens had shrunk to a flat gray opaque, or to a dead white opaque flat substance: it assumed a flocculent appearance after having been touched with the needle: in most cases the capsule was found to be very tough: the patients (3 excepted) recovered useful vision in from 3 weeks to 3 months.

Vision was but slightly improved in a case of myopia (at the age of 34), in which the eye had been injured by a blow 4 years previously: vision became gradually misty. The surface of the lens was sprinkled with minute gray opaque

dots and with numerous peripheral striæ. The vitreous at once advanced into the anterior chamber after escape of the aqueous, displacing the opaque lens-particles behind the iris. A week later the aqueous was found to be slightly yellowish, and the pupillary area occupied by the gray opaque lens-particles: most of these were removed by a second linear extraction, though the vitreous advanced again, closing round the scoop: the vision of this patient was finally improved.

In another case (suffering from consumption) in which the eye had been injured 4 years previously by a blow, the lens had a dirty gray yellow opaque appearance: it became flocculent after having been touched with the needle: only a few flocculi escaped during the operation, the bulk of the lens sinking back into the vitreous chamber: some of the yellowish slightly viscid vitreous (?) escaped. No irritation followed: the flocculent lens had risen again behind the pupil: it was brought forward with the scoop, and was then removed by an enlarged incision in the cornea.

In a third case (injury, blow 1 year before), the hard nucleus of the lens was (enclosed by gray opaque lens-substance and by a tough lens-capsule) crushed with the cannula forceps, and, like the remainder, removed through the small incision in the cornea.

Traumatic cataracts, with abolition of the anterior chamber, and soft cataracts, where the lens was grayish and translucent (so that one could see into it to a certain depth) were the most satisfactory cases. The former, because the anterior chamber was speedily re-established; the latter, because the lens-substance escaped readily, and only very slightly adhered to the capsule.

The degree of inflammation, which followed linear-extraction, appeared to be more severe when the more healthy lens-substance had been displaced or left behind. The posterior synechiæ, and the irregularities and impaired movements of the pupil, disappeared in many cases after a considerable time.

The operation was repeated 2 or 3 times, at intervals of from 3 days to 2 weeks, on eyes, in which the quantity of opaque lens-substance appeared to justify such proceeding. In some cases (of children) the lens-capsule also was removed with the cannula-forceps: in others, only as much lens-substance was allowed to escape as would readily come out by making the corneal incision gape, on withdrawing the broad needle. The escape of opaque lens-substance was facilitated by

gently pressing with the forceps, with which the eye was fixed. The eye was closed for a minute and gentle friction applied to the lid, when lens-substance had been displaced behind the iris towards the ciliary processes: this, in some cases, succeeded in bringing it forwards into the anterior chamber.

Suppuration in the tract of the puncture in the cornea has been observed in 2 cases (with subsequent small opacity) and a deposit of small particles of lime at the bottom of the anterior chamber in 2 other cases.

Spontaneous bleeding, from the anterior surface of the iris, occurred during the operation in 2 cases (followed by recovery). Prolapse of the iris by the incision into the cornea occurred in 7 cases: the prolapse receded spontaneously in 1 case, and on exposure to light (some hours after the operation) in 2 cases. Bulging of the iris, after the corneal incision had healed, was in 2 cases caused by lens-particles behind the iris.

Adhesions of detached portions of lens-capsule enclosing opaque lens-particles, or of the latter alone to the pupillary margin, without materially impairing the movements of the iris, were observed in five cases.

More or less extensive adhesions between the pupil, or the posterior surface of the iris and the capsule (posterior synechiæ) have occurred in two-thirds of the cases. The fluid which fills the anterior and posterior chambers after linear-extraction appears in these cases changed: it becomes more glutinous, and the capsule being in contact with the iris, becomes glued to it. Part or the whole of the posterior chamber may thus become excluded from the anterior, and bulging of portions or of the entire iris, by fluid, or by retained lens-particles, etc., may occur. It is desirable that these synechiæ should be divided.

Attacks of iritis, or of severe ophthalmia, were treated by leeches, instillations of atropine, cold and rest. In a very few cases only the whole of the lens was removed by the first linear-extraction: in some cases of traumatic cataract (judging from what had escaped) as much as two-thirds of the lens were left, in others a whole segment of the lens, in others the part nearest the posterior capsule or near its periphery. In three cases the central portion of the posterior capsule became glued to the rent in the anterior, and the latter to the pupillary margin, thus excluding the posterior chamber as well as enclosing lens-substance in its peripheral parts.

Such accidents account for the appearance of opaque flocculent lens-substance after the capsule had been opened

with needles. The capsule, when opened with the needle, curls in towards the lens, and transparent lens particles or grey ones, which have not yet separated from the capsule, remain enclosed, and subsequently form one kind of what is termed a false membrane behind the pupil.

An accident which frequently complicates the operation is the protrusion of what is termed the vitreous humour. Straining of the patient during the operation, wounding of the posterior capsule, too sudden escape of the aqueous, etc., may lead to it. It may be recognized by the pupil becoming suddenly clear (black). The vitreous either advances to or through the pupil, or even escapes through the corneal incision; thus it may displace the lens particles behind the iris or into the anterior chamber, and prevent their escape, and by its viscid state and the elasticity of the individual portions which close round the lens particles, it may frustrate all attempts to remove them at the time.

In three cases, in which most of the lens had been removed, the vitreous came forward and displaced the entire capsule towards the inner posterior margin of the pupil: the capsule became adherent to it and finally led to contraction and irregularity of the pupil. It has happened in traumatic cases, where probably the suspensory ligament had been ruptured and the consistence of the vitreous been impaired, that the latter escaped before any lens could be removed: in one of these cases where this could be anticipated, the lens was fixed with the sharp hook and removed with the scoop by an enlarged corneal incision. The vitreous, with few exceptions, receded behind the pupil in about half an hour after the operation. The aqueous humour (probably overcoming the elasticity of the vitreous) fills the anterior chamber, and the lens particles, which had been displaced behind the iris, reappear in the pupillary area.

An irregular large pupil, caused by the protrusion of vitreous (the pupillary margin being tugged backwards), was observed to continue for four months without producing any other irritation than a slight degree of photophobia. A similar state continued for one month in another case: it subsided spontaneously. Adhesions of the pupillary margin to portions of vitreous were observed in a third case. The movements of the pupil are impaired by the elasticity of the vitreous occupying its area. Displacement of the pupil towards the corneal incision by filaments of the vitreous which protruded through the corneal wound has been noticed in a few cases.

REPORT

OF RECENT GIFTS TO THE ROYAL LONDON OPHTHALMIC HOSPITAL LIBRARY AND MUSEUM,

By Dr. Bader, *Curator and Registrar.*

TO THE LIBRARY.

By Professor Von Ammon,

1. Von Ammon's Acyclia Irideremia, und Hemiphakia Congenita, 1858.
2. Von Ammon's Zur Beantwortung der Frage Giebt es eine organische Verbindung zwischen der innern Fläche der Corona ciliaris und dem Linsenkapselrand.
3. Von Ammon's Zur Genaueren Kenntniss des Nervus Opticus, namentlich dessen intra ocularen Endes, 1860.
4. Von Ammon's Beitrage Zur Pathologischen Anatomie des intraocularen Sehnervenen des behufs der ophthalmoscopischen Diagnose von Krankheiten des Augengrundes.

By Dr. Turnbull, *of Philadelphia,*

1. Turnbull's Clinical Medicine and Surgery of the Eye, 1859.
2. Turnbull's Clinical use of the Ophthalmoscope, n.d.

By Mr. Harkness,

1. Béraud's Cathétérisme du Canal Nasal, 1855.
2. Béraud's la Tumeur Lacrymale, 1855.

By Mr. Critchett,

Sichel's Iconographie Ophthalmologique, v.y.

TO THE MUSEUM.

By Mr. Windsor, *of Manchester,*

A Tumour (fibrous) removed from the sclerotic.

By Mr. Woolcott,

An Eyeball (tubercular).

By Mr. White Cooper,

An Eyeball (gun-shot wound).

By Mr. Holthouse,

An Eyeball.

By Dr. Bronner,

An Eyeball.

1

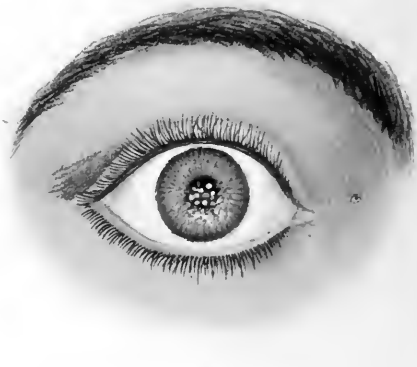

2

3

4

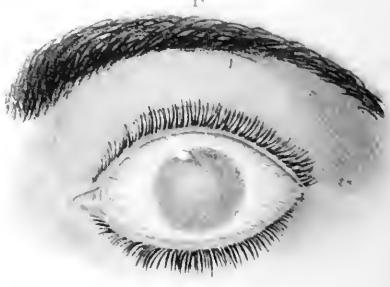

5

PLATE X.

Illustrates Mr. Hutchinson's Papers on Hereditosyphilitic Inflammations of the Eye.

Fig. I. Shows a condition of extreme congestion and blood-staining of the structure of the cornea. From a case of peracute keratitis, in which softening was threatened in the centre of the corneal disk.

See case XLVIII, p. 79.

Fig. II. Dots of earthy deposit in the posterior lamina of the cornea,—the result of a bygone attack of inflammation.

See case III, p. 280.

Figs. III & IV. Two eyes from the same patient. (Case LV, p. 85).

The sketch was taken two years after the attack of keratitis. In each eye the substance and posterior layers of the cornea are seen to be occupied by a dense deposit of grey-white lymph. The front surfaces of the corneæ were quite free from leucoma, and transparent, giving to the opacities the appearance of having been mounted behind thin laminæ of glass.

Fig. V. Illustrates the conditions often seen in the eyes of those who have suffered from choroiditis,—the result of hereditary syphilis.

It is from the left eye of case XIV, p. 274.

PLATE XI.

Of the upper part of the Plate the central figure—

X. Y. Z. shows the ordinary ophthalmoscopic appearance of the (cupped) entrance of the optic nerve and neighbouring parts of the case related at p. 241; in it—

X. Z. are veins, and

Y. an artery,

a. b. a long white mark, having the appearance of a separation or rupture in the red choroid.

A. the apparent alteration (of position) of the two *veins* X. Z. *in the cup,* when the ophthalmoscopic lens, in the hand of the observer, was moved upwards.

B. ditto—moved downwards.

C. „ — „ to the right (*of the observer.*)

D. „ — „ to the left „

U. shows the collapsed bloodlessness of the veins *in the cup* when the eye of the patient was *slightly* pressed upon by the observer. X. Z. the veins, Y. the artery.

V. is intended to represent the ordinary appearance of the artery in the cup and at its margin at the time when, with the pulse, it was filled. Y. the artery (X. Z. the veins).

M. a magnified (3 times) sketch of the iris and semi-transparent occluding membrane filling the pupil of the left eye, of James Mussel, see p. 335.

N. the pupil of the same eye, after the operation: the occluding membrane being retired to the outer side.

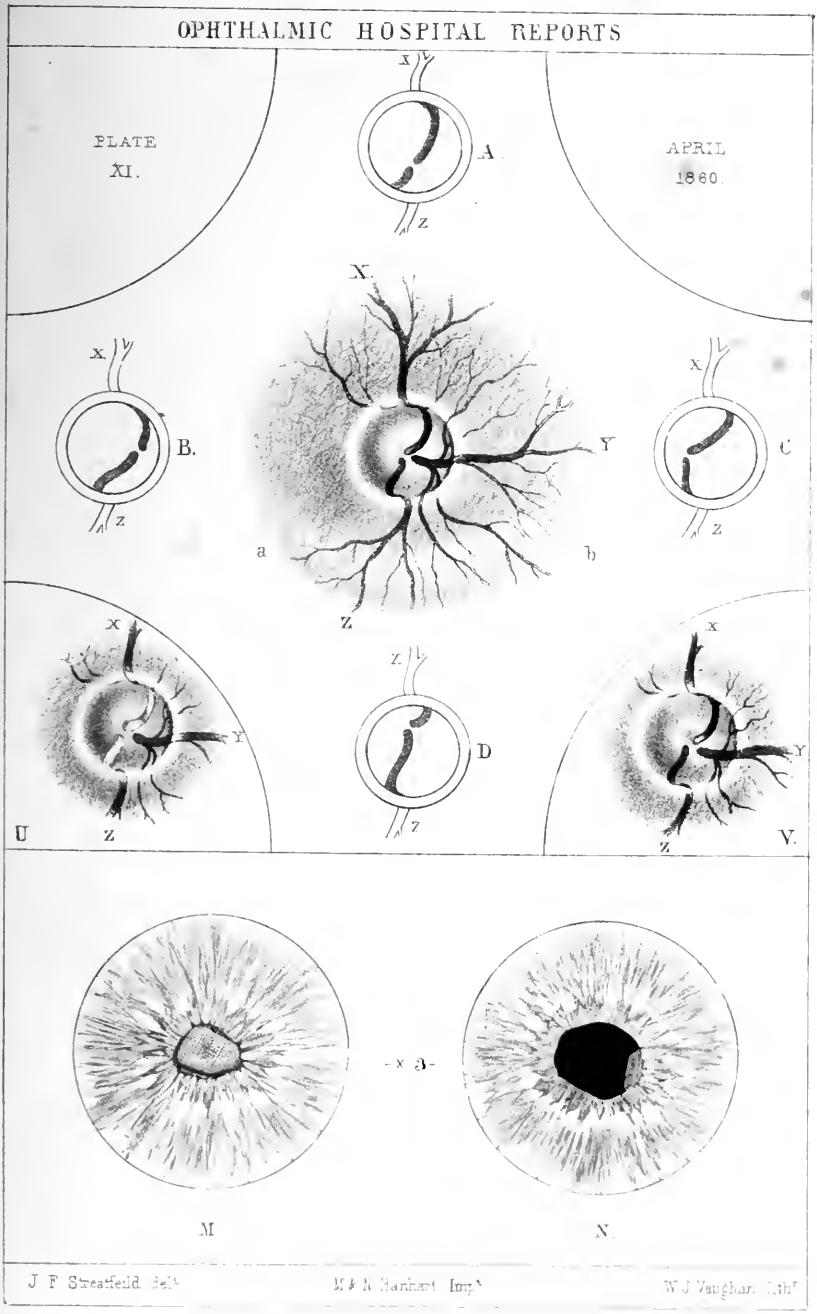
OPHTHALMIC HOSPITAL REPORTS
PLATE
XI.
APRIL
1860.
A
B.
C
D
U
V.
X.
Y
Z
a
b
M
N.
J F Streatfeild delt
M & N Hanhart Impt
W J Vaughan Lithr

GENERAL INDEX

TO THE SECOND VOLUME.

*** *The numbers refer to the pages.* O.S. *is used to indicate ophthalmoscopic.*

A.

Abducens,—see Rectus externus.
Abduction, 2—*see* Squint.
Aberration, of squinting, 135; O.S., 242.
Abscess in the orbit, 222.
Abscission of anterior *staphyloma*, 115.
Accommodation, 108, 144, 167, 199; effect of *oculomotorius paralysis* on, 197; by muscles, 197; after iridectomy, 234, 237; and pupil-adhesions, 316; after *corelysis*, 339; and movements of the *iris*, 303, 305; paralyzed, 306; practised, 306.
Adduction, 4—*see* Squint.
Adhesion, between false membrane and *lens*-capsule, 313; of the *iris* —*see* Pupil, adhesions.
Adjustment, 296, 298.
Age of patients, with interstitial *keratitis*, 94; relatively, 100; with conical *cornea*, 157: with heredito-syphilitic *choroiditis*, 276.
Alternation of œdematous *conjunctivitis*, 248.
Amaurosis, 303; cerebral, 168; spinal, 308; with excavation of the optic nerve, 241; with Bright's disease, 181, 184.
Anemia, with night-blindness, 36; O.S., 14, 228, 249.
Aneurism orbital, signs of, 6; some symptoms of, 127; supposed, 219; by *anastomosis*, 10; traumatic, 222.
Angle of squinting, primary and secondary, 135, 141.
Anterior chamber—*see* Chamber.
Apex of conical *cornea*, opaque or nebulous, 154, 155, 157, 158.
Apoplexy, capillary, retinal, O.S., 31; and contracted pupil, 19.
Aqueous, yellowish, 352; glutinous, 353; to be slowly evacuated in iridectomy, 170; drainage of, 172, 226; *exosmosis*, 158; resecreted, 354; sudden escape of the, 354.
Aqueous chambers—*see* Chamber.
Aqueous region, tension of the, 158.
Aquo-capsulitis, 102; heredito-syphilitic, 278; defined, very rare, 278.
Arcus senilis, 324.
Artery, retinal, O.S., 228, 229, 241; pulsation of the, 244, 252; spontaneous pulsation of the, 228; straight and bright red, 15; peculiarity of the, 16.
Artificial pupil—*see* Pupil.
Associated movements, 135, 140, 208, 214, 285.
Asthenopy, 106.
Atrophy, of the eye, 350; of the optic nerve, O.S., 168, 252, 253, 257; of the optic nerve and *retina*, O.S., 31.
Atropine—*see Belladonna.*
Axis, optic, O.S., 242, 243; of turning, 46, 208; of vision, 242.

B.

Babbage's rules of typographical perspicuity, 117.
Bader, on *ophthalmitis*, etc., dissection, 11; on anemic state of the optic nerve and *retina*, O.S., 14; on night-blindness, O.S., 15; on inflammation of *retina* (?) and choroid, O.S., 16.
Bader's report of an excised eye, 190.

Base of a prism, 141.
Belladonna, 241; and glycerine, 314; in *iritis*, 311, 314; its action on the pupil, 19; as a cause of *mydriasis*, 303; for pupil-adhesions, 312; to detach pupil-adhesions, 312, 313; after *corelysis*, 333.
Bleeding, from phagedenic ulceration, etc., 8; from the *iris*, 27, 30, 31, 129, 164, 199, 320, 332, 336; spontaneous from the *iris*, in linear extraction, 353, from the *iris*, in iridectomy, 171, 172, 227, 228; from the choroid, in iridectomy, 169, 170, 172, 228; from the ciliary processes, 344; from the *iris*, in *corelysis*, 320, 323, 325, 341; from a point of the *conjunctiva*, 113; from a new lid, 114; in linear extraction, 347; into the vitreous space, 348—*see* Blood.
Blind eyes, 168, 170, 236.
Blindness, and contractibility of the pupil, 304; simulated, detected, 304.
Blood, subconjunctivally, reproduces squint, 106; in the anterior chamber, 27, 28, 30, 31, 245; a ring of, in the anterior chamber, 344; in the anterior chamber, a counter puncture for its escape, 171; clot, in the anterior chamber, linear extraction, 347; between choroid and sclerotic, 170; in the 'cup' of the optic nerve's entrance, 228; spots, O.S., of the *retina*, 30, 182, 183, 184; spots, O.S., of the *retina*, in *glaucoma*, 228; spots, along the vessels, O.S., 17; supply, of the eye, extra, 249; circulation of the *retina*, 13; circulation of arteries, O.S., 16.
Blow, of the eye, 245; followed by *amaurosis*, 241.
Bluish tint, of the *fundus*, O.S., 16.
Bone, lining the choroid, 190,
Bowman, on conical *cornea*, 154.
Bowman's case of signs of orbital aneurism, 6; operation for *ptosis*, 111; case of lower lid making, 114.
Bright's disease, 181; *amaurosis* in the second stage, 184.
Bruits, with signs of orbital aneurism, 7, 11.
Bryson on night blindness in connection with scurvy, 40.
Bulge of conical *cornea*, lessened, 166.
Bulging of sclerotic incision-scar of iridectomy, 226.

C.

Canals, lacrymal, passages of tears by, 125.
Cancer-cells, 121.
Cancerous ulceration at the inner *canthus*, 5.
Canthus inner, in squint operation, 107; ulceration at the 5.
Capsule, fascial, of the eye, 218; of the *lens*, *see Lens*-capsule.
Carotid, internal, compressed, 11; the common, tied, 7.
Carriage of the head, in *paralysis* of *obliquus superior*, 292.
Caruncule, 123; inflamed, 5; hidden by the *tensor tarsi*, 124, 176.
Cataract, 171, 188, 309, 323, 344; and syphilis, 263, 271, 272, 273, 277, 346, 349; congenital, 27, 106, 190, 277, 346, 347; chalky, 190, 346; unilateral, 277, 346, 348, 350; traumatic, 107, 342, 344, 346, 350, 351, 353, 354; soft, 352; tripartite, 349; displaced, 351; after suckling, etc., 349; of various origins, 346, 348; with pupil-adhesions, 342; removal of remains of *lens*-capsule, etc., 342; after *corelysis*, 316, 319; extraction, *see* Extraction.
Causes of *paralysis* of the facial nerve, 301.
Caustic for *mydriasis*, 307.
Cells, of the choroid, 265; hexagonal, O.S., 16.
Chalk, in the *lens*, 273; in the *cornea*, 281.
Chamber, aqueous, tapped, 160; lymph in the aqueous, 176; vitreous filling the aqueous, 351, 352; lime in the aqueous, 353; yellow fluid in the aqueous, 348; anterior, large, 68, 90, 263; anterior, obliterated, 191; anterior, diminished, 351; anterior, after iridectomy, 227; anterior, filled with blood, 27, 171; anterior, water injected into the, 351; foreign body in the, 246.
Chemical reactions of the *iris*, 19.
Chemosis, 176, 248, 250, 351.
Chloroform, in iridectomy, 227; in *iriddesis*, 145; in *iriddesis*, for conical *cornea*, 164; in linear extraction, 347.
Cholesterine, 190.
Chorio-capillaris, 256; O.S., 15.
Choroid, ruptures of the, O.S., 241; thinned, 265; edematous, 264;

prolongation, forms the *iris*, 20; lined with bone, 190; its state in artificial pupil, 26; infiltrated, 12, 17; encroaching upon the optic nerve fibres, 12, 17; disseminate inflammation of, 107; inflamed from *syphilis*, 258; lymph effused, 176; inflamed, fluid from, 13; in *glaucoma*, 228; its vessels, in *glaucoma*, 169, 228; O.S. in *glaucoma*, 228; elastic *lamina* of the, 265; stellate pigment of the, 265; *cicatrices* in the, 261, 262; white patches in the, 311; white and pigment patches of the, O.S., 274; white patches of lymph in the, O.S., 258, 259, 262; and *retina*, displaced by bleeding, 169.

Choroidal, redness, O.S., 17; vessels, O.S., 15; pigment, O.S., 15; pigment, its quantity, O.S., 16; aperture, 15; aperture, diminished, 13, 17; *epithelium*, O.S., 16.

Choroiditis, 258, 263, 268, 276; O.S., 16; symmetrical, 277; in early age, 282; and cataract, 348.

Cicatrix, of cancerous ulceration, 6; conjunctival, in a second squint operation, 106, 108; of the *cornea* and *fistula*, 29; in the choroid, 261, 267, 268.

Ciliary, body, inflammation of the, 345; nerves, 302, 305; nerves, compressed, in *glaucoma*, 252; processes, 343; processes, bleeding from, 344; processes, edematous, 264; processes, lymph infiltrated, 12; redness, and pupil-adhesions, 316, 317; redness, after *coredysis*, 333; region, perforated, 11, 31; region, bulging of the, 158; region, thinned, 29; region, chronic inflammation of, after removal of *lens*-capsule, etc., why, 344; region in *iriddesis*, pupil not to be extended to, 147; vessels, in conical *cornea*, 157; muscle, 18, 20, 197, 198; part of *orbicularis* muscle, 177, 179, 187; part of *orbicularis* muscle causes, and is excised for, *entropion*, 247, 248.

Circular muscular fibre of *iris*, 19.

Circulation, essential to the action of the pupil, 18; in the retinal vessels, 253; in arteries, O.S., 16; stopped, in the O.S. veins by pressure, 241.

Clot, in the internal carotid artery, veins, and sinuses, 10; in the anterior chamber after iridectomy, 171; in the anterior chamber, from *coredysis*, 325; near to vessels, O.S., 17.

Coagulum in the sinuses, 9.

Coal in the eye, 244.

Coloboma iridis, 19; congenital, 334; artificial, 334.

Colours most fatiguing to the eye, 120.

Coloured, papers, 117; glass, and diplopy, 298.

Comparative anatomy of the iris, 19.

Concavity of the optic nerve's entrance, O.S, 243—*see* also Excavation.

Congenital, *ptosis*, 111; tumour of the *cornea*, 112.

Congestion of the optic nerve's entrance, O.S., 241.

Conical *cornea*—*see Cornea*, conical.

Conicity of the *cornea*, 154, 167; arrested by a first *iriddesis*, 166.

Conjunctiva, injected, 188, 220, 245; acutely inflamed, 191; palpebral, inflamed, 5; granular, 110, 338; invaginated, 110; congested, 114; edematous, 110, 248; reddened, 248; exposed, 300; in *glaucoma*, 169, 170; catarrh of, 300; and reflex closure of the lids, 299; and caustic, 307; contracted pupil and foreign bodies, 303; its elasticity, acts as a safety valve, 226; drawn together after abscission, 115; blood beneath, causes squint, 106; covered with lymph, 130, 176; bleeding from a point of the, 113; gunpowder in the, 324; some excised, 107, 108, 109, 110, 113.

Conjunctival *cicatrix*, in a second squint operation, 106, 108.

Conjunctivitis, 339; recurrent, 251; syphilitic, 282, 283; aggravated, 250; mucous, 248, 250; slight, with much *edema*, 248.

Constriction of the optic nerve, 13, 17.

Contraction, of the *tensor tarsi*, 124, 125, 176, 180; of the *orbicularis*, 177; secondary, 141; secondary, of the inferior oblique, 294; of the *rectus superior*, 293.

Convex mirrors, O.S., 239.

Convexity of the *cornea*, 263.

Cooper, on foreign bodies in the eyeball, 188.

Corectenia, 312.

Corectomia, 312.

Coredysis, 26, 27, 309, 310; risks, 311; limits of, 313; and iridectomy, 312; instruments, 321; results, 334; cases, 335; of anterior adhesions, 334; re-adhesions after, 319,

320, 333, 337; *diagnosis*, 320; various details, 321; aqueous to be retained, 321, 322, 328: corneal opening for, 327, 329, 332, 337; corneal opening, where, 322; difficulties, 322; use of scissors, 322, 332; precautions, 317; analogy, 317; advantages, 317; often required, 319; basis, 315; marks of the detached adhesions, 315; of occluding membrane, 330, 336; favourable indications, 331; of a single band, 328; of two bands, 328; of many bands, 329; *iris* not to be stretched, 328; and after cataract extraction, 313; alternatives, 312, 313; comparative advantages, 316; cataract after, 316; how chosen, 317; dangers, 324; the operation, 326. 330; globe fixed, how, 326; difficult without the *lens*, 342; after treatment, 333.

Cornea, 169; flattening of, 197; ulceration of, 26, 108, 109, 157; suppuration of, 347; sloughing of, 157; lacerated, 188; prominent, 189; opaque, 56, 60, 154, 157, 158, 190, 245; hazy, 29, 30, 73, 79, 87, 88, 89, 90; dotted, 72, 75, 102, 227; thinned and bulging, 67, 82, 154, 158; perforated, 351: melanotic tumour of, 122; brown dots, at back of, 338: *paracentesis* of, 252; gunpowder in the, 324; opaque and *corelysis*, 320; specks of, 325: dim, 65, 68, 130; sloughy, 131: granular, 55, 69, 70; opaque and vascular, 55, 68, 70, 75; leaden, 56, 65; hazy, syphilitic, 259, 270, 275; bulged, 270; irregularly oval, 275; rough and hazy, 245; foreign body in the, 245; penetrating ulcer of, 146, 148, 149; iridectomy for a perforating ulcer, 29; shape of, after iridectomy, 227; red, 77, 79, 101, 105; pink, 88; vascular, 109, 110; dense central opacity of, 147, 148; abnormal curvature of, 295; facets of, 295; contracted pupil and foreign bodies of, 303; and caustic, 307: finely dotted deposit, of posterior layer, 278, 280; chalky white dots, 281; softening of, 158; exosmose by, 158; disinclined to bulge, 158; conical, 154; anatomy of conical, 154; conical, considerable, with opacity, 154; conical, *iriddesis* for, 27 162, 164; conical, ciliary vessels in, 157; tension of the globe in conical, 158, 166; general history of conical, 157; family predisposition to conical, 157; conical, gradual, 157; conical, how produced, 159; iridectomy for conical, 160; Tyrrell's treatment of conical, 160; conical, curvature of the *apex*, 166; the bulge of conical, lessened, 166; height of the, 46, 194, 203, 208, 214, 285; and sclerotic, tumour of the, 112; iris-adhesions to the, 309—*see* also Pupil-adhesions.

Corneal, opacities, 106, 263, 264, 276; opacity, of lead, 115; opacity, artificial pupil for, 26; *nebulæ*, 241; section, 191, 323; section, in extraction, 24, 25, 318; section, in *glaucoma*, 169, 170, 171; section, in *glaucoma*, gaping of, 172, 173; section, in *glaucoma*, heals quickly, 226; puncture, for *corelysis*, 322, 327, 329, 332, 337; opening, in linear extraction, 352, 354; opening, in linear extraction, suppuration of, and opacity, 353.

Cornecëctomy, 162.

Corneitis—see Keratitis.

Corneo-iritis—see Kerato-iritis.

Corotomia, 312.

Cosmetic squint operation, 298.

CRITCHETT—on *Iriddesis*, 145.

Crossed double images—*see* Diplopy.

Crying at will, 178.

'Cup' O.S. of optic nerve's entrance—*see* Excavation.

Cyst, sebaceous, 154; around a foreign body in the orbit, 218.

D.

Dark eyes, O.S., 16.

Deposit of lead in the *cornea*, 115.

Detachment, of the *iris*, at its periphery, 27; of pupil-adhesions—*see Corelysis.*

Deviations of the optic *axis*—*see* Diplopy.

Dialysis, 199.

Diarrhœa, scorbutic, and slight blindness, 38.

Diet, good, necessary for interstitial *keratitis*, 79, 104.

Dilatator pupillæ, 196, 198, 303.

Diphtheritic *Ophthalmia*, 130, 175.

Diplopy, 2. 4, 107, 108, 133, 136, 138, 140. 141. 144, 193. 194, 196, 200, 206, 207, 208, 212, 222, 284, 287,

290; with one eye, 324; uniocular or binocular, 139; examination of, 139: power of uniting the two images, 141; at different heights, 204; the two images converge, 196; the two images diverge, 196, 206, 212; anomalies in, 295; when most confusing, 143; how remedied, 143; when the two images cannot be united, 298; and simulated blindness, 304; line dividing it from single vision, 291; tenotomy for, 294; homonymous, 137, 196, 212, 287, 293; homonymous and divergent squint, 296; crossed, 137, 138, 143, 193, 195, 196, 203, 206, 209, 214, 293; crossed, and convergent squint, 296; slanting, 195, 213, 287, 291.
'Direct' ophthalmoscopy, 253.
Discolouration of *glaucoma*, 252.
Disk, optic—*see* Optic Disk.
Dispersed rays of light, 199, 200; excluded, 197; in *mydriasis*, 304; suppressed by the patient, 304.
Displacement of the *retina*, 12, 13, 169, 190, 228, 348.
Dissection of conical *cornea*, 154; of *glaucoma*, 229; of *ophthalmitis*, 13; of a congenital cataract, 347.
'Division,' operation, with pupil adhesions, 318.
Donders' rules of the inclination of the vertical meridian, 45.
Dots on the *lens*, of cataract, 348, 350, 352.
Double, vision and images—*see* Diplopy.
'Drilling' operation, 313.

E.

Eccentric point for *iris*-fibres, 338.
Ectropion, 109, 110, 155, 176; of the upper lid, 154; of the lower lid, 110, 299, 302.
Eczema of the lids, 112.
Edema, much, with slight *conjunctivitis*, 248.
Eggs of *phthirius*, 126.
Elastic, tissue of *iris*, 19; lamina of the choroid, 265.
Endophthalmitis, 175.
Entomological pins, 109.
Entrance of the optic nerve—*see* Optic disk.
Entropion, 108, 110; and *trichiasis*, 109, with syphilitic *keratitis*, 97; how caused, 178, 179, 247: partial, 179, 187; voluntary, 176, 186, 187; from winking, 247; skin excised for, 248; operation for, 187.
Epilepsy, 14.
Epithelium, choroidal, O.S., 16; corneal, before and after iridectomy, 227.
Equator, of the eye, 289, 170, 228, 265, 266, 280; vertical, 182.
Erectile tumour, 10.
Escharotic treatment of cancerous ulceration, 5.
Eversion, of the eye—*see* Squint, divergent; of the lids—*see Ectropion*.
Excavation of the optic nerve's entrance, O.S., 229, 240, 243, 253; with *anemia*, 228; *amaurosis* with, 241; illusions of, 242, 252; where deepest, 229; diagnosis of, O.S., 243, 257; near and distant parts of, 242; amount or depth of, 243, 257.
Excision, of *pterygium*, 114; of *rectus internus*, and *conjunctiva*, 107, 108; of the eye, 12, 31, 122, 154, 189, 263; of the eye, for *glaucoma*, 169, 170; of *iris*—*see* Iridectomy.
Exclusion of the pupil—*see* Pupil, excluded.
'Excursion' of an eye, 203, 285, 294, 298.
Exophthalmia, 222.
Exophthalmos, 200, 201.
Exosmosis of the aqueous humour, 158.
Extirpation of a cancerous ulcer, 5; of the eye—*see* Excision.
Extraction, of cataract, 26, 151, 153, 161, 167, 191, 323, 325, 344; of the *lens*, 26, 28; of a transparent *lens*, 313; for *glaucoma*, 172; through a closed pupil, 318; and the use of forceps, 20; section of the *cornea* for, 21; of cataract, with pupil-adhesions, 309, 311, 318; with pupil-adhesions or closed pupil, 342; of shrunken *lens*, 343; linear—*see* Linear extraction; of a foreign body, 244.
Extraordinary power over some muscles of the eye, 4.
Exudation, cells, 130; pellicular, 132, 175, 176.
Eye, shrunk, 132, 190, 347; wasted, 244; hard, 176; suppuration of, 244; irritation of, 244; shrunk, after linear extraction, 351; oscillating, 75, 81, 106; rolling, 260, 268; small and rolling, 71.
Eyelashes—*see* Lashes.
Eyelids—*see* Lids.

F.

False membrane, in the pupil, 28; in the pupil, make an opening, 323; in the pupil, its adhesions to the *lens*-capsule, 313; in the pupil, opening made in it for *corelysis*, 332, 336; in the pupil, find a gap, 312, 323, 332; in the pupil, diagnosed for *corelysis*, O.S., etc., 331; in the pupil, *not* for *corelysis*, 318, 319; in the pupil, one kind described, 354: in the pupil, *iris* adhesions to a, 309, 318, 330—*see* Pupil-adhesions; in the pupil, *corelysis*, 336—*see* Membrane, occluding; covering *conjunctiva*, 131, 176.
Far-point of accommodation, 197.
Fat accumulation, causing *ptosis*, 111; of tumours, 112, 113.
Fatty degeneration of the *retina*, 181; O.S., 182, 184.
Fibro-cartilage of the lid, grooving of the, 108; drawn down and forwards, 110; drawn out and upwards, 111; tumour of the, 113.
Fibrous tissue, 264; white, 112, 113.
Fifth nerve, pain of the, 113.
Fistula, of the *cornea*, 29; of the sclerotic incision of iridectomy, 226.
Fixing the eye in extraction, 33.
Flashes of light in the eye, 38.
Flocculi in the vitreous space, 13.
Focus, 154, 167; and pupil-adhesions, 316—*see* Accommodation.
Forceps, used in extraction, 20; how used, 23; in other operations, 24.
Foreign body, in the eye, 188; extracted, 244; in the vitreous space, 240; in the anterior chamber, 245; and contracted pupil, 303; in the orbit, 216; in the orbit, suppuration and ulceration from, 218.
Foreola of the optic disk, 256.
France, on the use of forceps in extraction, 20.
Freeing the pupil—*see Corelysis*.
Fundus O.S., 240, 276; its examination, 253; objects reversed, 254; after iridectomy, 228; half of it white, etc., 39; yellowish substance in the, 260; blueish-red, 15.

G.

Galvanism, its effect on the pupil, 18.
Gioppi's digital pressure of the common carotid artery, 11.
Glass, coloured, and diplopy, 298.
Glasses—*see* Spectacles.
Glaucoma, 31, 160; prognosis, 229; eyes affected are small, 229; change after iridectomy, 226; and *mydriasis*, 305; the sea-green appearance, 252; blood patches of choroid, 170; attacks of dimness, 230; which eye affected, or both, 230; one or both eyes operated on, 169, 230; iridectomy operation for, 168, 226; and the optic *papilla*, 252; acute, 168, 172, 227, 228; acute, prognosis, 169; subacute, 168, 171, 227, 228; subacute, prognosis, 169; subacute, most liable to *iris*-bleeding, 171; chronic, 168, 170, 227, 228, 229, 243; chronic, *prognosis*, 168.
Globe—*see* Eye.
Glycerine, and *belladonna*, 314; and sulphate of zinc paste, 5.
Graefe's rules for the paralyses, etc., 44; operation for squint, 106.
Granular *conjunctiva*, 110, 338.
Granules of the hexagonal cells, O.S., 16.
Grooving the fibro-cartilage, 108.
'Ground-glass' opacity of the *cornea*, 58, 66.

H.

Hair-bulbs, of a tumour, 112.
Harkness, on *Phthiriasis palpebrarum*, 125.
Height, of the *cornea*, 46, 194, 203, 208, 214, 285; of the double images, 195, 204, 209, 289, 291 293.
Hemeralopia, 37—*see* also Night-blindness.
Hemiopia, with effusion, etc., 38.
Hemorrhage—*see* Bleeding.
Hereditary syphilitic inflammation, 54, 106, 258; and cataract, 349, 350.
Hexagonal cells of the choroid, 266; O.S. 16.
Hippus, 309; treatment of, 309.
Homonymous diplopy—*see* Diplopy.
Hook, preferred for *iriddesis*, 164; of the spatula-hook, 328.
Horizontal meridian—*see* Meridian.

Horner's muscle—*see Tensor tarsi.*
Hulke, on the capital signs of orbital aneurism, 6.
Hulke's case of skin-transplantation, 110; examination of conical *cornea*, 155.
Hussey, on protrusion of the globe, with some symptoms of aneurism, 127.
Hutchinson, on hereditary syphilitic inflammations, 54, 258; on *diphtheritic ophthalmia*, 130.
Hyaloid, *fossa*, 172, 346, 347; membrane, 229; displacement, 12.
Hyperopia, 306.
Hypopion, 108.

I.

Illusions, O.S., optical, 240, 242, 252; false, 243.
Images, O.S., correct and illusory, 242; *pseudo—see Pseudo-images;* double—*see* Diplopy.
Immobility of the eye, 225.
Incongruence of the *retina*, 137, 295; and use of prisms, 297; antipathy to single vision, 297.
'Indirect' ophthalmoscopy, 253.
Infiltration of *ora serrata*, ciliary processes, and *iris*, 12.
Inflammation of the eye, syphilitic, 54, 258; destructive, 175.
Inherited syphilis and inflammation of the eye, 54, 258.
Injection of a *nevus* with tannic acid, 113.
Innervation of the muscles, 135.
Inoculation, 110.
Intolerance of light—*see* Photophoby.
Intraocular pressure, 158, 159, 160, 169, 173, 227, 257; and *mydriasis*, 305.
Inversion, of the lids, voluntary, 177, 186; of the eye, in extraction, 21; of the eye, *see* Squint; of the lashes, *see Entropion.*
Iriddesis, 26, 27, 342; a second, 27, 164, 166, 167; marginal, 165; double, 165; further remarks on, 145; its advantages, 145, 153; after *corelysis*, 340; for conical *cornea*, 162, 164; support of the *lens* wanted for, 152; loop drawn in, 153; hook preferred for, 163.
Iridectomy, 28, 160, 165, 168, 226, 241; accidents and difficulties, 169, 170, 172; results, 172, 173, 226, 229, 230; and *corelysis*, 312, 319, 320, 339; after *corelysis*, 334; a second, 173; changes after, 226; and accommodation, 198, 199, 200, 234, 237.
Irideremia totalis, 199.
Iridodialysis, 199, 345.
Iridodonesis, 309.
Iris, steel-blue, 107, 263, 275; steel-grey, 270, 278; operations, 26, 161, 312, 342; tremulous, 241, 309, 348; tremulous, of conical *cornea*, 158; dull and inactive, 245; muddy, with keratitis, 55, 102; thinned, 67, 68, 70, 71, 72, 73, 74, 75, 76; atrophied, 170, 264, 278; atrophied and dilated, 305; lymph infiltrated, 12; abnormalities of its movements, 302; and accommodation, 199, 303; soft and rotten, 150; rent in the, 152; prominent, 331; in apposition with the *cornea*, 190, 264; the nascent, 186; rings of the, 185; bound to the *lens*, 185; adhesions, 29, 188; in *glaucoma*, 169, 170; after iridectomy, 227; left in corneal wound, after iridectomy, 172; part that bleeds in iridectomy, 171; paralyzed, 191, 227; prolapsed, 151, 199, 353; *hernia* of the, 162; protrusion of the, 188; irritable prolapse of the 172; and the detection of fraud, 304; discoloured, 188; the whole removed, 199; torn out or excised, 312; not to be altogether dragged upon, 345; condensed by *iritis*, 334, 340; a prolongation of the choroid, 20; its width, 152; structure of 18; movements of, 18; cut through, 19; comparative anatomy of, 19; fibres, to be preserved, 145; fibres, tense, 152; fibres, contract with an occluded pupil, 331; fibres, after *corelysis*, 335; bulging, 349, 353; wounded, 351; tying, *see Iriddesis;* excision, *see* Iridectomy; bleeding from the, *see* Bleeding; adhesions, detached, *see Corelysis.*
Iritis, 28, 63, 102, 172, 262, 268, 273, 309, 311, 314, 339; hereditosyphilitic of infants, 94, 278; syphilitic, 316; syphilitic, best for after-*corelysis*, 331; after *corelysis*, 333, 341; after linear extraction, 347, 348, 350, 351, 353; serous, 351; rheumatic, 28; chronic, 226, 227; recurrent, 150, 319, 334; re-

currence prevented, 315; a second, from adhesions, 316; leaving adhesions, 276, 278; in early age, 282; with *keratitis*, undistinguished, 278; result of, 311; treatment of, 311; operation for false membranes from, 309, 330.
Irritation of the eye, 244; from sympathy, 264.

J.

Jago, on voluntary power of using the *tensor tarsi*, 123.
Jewish people rarely have syphilitic *keratitis*, 91.
Jones, on persistence of pupillary membrane, 185.

K.

Keratitis, pannosa, 300; strumous, 56, 94; specific, 350; syphilitic, 26, 94, 100, 103, 259, 268, 269; syphilitic, Jewish people rarely have it, 91; symmetrical, 277; with ulceration, 109; interstitial, 54. 262, 271, 273, 276, 278, 282; good diet necessary, 79; commonest at ages 10 to 15, p. 94; in girls, 94; patients are pallid or sallow, 95; their skin, coarse and flabby, 95; nose depressed, 95; face pitted and scarred, 95; upper incisors notched, etc., 96; special coincident affections, 96; brothers and sisters syphilitic, 97; infantile syphilitic symptoms, 97; syphilis in their parents, 97; their relative mortality, 99; the eldest child, most subject, 100; in four groups, 101; affects both eyes, left first and most severely, 102; clears steadily, 103; is syphilitic, 103; its treatment, 104.
Kerato-iritis, 26, 27, 67, 73, 74, 75, 76, 77, 271, 282.
Keratonyxis, 190; the use of forceps in, 24.

L.

Lacrymation, 110, 177, 245, 247; voluntary, 178, 180; with interstitial *keratitis*, 56, 62, 86, 101; but for the *orbicularis*, 299, 300; for night-blindness, 36.
Lacrymal, abscess, with syphilitic *keratitis*, 97; canals, action of the *tensor tarsi* on the, 125, 178; secretion, imitated, 302.
Lactation, inducing *keratitis*, 63.
Lagophthalmos paralyticus, 299, 300; *totalis*, 300.
Lamina cribrosa, 256, 257.
Lashes, in *entropion*, preserved, 108; transplanted, 108; removed, 108, 109; with lice, and their eggs, 126; having lice, cut off, 127; falling of the, in syphilitic infants, 283; used to replace inverted lids, 247.
Lateral, movements of the globe, 1, 4; distances, 285, 291.
Laurence—on *Hemiopia* with lymph effused, etc., 38.
Lead-deposit in the *cornea*, 115.
Lens, how supported, 345; O.S., 253; changes shape, 198; approaches the *cornea*, in accommodation, 198; luxation of the, 295; dislocated, 190, 309; dislocated, linear extraction, 351; sunk into vitreous chamber, 352; transparent, extracted, 26, 28, 313; drilled, 313; chalky, 190; evacuated in iridectomy, 172; to be cared for in iridectomy, 170, 171; removed for conical *cornea*, 160, 161; support wanted for *corelysis*, 342; wounded and shrunk, 342: shrunk, 351; flattened, 343; diplochromatic in *glaucoma*, 252; central part, opaque, 346; swollen, 349; *striæ* in the, 325; gunpowder grain in the, 325; *nucleus*, opaque, 349; crushed with *cannula-forceps*, 352; two months in the anterior chamber, 350; inflammatory opacities of, 258, 276, 277; *nucleus*, opaque, 349; shrivelled, 350; *uvea* on the, 273; yellow chalk, in the, 273; not very easily wounded, 311, 316, 324, 330; remains of, 271; O.S. biconvex, 240; O.S. illusions with the, 242; *iris*-adhesions to the, 309—*see* Pupil-adhesions.
Lens-capsule, 271, 346, 348, 352; opaque, 146, 150; thickened and empty, 264; wounded in iridectomy, 170, 171, 172; adhesions of a false membrane, 313; may be cleared, 311, 313; held by suspensory ligament, 344 etc.; re-

moved, ill results, 344; separated, for removal, 345; remains of, opened with needles, 344; opened, curls in and retains portions of *lens*, 354; etc. removed, with pupil-adhesions, 342; how to be loosened, 343; tough, 351.
Letheby—on the structure and movements of the *iris*, 18.
Leucoma, 85, 320, 335, 338, 340; central, 146.
Levator palpebræ, 128, 192, 201, 202; in relaxation, 299.
Lice, infesting the lashes, 126.
Lids, unstriped muscular fibre in, 201; made to open, after death, 202; used by patients to limit the pupil 165; folds of skin of, 247; voluntary power, over the *tensor tarsi*, 123, 176; voluntary power of causing *entropion*, 176, 186; half-closed by relaxation of the *levator palpebræ*, 299; reflex action, 299; forcibly and repeatedly closed for the treatment of *mydriasis*, 306; *eczema* of 112; swollen, 245, 248; swollen and inflamed, 130, 176; thickened, 109; edematous, 248; ulcerated, 129; unusual movements of the, 123, 176, 186; kept in place, 180; a V-shaped portion excised, 109, 155; a V-Y skin-incision, 110; everted, 176; lower, made, 114; everted, *see Ectropion;* inverted, *see Entropion.*
Ligature, for *nevus*, 113; of a melanotic tumour, 121.
Light circulation of the *retina*, 13.
Linear measurement of a squint, 136.
Linear extraction, 191; report on, 346; of one eye, 347; repeated, 347, 348, 349, 352, 353; cases suitable and not, 349, 350, 352; water injected, 351; the after-inflammation, 352; details of the operation, 352; vitreous protrusion, 353; with pupil-adhesions, 318.
Louse-crab, about the lashes, 126; fetal, 126.
Luminous rays only required for vision, 119.
Lymph, concealing the *conjunctiva*, 130, 176; in the eye, 175; punctate deposits of, in the *cornea*, 65, 73, 102, in the anterior chamber, 69, 77, 85, 101; in the *iris* and pupil, 350; on the *iris*, removed by iridectomy, 28; covering vitreous protrusion in iridectomy, 172; infiltration of *ora serrata*, ciliary processes and *iris*, 12; (?) effused and *hemiopia*, 38; patches, O.S., in choroid, 258, 259.

M.

Macdonald, on the Sun-ophthalmoscope, 239.
Mackenzie. on sulphate of zinc paste, 5; on so-called Diphtheritic *ophthalmia*, 175; on *amaurosis* and Bright's disease, 181; on *glaucoma* and the optic *papilla*, 252.
Macula lutea—see Yellow spot.
Measurement of a squint, 136.
Media, O.S., 228, 240; turbid, 169, 228; after iridectomy, 228; refracting, irregularities, 295.
Median line, 134, 285; horizontal, 208, 209, 212, 214, 285, 287.
Meibominian follicles, obstructed, 339.
Melanotic tumour (external) of the sclerotic, 120.
Membrana, orbitalis, 200; *retractor*, 201.
Membrane, pupillary, persistence of, 185; of the fetal louse, 126; false, *see* False Membrane; occluding, *see Corelysis.*
Mercurials and iodides, for interstitial *keratitis*, 104.
Mercury in *iritis*, 311, 331.
Meridian, vertical, 212; horizontal, 212, 289; vertical and horizontal, 289.
Mirror, O.S., convex, 239; concave, 253.
Moon-blindness, 41.
Motores oculorum—see Oculomotorius.
Movements, of the eye, 47; of the eye, laterally, 1, 4; of the eye, associated, 203; of the eye, vicarious, 203; of the eye, during extraction operation, 21; of the *iris*, 18, 353, 354; of the *iris*, abnormalities, 302; of the *iris*, and accommodation, 303; of the *iris*, and fraud, 304; of the *iris*, after *corelysis*, 335; of the *iris*, *hippus*, 309; of the O.S. lens, and illusions, 242; of the O.S. lens, and false illusions, 243.
Mucous membrane-like skin of folds of lid, 248.
Muscæ, 337; *volitantes*, 37; black, 270; black, O.S., explained, 275.
Muscle, plane, 46, 208, 216; paralyzed, to be strengthened, 142; inefficiency of, 143.

Muscles, paralyses of the, 44, 133, 192, 284; move the globe, 47; all paralyzed, 197.
Muscular, power, extraordinary, in the lids, 123, 176, 186; fibre, of the *iris*, 18.
Mydriasis, 192, 304, 314; spontaneous, 306; paralytic and spastic, 305; paralytic, and intraocular pressure, 305; caused by *belladonna*, 303; causes of, 305; one-sided, 306; treatment of, 306, 307.
Myopy, 38, 83, 107, 158, 178, 197, 351; and elongation of the eye, 350.
Myosis, 307; treatment, 308; unlike looking through a pin-hole, 307; causes of, 307; by reflex action, 307; (?) incise the pupil, 334.

N.

Navy, scurvy and night-blindness in the, 37, 41.
Near, point of accommodation, 197; sight, *see* Myopy.
Nebula, of the *cornea*, 241, 335, 338.
Needle-operation, 351, 354; for remains of *lens*-capsule, etc., 344—*see* Solution, Drilling, Division, etc.
Nerve, fifth, pain of the, 113; third, paralysed, 192; complete or partial paralysis of the third, 193, 196; motor and sympathetic, 196.
Neuralgia, 189, 191.
Nevus, 113.
Nictation, a slight, 180.
Night-blindness, O.S., 15; notes on, 35; causes of 36; how removed, treatment, 36, 38; feigned, 36; in connexion with scurvy, 40; and scurvy, some vision by candlelight, 42.
Nodes causing protrusion of the eye, 223, 225.
Notched lips, 107; teeth, *see* Teeth.
Nunneley, on extraction of a foreign body, 244.
Nunneley's cases of orbital aneurism, 10.
Nystagmus, 309.

O.

Obliquus, superior, 193, 194, 195, 200; *superior, paralysis* of, 212, 284; *superior, paresis* of, 287; *superior*, antagonistic of *recti*, 290; *superior, paralysis* of, *prognosis*, 294; *superior, paralysis* of, *diagnosis*, 293; *superior*, assists the *rectus inferior*, 49, 53; *inferior*, 140, 192, 208, 214; *inferior*, assists the *rectus superior*, 48, 52, *inferior, paralysis* of, 202, 211; *inferior*, secondary contraction of the, 294.
Obliqui, their anatomy, 50; move the globe, 51, 52, 134; their alternating action, 134.
Obliquity of the images, 211.
Occipito-frontalis, in *ptosis*, 201; will raise the lid, 128.
Occlusion of the pupil—*see* Pupil, occluded.
Oculomotorius, 192, 193, 196, 200, 212; *paralysis*, 291, 305; irritated, 302.
Oil-globules of the *retina*, 266.
Opacities, inflammatory, in the vitreous, 258, 276: corneal, *see* Corneal.
Operation, of extraction, 23; for conical *cornea*, 154; of *iriddesis*, 146, 153; for squint, 106; for *entropion*, 187; for *ectropion*, 110; for *trichiasis*, 108; for *ptosis*, 112; of iridectomy, 28; for removal of *lens-capsule*, etc., 343; of *corelysis*, 326, 330; incising the pupil after *iritis*, or for *myosis*, 334; in incongruence of the *retina*, 297, 298; for *paralysis* of the superior oblique, 294.
Operations, on the *iris*, 312; iridectomy for *glaucoma*, 168, 226.
Ophthalmia, 29, 149; acute, 31; peracute, purulent, 130; purulent, 61, 267, 270; purulent, corneal opacity, 26; muco-purulent, why, 283; catarrhal, 112, 171, 282; diphtheritic, 130, 175; strumous, 93, 147; chronic, 126; acute irritative, 245; and contracted pupil, 303; at regular intervals, 348, 349; after linear extraction, 349, 351, 353—*see* also *Conjunctivitis*.
Ophthalmic vein, thickened, 9; plugged, 11.
Ophthalmitis, 219; dissection of, 13; syphilitic, 258; idiopathic, traumatic, and phlebitic, 175; pyemic, 175.
Ophthalmoscope, to be used for conical *cornea*, 157; the sun, 239.
Ophthalmoscopic, appearances, 14, 15, 17, 39; appearances, of *glaucoma*, 229; appearances, of fatty degenerations of the *retina*, 182; appearances of the "cupped" optic disk, 240; parts are reversed, 242; *lens*,

biconvex, 240; illusions with the *lens*, 242.
Ophthalmoscopy, 239, 242; by the indirect and direct methods, 253; by sunlight, with convex mirrors, 239; by sunlight, with concave mirrors, 240.
Optic *axis*, 46, 134, 208; oscillates, 194; elongated for accommodation, 197; divergence of the 204; deviation of the, 135, 138, 141, 284, 293; fixing of the, 298.
Optic disk, O.S., 190, 228, 229, 252, 254, 275; anemic, 14; congested, 107, 241; red and indistinct, 182, 183; ill-defined and congested, 30; ill-defined, 274; how distinguished, 17; after iridectomy, 228; flat and well-defined, 15, 88; normal and oval, 15; normal and diseased, 256; prominent, 255, 257; irregular, 262; 'cupped'—*see* Excavation.
Optic nerve, 347; reflex action, 302; atrophied, 168, 252, 253, 257; flattened, 252; tension of the, 225; compressed and stretched, 154; fibres, 256, 266; fibres, constricted, 12, 17; fibres, pressed on in *glaucoma*, 229; entrance, O.S., *see* Optic Disk.
Optical illusions, O.S., 240; demonstrated, 242, 252, 254; false, 243; their cause, 255.
Optometer, 167.
Ora serrata, 155, 264, 265; lymph infiltrated, 12.
Orbicularis, its action, 247; its use, 123, 125, 187; voluntarily inverts lower lids, 176, 186; prevents overflow of tears, 299; insufficiency of, 300; paralyzed, 299; *paresis*, 299; and reflex action, 299; causes of its *paralysis*, 300; in *ptosis*, 201; fat causing *ptosis*, 111; in accommodation, 197; displaced by operation, 111.
Orbit, pain about, 76, 77; nodes of the, 223, 225; causes of protrusion in the, 216; foreign body in the, 216; traumatic aneurism in the 222, supposed aneurism in the, 219; signs of aneurism in the, 6; abscess in the, 222; blow received on the, 241; inflammation in the, 216; inflammation in the, to be incised, 218; diffused inflammation in the, 219.
Orbital fissure, inferior, 200; membrane, 200.
Oscillations of the eye, 260, 268, 275; lateral, 106.
Ova of lice, 126.
Ovens, on Night-Blindness with Scurvy in the Crimea, 35, 37.

P.

Pain, in the eye, 241, 245, 270; supra-orbital, 217; of *glaucoma*, 168, 170, 171, 172, 226, 227, 252.
Palpebral apertures, 248; small, 247.
Palsy—*see Paralysis*.
Panophthalmitis, 175.
Paper, coloured, 117.
Papilla, lacrymalis, inflamed, 5; optic, O.S., *see* Optic disk.
Paracentesis, for conical *cornea*, 160; sclerotic or corneal, 252, 257; for diagnosis of 'cupped' optic disk, 257.
Parallelism, 286; of the *axes*, 4; of the vertical meridians, 48, 49, 195, 203, 205, 209, 212; of the vertical meridians, destroyed, 140.
Paralysis, of the muscles of the eye, 44, 133, 192, 284; of all the muscles, 197; of the *orbicularis*, 299; of the *orbicularis* and reflex action, 299; of the *orbicularis*, its causes, 300; of external *rectus*, 2, 133, 142, 205; of external *rectus*, acute, 140; of external *rectus*, cured, 140; of internal *rectus*, 203, 206; of inferior *rectus*, 214; of superior *rectus*, 208; of the superior oblique, 200, 284; of the superior oblique, *diagnosis*, 293; of the inferior oblique, 202, 211; of the sixth nerve, 3; of the third nerve, 192; of the third nerve, complete or partial, 193, 196; of the third nerve, cerebral or peripherical, 192; of the facial nerve, 300; of the facial nerve, causes and *prognosis*, 301; causing a squint, 141; use of prismatic glasses for, 141; cured by prismatic glasses, 141, 142; of the accommodation, 306.
Paresis, 194, 287; of the *orbicularis*, 299.
'Patches,' O.S., white and brown, 107; white, in the choroid, 274, 276, 311, 317; white, of lymph in the choroid, 258, 259, 262; of pigment in the choroid, 261, 275; white, of *retina*, 268, 269, 276; black, of *retina*, 271, 275.

Pediculus pubis, 126.
Persistence of pupillary membrane, 185.
Perspective appearance of the vessels of the 'cupped,' O.S., optic disk, 241.
Phagedenic ulceration, 8.
Phlebitis of the sinuses, 11.
Phosphenes, 197.
Photophoby, 115, 239, 241, 245, 280, 354; with interstitial *keratitis*, 55, 65, 77, 86, 92, 101, 105.
Photopsia, 181.
Phthiriasis palpebrarum, 125.
Physiognomy of hereditary *syphilis*, 261, 267, 269, 276.
Pigment of choroid, its quantity, O.S., 16; stellate, 265; colour of the stellate, 266; patches, O.S., 261, 275.
Planes of the eye, meridian planes, 45; muscle planes, 46.
Plicæ semilunares, 123.
Pneumonia, 14.
Poland, on protrusion of the eyeball, 216.
Presbyopy, 197.
Pressure, to stop circulation of blood, O.S., 16, 17; causing pulsation, O.S., 241, 244.
Prisms, 141, 207, 211, 214, 216; one for each eye, 299; to detect simulated blindness, 304; practising with, 144; their strength, 142; their choice, 143; in *obliquus superior* paralysis, 292; and no diplopy, 296; and incongruence of the *retina*, 297; for incongruence of the *retina*, after tenotomy, 299.
Prolapse of the *iris*, 151, 153, 199; through a corneal ulcer, 29.
Projection of the field of vision, 285.
Protrusion of the eye, 6, 8, 11, 127, 154, 176, 201, 216, 219, 223.
Pseudo-image, 196, 200, 203, 204, 209; obliquity of, 211; appears nearest, 290—*see* Double images.
Pterygium, 113; excised, 114.
Ptosis, 8, 111, 193; when most excessive, 201; and *mydriasis*, 305; congenital, 111.
Pulsation, behind the eye, 220; in the orbit, 7, 11; of retinal arteries, O.S., 228, 252; of the vessels, O.S. 241, 244.
Pulse, O.S., 15, 244.
Punctum, slit, 109, 110; inversion of the, 178; the *tensor tarsi* inserted into the, 125.
Puncturing the iridectomy section, 173, 227.
Pupil adhesions, 73, 76, 81, 89, 170, 263, 270, 272, 273, 276, 278, 280, 309; always to be freed, 310, 311; detachment of, 309; complete, 311; prevention of, 311; taken in detail, 345; prejudicial, 315, 319; reinduce *iritis*, 319, 334; and a second *iritis*, 316; minor, 319; that may not be detached, 319, 320; cut through, 343; detached, project, 335, 339, 340; to the *cornea*, 27, 334, 338, 340; broad to the *cornea*, 320; to the *cornea*, separated, 310; to the *lens*, 26, 28, 188, 328, 337; to the *lens*, have been left, 311; to the *cornea* and *lens*, 341, 342; to remains of *lens*, etc., 342, 353, 354; (?) self-detached 338; painful, 339; involved in the scar of a wound, 342, 343; one only, bad, 316, 319; transparent, 317; detached, dots, O.S., left circularly, 315; have been neglected, 312; find an interval, 312, 329; of dilated or contracted pupils, 327, 340; use of *belladonna*, 313; remedies to be tried, 313; destroyed by *corelysis*, 315; posterior, when difficult to detach, 342; deceptive, 321; adhesions, and cataract extraction, 323; and linear extraction, 347, 348, 352, 353; and accommodation, 316; hour-glass shaped pupil, from, 328, 341.
Pupil, artificial, 26, 76, 87, 312, 315, 316, 317, 330; ill-placed, 312, 313; dangers, 325; in the place of the natural, 311; *iridesis*, 145, 153, 162; slit-like, 161, 163, 165, 166, vertical, not horizontal, 163, 165; balloon-shaped, 160, 162, 165, 166.
Pupil, reinstated, 309, 311, 315, 316; intercepts, O.S., examination, 242, 243; distorted, 341; voluntarily contracted, 180; closed, 81, 312, 320, 325; closed, after linear extraction, 350; contracted, 19, 198, 303, 307, 318; contracted, with contraction of the *rectus internus*, 303; contracted, by irritation of the fifth nerve, 307; contracted, by reflex action, 304; contracted, by forced and repeated closure of the lids, 306; contracted, adhesions of, 327, 337; oval, adherent, 149; eccentric, desirable, 319; immoveable, 20, 75, 196; immove-

able, after *iritis*, 334; with atropine, when paralyzed, 196; sluggish, 17, 30, 267, 280; fixed, 29; dilated and sluggish, 305; dilated and fixed, 184, 225, 270; dilated, 6, 8, 19, 36, 37, 40, 128, 191, 196, 201, 202, 302, 304, 314; irregular, 70, 71, 74, 275, 354; excluded, 270, 311, 313, 321, 338; occluded, 28, 67, 102, 312, 313, 317, 321, 330, 335, 353; occluded, O.S., 331, 336, 338; occluded, uveal margins, 336; occluded, *lens* transparent, 313; occluded, *lens*-capsule may be cleared, 311; occluded, find an interval, 312; occluded, cases for *corelysis*, 313; occluded, not for *corelysis*, 319; occluded, incompletely, 337; membrane in the, 270; eccentric point, 338; in *corelysis*, not to be forcibly dilated, 326; flattening, after *corelysis*, 339; shape, after *corelysis*, 335; (?) to be incised, after *iritis*, or for *myosis*, 334; displaced, 153; enlarged, 165; altered in shape and position, 145; contractibility, 18; contractile, 145, 147; active, 36, 152; its *area*, after *glaucoma*, 227; filled by the *lens* dislocated, 191: displaced by vitreous, 351, 354; contracts and dilates, 303; of conical *cornea*, large, 158; 'cat's,' made for conical *cornea*, 27; after linear extraction, 352; its structure and movements, 18; of some animals; 19; of skate, 19; of reptiles and some fish, 20; curtain-like, 20.

Pupillary membrane, 317; persistence of, 185; inflammation of, 186.

Pus, in the eye, 175; in the *cornea*, 79; on the *iris*, etc., 347; in the vitreous space, 347; corpuscles, from inflamed choroid, 13.

Q.

Quadrants of the *retina*, 196, 204, 210, 289.

R.

Radiating muscular fibres of *iris*, 19.

Re-adhesion after *corelysis*, 319, 320, 333, 337; prevented, 342.

Rectus, superior, 140, 192, 212; superior, its three movements, 47; superior, paralyzed, 208; superior, contraction of the, 293; superior or inferior can (?) move the eye laterally, 1, 4; external, 140, 143, 193; external, helps to preserve parallelism of vertical meridians 139; external, *paralysis* of, 2, 133 142; external, acute *paralysis* of, 140; external, *paralysis*, cured, 140; external, contracted, 144; external, insufficiently innervated, 135, 136; external, tenotomy of, 107, 298; external, divided subconjunctivally, 108; external, divided and eye fixed inwards, 107; inferior, 192, 286, 293; inferior, its three movements, 48; inferior, paralyzed, 195, 214; inferior, paralyzed, position of head, 216; internal, 135, 140, 143, 192; internal, contracted, 141, 144, 298; internal, stronger than the external, 141; internal, insufficiency of, 298; internal, *paralysis* of, 203; internal, paralyzed, position of head, 207; internal, contraction of and contracted pupil, 303; internal, divided subconjunctivally, 106, 110; internal, one first divided, 106; internal, some excised, 107, 108.

Recti, their retrahent action, 290; affected by galvanism, 19; superior and inferior, their broad sclerotic insertions, 1; both internal, divided, 106, 107; both external, divided, 107; internal and external, their anatomy, 49, 50; internal and external, move the globe, 50; internal and external, one pair, 46; superior and inferior, their anatomy, 47; superior and inferior, move the globe, 47.

Recurrence of *conjunctivitis*, 249, 250.

Reflex closure of lids in *paralysis*, 299.

Refraction, O.S., of the margin and bottom of the 'cupped' optic disk, 242.

Reinstated pupil—*see* Pupil reinstated.

Remains of *lens* and *lens*-capsule, 341, 342, 344.

Removal of a foreign body in the vitreous, 240.

Report, of *iris*-operations, 26; of operations for *strabismus*, *entropion*, *ectropion*, *ptosis*, tumours, etc., 106; of iridectomy operations for *glaucoma*, 168, 226; on linear-extraction, 346; of gifts to the Library and Museum, 32, 355.

Retina, displaced, 12, 348; displaced by bleeding, 169, 228; displaced and funnel-shaped, 190; how displaced from choroid, 13; hazy, O.S., 30, 88; hazy, syphilitic, O.S., 259, 264; pale, O.S., 262; anemic, O.S., 14; deposit in the, 276; loss of transparency of, 228; very vascular, 13; *hyperesthesia* of the, 307, 309; affected by scorbutic blood, 41; circulation of light, blood, etc., in the, 13; in *glaucoma* 228, 252; parts blind, 230; its state in artificial pupil, 26; lymph effused on the, 38, 176; fatty degeneration of the, 181; fatty degeneration of the, O.S., 182, 184; spots of induration of the, 184; lateral portions, best, 275; thinned, O.S., 268; black patches of the, O.S., 271, 275; white patches of the, 268, 269; (?) inflammation, O.S., 16; light concentrated on, 306; distorted 'rods' of, 265; radial fibres, *loculi*, 266; cell-layer of, 266; quadrants of the, 196, 204: incongruence of the, *see* Incongruence.
Retinal vessels, 258, 275; in patches, O.S., 268; thin and few, O.S., 15; arteries and veins, 15; tortuous, 17; in *glaucoma*, 169, 228, 229.
Reunion of *iris*, detached at its periphery, 27.
Reversal of parts seen, O.S., with a *lens*, 242.
Rimæ palpebrarum, 123, 124, 180.
Ring-forceps, 109.
Ruptures of the choroid, O.S., 241.

S.

Sac, lacrymal, valve of the, 125.
Scar of sclerotic incision of iridectomy, 226.
Scarlatina and diphtheritic *ophthalmia*, 131, 175.
Scissors, *cannula*, 344; for *corelysis*, 322, 332, 341.
Sclerotic, 197; *paracentesis* of the, 252; seen, O.S., through separations of the choroid, 241; gunpowder in the, 324; perforated, 190; thinned, 29, 70; in *glaucoma*, O.S., 228; injected, 188, 245; acutely inflamed, 191; congested, with *keratitis*, 55, 65, 69, 77; bulges rather than *cornea*, 158; external melanotic tumour of, 120; incision of iridectomy, 226; incision of iridectomy, unhealed or fistulous, 226.
Sclero-iritis, 258.
Scorbutic blood causing night-blindness, 40.
Scurvy in connexion with night-blindness, 35, 40.
Sebaceous, tumours, 112; cyst, 154.
Section of the *cornea*, extraction, 21, 25.
Secondary, contraction of the inferior oblique, 294; action of the *recti* superior and inferior, 3.
Serous effusions and *conjunctivitis*, 251.
Serum from inflamed choroid, 13.
Sex of interstitial *keratitis* cases, 94.
Short-sight—*see* Myopy.
Shot, in the eye, 189, 190, 217, 218, near the optic nerve, 218.
Signs of orbital aneurism, 6.
Silk, to tie the *iris*, 146.
Simpson's sulphate of zinc escharotic, 5.
Sinus, filled with *coagulum*, 9; cavernous, swollen, causing *bruit*, 11.
Sixth nerve, 133; palsied, *see Paralysis*.
Skin, folds of, of lids, 247; excised for *entropion*, 248; etc., removed for *entropion*, and *trichiasis;* 108, 109; removed for *ptosis*, 111; sloughed, 110; V-Y incision, 110.
Slitting the *canaliculus*, 109, 110.
Sloughing, of *cornea*, 131, 157; of the skin, 110, 114.
Soap, put in the eyes, for night-blindness, 36.
So-called diphtheritic *ophthalmia*, 175.
Softening of the *cornea*, 158, 159.
Solaneæ, their action on the pupil, 19.
Solution, 160; operation, 313, 341; operation, with pupil—adhesions, 318.
Spasm in extraction operation, 24.
Spatula-hook, 316, 321; its use, 328, rotated in the anterior chamber, 328; withdrawn, 330; to separate and detach membrane and *lens*, 333.
Spectacles, 183: prismatic, 141; cobalt blue for *myosis*, 308; convex, for *mydriasis*, 306; convex, before iridectomy, 230.
Spherical aberrations, O.S., 243.
Sphincter pupillæ, 192, 197, 198, 199, 303, 305; divide it, (?) 334; paralyzed, 196.
Squint, 63, 268, 343; *diagnosis*, 133, 135; unilateral, 110; from imita-

tion, 3; hereditary, 3; of one eye, at will, 3; linear measurement, 136; convergent, 81, 106, 108, 110, 134, 135, 137, 140, 212, 285, 293, 294; occasional convergent, 3; convergent after operation for divergent, 107; convergent, and crossed double images, 296; divergent, 8, 14, 67, 107, 108, 138, 141, 177, 179, 187, 193, 194, 203, 204, 208, 214, 261, 270, 293, 294, 298; divergent, after operation for convergent, 106, 107; divergent, and homonymous double images, 296; divergent, after operation, frequently relapses, 108; convergent and divergent, 294; and incongruence of the *retina*, 295, 298; prevented by an effort of the will, 3; caused by a *paralysis*, 141, 193; operation, 2, 3, 298; operation, the *recti superior* and *inferior* partly divided, 2; congenital concomitant, 297; and the most sensitive part of *retina*, 296; and extinction of mutual vision, 296.
Squinting, angle of, 135; upwards and downwards, 139.
Staphyloma, 160; of the *cornea*, 72; *cornea*, iridectomy for, 28; anterior, 264; anterior, abscised, 115; posterior, 263.
Staphylomatous state of sclerotic incision of iridectomy, 226.
Statistics, of interstitial *keratitis*, 93; of mortality of inherited *syphilis*, 99.
Stillicidium, 114, 115.
Stimulant treatment of night-blindness, 36.
Streatfeild, on *Corelysis*, 309; on an operation for removal of *lens*-capsule, etc., 342; on O.S., appearances of the vessels of the 'cupped' optic disk, 240; on sunlight ophthalmoscopy, 240; on much *edema*, with slight *conjunctivitis*, 248; on *entropion*, from winking, 247; on voluntary power of using the *tensortarsi*, and of causing *entropion*, 176; on coloured papers, 118; can the superior and inferior *recti* move the eye laterally (?) 1.
Streatfeild's case, of *ectropion*, 110; of *phthiriasis*, 125; of *iridlesis*, after extraction prolapse, 151.
Striæ, of *lens*, 348, 349, 352.
'Stump' after abscission, 115.
Subconjunctival, *edema*, 248, 251; *edema*, where most probably, 250; tenotomy, 106, 107, 110.
Subcutaneous, *edema*, 248, 251; division of a *nevus*, 113.
Suckling and edematous *conjunctivitis*, 251.
Sulphate of zinc paste, 5.
Sun-ophthalmoscope, 239.
Suppuration, of the eye, 171, 244; of the eye, after linear extraction, 347; of the *cornea*, 347; of the linear extraction puncture, 353; in the orbit, not to be waited for, 218.
Suspensory ligament, 264; perforated, 190; ruptured, 354; toughened, 344, 345; in iridectomy, 169, 170; retains *lens*-capsule, 344; dragged upon in removal of *lens*-capsule, etc., 344; to be torn through, in detail, 345.
Suture, to fix the eye, 107; to fix the lid, 110.
Symmetrical, pupil adhesions, 340; effusion of lymph into the anterior chambers, 86.
Sympathetic irritation of the eye, 264.
Sympathetic nerve, 196, 201, 202; decreased action, *myosis*, 308; and dilatation of the pupil, 302, 306.
Symptoms of orbital aneurism, 6.
Synchysis, of the vitreous, 309.
Syncope and dilated pupil, 19.
Synechia posterior totalis, 321.
Synechiæ—*see* Pupil, adhesions.
Syphilis, secondary and hereditary, and cataract, 349; hereditary, 106; of interstitial *keratitis* cases, infantile, 104; of parents, 97.
Syphilitic, hereditary, diseases of the eye, 54, 258, 311; nodes, and protrusion of the eye, 223, 225; nature of interstitial *keratitis*, 103; physiognomy, 54, 60, 61, 62, 66, 67, 68, 69, 70, 74, 75, 76, 77, 89, 95, 97, 103, 107.

T.

'Tape-worm' and squint, 2.
Tapping—*see Paracentesis*.
Tarso-raphia, 302.
Tarsus, 201.
Taylor, on voluntary power of inverting the lower lid, 186.
Tears, shedding, injurious, 159; flow of, 299; overflow, importance of the *orbicularis*, 299; their passage

by the canals, 125, 178, 180; their composition imitated, 302.
Teeth, of inherited *syphilis*, 57, 58, 59, 67, 68, 77, 80, 82, 83, 84, 90, 92, 93, 97, 103, 107, 261, 267, 271, 277; black *caries* of, 272.
Tendo, 179.
Tenotomy, for squint, 2; for diplopy, 295, 297.
Tension of the lids, 125, 180; of the vitreous and aqueous regions, 158; of the eye, 158, 166, 241; of the eye, in *glaucoma*, 168, 170, 171, 227, 228, 252.
Tensor, tarsi, voluntary power of using the, 4, 123, 176; *tarsi*, use of the 125, 180; *tarsi*, opposed to the *orbicularis*, 179, 181; *tarsi*, independant of the *orbicularis*, 124, 125, 177, 179; *tarsi*, two divisions of the, 125, 176; *choroideæ*, 197, 198, 199; *choroideæ*, paralysed by *belladonna*, 303.
Thinning of conical *cornea*, 155, 156, 158.
Third nerve swollen, etc., 9.
Tinea tarsi, 112; syphilitic, a secondary phenomenon, 282; syphilitic, with excoriations, 283; with syphilitic *keratitis*, 66, 72, 96.
Transplantation, of skin, 110, 114; of skin and lashes, 108; of *pterygium*, 113.
Treatment, of interstitial *keratitis*, 104; of conical *cornea*, 154, 157; of conical *cornea*, indications for, 159.
Trichiasis, 108, 109.
Trochlearis—see Obliquus superior.
Tumour, 112, 196; melanotic, 120; sebaceous cyst, 154.
Turning point, dislocated backwards, 290.
Tying, the common carotid, 7; the *iris*, *see Iridodesis.*
Types, Jæger's test, 336.
Typical teeth of inherited *syphilis*, *see* Teeth.

U.

Ulcer, of *cornea*, 338; of *cornea*, perforating, iridectomy for, 29; cancerous at the inner *canthus*, 5.
Ulceration, phagedenic, 8; of *cornea*, 157; cancerous, at the inner *canthus*, 5.
Uvea, on the *lens*, 273; *lens*, adherent to the, 190.

V.

V-shaped, portion of lid, removed, 155; skin excision of *entropion*, etc., 109; excision of lid, 109.
V-Y incision, of skin of lid, 110.
Valve of the lacrymal *sac*, 125.
Vanzetti's digital pressure of the common carotid artery, 11.
Varicose appearance of the ophthalmic vein, 9.
Vascular turgescence of the *iris*, 20.
Veins, dilated, with signs of orbital aneurism, 6; O.S. circulation easily arrested, 244; O.S. of the optic disk, 241; O.S. of the optic disk, gorged, 228, 229; their circulation restored by iridectomy, 229; of choroid and *retina* in *glaucoma*, 169, 229; retinal, O.S., anemic, 15; tortuous, 16.
Vertical meridian, of the eye, 45, 195, 203, 212, 286, 289; converges, 196, 205.
Vesicles, like *herpes*, O.S., 17
Vessels, of the optic disk, O.S., too numerous, 16; compress optic nerve fibres, in *glaucoma*, 229; of the optic disk, O.S., excavated, 240, 244; of the optic disk, O.S., excavated, their movements, 242; choroidal, 265, 275; retinal, 258, 275; retinal, O.S., 182. 254, 256; retinal, congested, 184; retinal, thickened, 266; retinal, small, 274.
Viability, of cases of inherited *syphilis*, 99; of heredito-syphilitic *choroiditis* patients, 276.
Vicarious yellow spot, 296; ideal, 297.
Vision, in *glaucoma*, 229, 230; before and after iridectomy, 230; mode of assisting, 247; magnifying, 249; single, 291; with a vicarious yellow spot, 296; mutual, extinguished, 296; in proportion to blood-supply, O.S., 15; of luminous rays only, 119; with squint, 3; before *corelysis*, 330; after *corelysis*, 316; dim, 181, 185; indistinct, 241; misty, 16; misty, anemic, 14; 'bothered,' 6, 7; double, *see* Diplopy.
Vitreous, *synchysis* of the, 309; region, tension of the, 158; absent, 190; lymph, in the, 176; space, arrest of development, 347; space, diminished, 13; space, turbid fluid of, 13; escape in extraction, 24; escape, in linear extraction, 347,

351, 354; escape, in linear extraction, before any *lens*, 354; advanced (and receded) after linear extraction, 349, 354; protrusion, in linear extraction, causes, 354; protrusion, obviated, 344; protrudes after removal of *lens*-capsule, etc., 344; its protrusion overlooked, *diagnosis*, 344; in the aqueous chamber, 351, 352, 354; softening of the, 350, 354; fluid, 172; fluid, after iridectomy, 228; protrudes in iridectomy, 169; is evacuated, 169, 170, 172, 226; is not discoloured in *glaucoma*, 252; appearance, O.S., of black *muscæ* in the, 275; brown flakes, O.S., in the, 325; inflammatory opacities of the, 258, 276; hazy, O.S., 259; *debris* of the, 264; black *striæ* in the, O.S., 272; foreign body in the, 240.

Voluntary, *entropion*, 247; power, over some muscles of the eye, 4; power, of using the *tensor tarsi*, 123, 176; power, of causing *entropion* of the lower lids, 176, 186.

Vomiting, dislocating the *lens*, 190.

W.

Wells, on paralytic affections of the muscles of the eye, 44, 133, 192, 284.

Williams, on a melanotic tumour, etc., 120.

Wright's examination of an excised eye, 122.

X.

Xerophthalmos, 300; its treatment, 302.

Y.

Yellow paper, most agreeable for readers, 118.

Yellow spot, 15, 16, 31, 138, 141, 143, 193, 194, 197, 204, 241, 254, 256, 290, 347; another point of the *retina*, substituted, 296; ideal, 297.

J. F. S.

Type Corrections in the Second Volume.

Page 119, line 2 (from bottom), for 127 read 137; and line 1 (from bottom), for 34 read 84. Page 155, line 3 (from bottom), for 2 read 3; and line 1 (from bottom) for 3 read 5. Page 156, line 1 (from top), after "fusiform cells" insert "(Fig. 2)"; and line 3 (from top), for "deceased" read "diseased." Page 169, line 12 (from bottom), for "opposition" read "apposition." Page 197, Note †, for "*vol. iii*" read "*vol. ii.*" Page 198, line 7 (from bottom), for "*choroideæ*" read "*pupillæ.*" Page 200, at bottom line, for "*membrana*" read "*musculus.*" Page 201, at top line, for "*membrana retractor* and *orbitalis*" read "*musculus retractor* and *orbicularis oculi.*" Page 214, line 14 (from bottom), for "*O inferior*" read "*O superior.*"

PRESENT

LIST OF SUBSCRIBERS

The Royal College of Surgeons.
The Royal College of Surgeons of Edinburgh.
The Faculty of Physicians and Surgeons of Glasgow.
The University of Glasgow.
The Royal Medical and Chirurgical Society.
The Birmingham Medico-Chirurgical Society.
The Nottingham Medico-Chirurgical Society.
The Royal Manchester Institution.
The Northampton General Infirmary.
St. Bartholomew's Hospital.
London Hospital.

C. R. Agnew, M.D., *surgeon to the New York Eye Infirmary.*
J. Andrew, London.
W. J. Arrington, M.D., United States.
E. Atkinson, Jerusalem.

A. B. Barnes, *surgeon to the West London Eye Infirmary.*
W. Bartlett, Notting Hill.
R. T. H. Bartley, M.D., *surgeon to the Bristol Eye Hospital.*
R. W. Batten, M.D., London.
B. Bell, *surgeon to the Edinburgh Eye Infirmary.*
R. M. Bernard, *consulting surgeon to the Bristol Eye Hospital.*
J. Billet, *surgeon to the Taunton Eye Infirmary.*
E. Boult, *surgeon to the Bath Eye Infirmary.*
E. Bowen, M.D., Chester.
H. H. Boxwell, M.D., Wexford.
R. S. Bright, Tasmania.
E. Bronner, M.D., *surgeon to the Bradford Eye Institution.*
A. D. Brooks, Henley-on-Thames.
T. Brown. London.
M. Brownfield, London.
G. Bullen, Ipswich.
F. J. Bumstead, M.D., *assist.-surgeon to the New York Eye Infirmary.*
J. M. Burton, Blackheath.
M. Buszard, M.D., Lutterworth.

J. Cadenhead, M.D., *surgeon to the Aberdeen Ophthalmic Institution.*
H. J. Carter, *surgeon to the Bombay Eye Infirmary.*
E. Chesshire, *surgeon to the Birmingham Eye Institution.*
R. Cocks, M.D., *surgeon to the Dundee Eye Infirmary.*
R. H. Cooke, Stoke Newington.
W. W. Cooper, *ophthalmic surgeon to St. Mary's Hospital.*
F. C. Cory, M.D., London.
J. Couper, London.
F. D. Cunningham, M.D., United States.
H. Curling, Ramsgate.

P. C. Delagarde, *surgeon to the Exeter Eye Infirmary.*
H. Dor, M.D., Vevay.
A. Dubois, M.D., *surgeon to the New York Eye Infirmary.*

J. H. Eccles, *surgeon to the Plymouth Royal Eye Infirmary.*
Dr. Esmarch, Kiel.
C. J. Evans, Nottingham.
H. Ewen, Long Sutton.

J. R. Farre, M.D., London.
S. W. Fearn, Derby.
W. H. Flower, *surgeon to the North London Eye Infirmary.*
J. F. France, *ophthalmic surgeon to Guy's Hospital.*

E. D. L. Gillott, *surgeon to the Sheffield Eye Dispensary.*

C. Gordon, London.
J. Green, United States.

H. Hancock, *surgeon to the Royal Westminster Ophthalmic Hospital.*
W. W. Harkness, London.
G. H. Haslop, Buckingham.
C. Heath, London.
G. F. Helm, Cambridge.
J. G. Hildige, M.D., Dublin.
J. Hogg, *assistant-surgeon to the Royal Westminster Ophthalmic Hospital.*
W. H. Holman, Hampstead.
C. Holthouse, *surgeon to the South London Ophthalmic Hospital.*
E. C. Hulme, *assist.-surg. to the Central London Ophthalmic Hospital.*
J. R. Humphreys, Shrewsbury.
F. A. Humphry, Brighton.
E. L. Hussey, Oxford.
E. Hutton, Dublin.

W. E. Image, Bury St. Edmund's.

H. Jackson, Sheffield.
F. Jordan, *consulting surgeon to the Birmingham Eye Dispensary.*

T. Kitchener, M.D., Jersey.
J. H. Knapp, M.D., Heidelberg.

J. Z. Laurence, *surgeon to the South London Ophthalmic Hospital.*
W. Lawrence, London.
L. S. Little, London.
W. Lockhart, M.D., Blackheath.

J. E. Macdonald, M.D., *ophthalmic surgeon to Demilt Dispensary, New York.*
R. McDonnell, M.D., Dublin.
W. Mackenzie, M.D., *surgeon to the Glasgow Eye Infirmary.*
G. Mackmurdo, London.
A. Macmillan, M.D., Hull.
E. Marshall, Mitcham.
W. Martin, Brighton.
W. May, Pernambuco.
R. Middlemore, *consulting surgeon to the Birmingham Eye Infirmary.*
W. J. Millard, Whitchurch.
J. E. Miller, M.D., Londonderry.
R. H. Moon, Buckingham.
E. Morris.

H. B. Norman, Southsea.

T. Nunneley, *surgeon to the Leeds Eye Infirmary.*

H. Obre, *surgeon to the St. Marylebone Eye Institution.*
P. O'Brien, Bengal.

W. B. Page, Carlisle.
R. Partridge, London.
H. Penfold, *surgeon to the Brighton Eye Infirmary.*
A. Playne, M.D., Maidenhead.
H. Power, *assist.-surgeon to the Royal Westminster Ophthalmic Hospital.*

E. M. A. Rendle, *surgeon to the Plymouth Royal Eye Infirmary.*
W. Rivington, London.
B. Roberts, Eastbourne.
H. Rogers, London.

J. K. Sampson, Southampton.
B. T. Seabrook, *surgeon to the Brighton Eye Infirmary.*
J. Shaw, *surgeon to the Madras Eye Infirmary.*
F. Simms, Twickenham.
E. P. Smith, Hackney.
J. V. Solomon, *surgeon to the Birmingham Eye Infirmary.*
W. J. Square, *surgeon to the Plymouth Royal Eye Infirmary.*
V. Stoeber, M.D., Strasbourg.

T. P. Teale, jun., Leeds.
Dr. Thilesen, Christiania.
C. R. Thompson, Westerham.

H. Veasey, Woburn.

W. Walker, *ophthalmic surgeon to the Edinburgh Royal Infirmary.*
T. W. Walsh, *surgeon to the Worcester Eye Infirmary.*
M. Ware, London.
J. S. Wells, M.D., London.
E. F. Weston, Stafford.
W. R. Wilde, *surgeon to St. Mark's Ophthalmic Hospital, Dublin.*
J. Williams, M.D., *surgeon to the Cork Eye Dispensary.*
T. Williams, M.D., Swansea.
H. Wilson, Dublin.
J. Windsor, *surgeon to the Manchester Eye Hospital.*
J. Woolcott, *surgeon to the Kent County Ophthalmic Hospital.*

RE
3
L6L6
v. 2

Royal London Ophthalmic Hospital.
Reports

Biological
& Medical
Serials

PLEASE DO NOT REMOVE
CARDS OR SLIPS FROM THIS POCKET

UNIVERSITY OF TORONTO LIBRARY